AITBS
PHARMACY BOOKS

HUMAN ANATOMY & PHYSIOLOGY

Exclusively Prepared for
D.Pharm First Year Students (PCI ER 2020)

SEEMA RAHUL KENJALE

HUMAN ANATOMY & PHYSIOLOGY

Exclusively Prepared for D.Pharm First Year Students (PCI ER 2020)

© 2023 AITBS Publishers, India all Rights Reserved. No part of this book may be reproduced or transmitted in any form or by any means of electronic or mechanical including photocopying, recording or any information stored in a retrieval system, without the prior written permission of the publisher.

All brand names and product names used in this book are trade names, service marks, trademarks or registered trademarks of their respective owners. The publisher is not associated with any product or vendor mentioned this book.

Medicine is an ever changing science. As we learn more about medicines, our knowledge changes. While due precautions have been taken to ensure the credibility of the matter published; authors, publishers cannot be held, responsible for any error arising out of use of information published in this book and/or of judgement by the use of material printed in this book. Readers are therefore, encouraged to confirm the information printed from other sources before using the drugs. This is particularly so in case of uncommon or rarely used drugs.

This book is sold on the understanding that the publisher is not engaged in providing professional medical services. If such advice or services are required, the services of a competent medical professional should be sought.

Every effort has been made to avoid errors or omissions in this publication. In spite of this, some errors might have crept in. Any mistake, error or discrepancy noted may be brought to our notice which shall be taken care of in the next edition. It is notified that neither the publisher nor the authors or seller will be responsible for any damage or loss of action to any one, of any kind, in any manner, therefrom. In case of any dispute, all legal matters are to be settled under Delhi jurisdiction only.

For binding mistakes, misprints or for missing pages, etc., the publisher's liability is limited to replacement within one month of purchase by similar edition. All expenses in this connection are to be borne by the purchaser.

First Edition : 2023

ISBN: 978-93-7473-714-9

Published by:
Virender Kumar Arya for
AITBS Publishers, India
MEDICAL PUBLISHERS
J-5/6 Krishan Nagar, Delhi-110051 (INDIA)
Phone: 011-40167052, 49067602; Fax: 011-22009074
E-mail: aitbsindia@gmail.com & aitbsindia@hotmail.com

Printed by AITBS, Delhi

Preface

It is indeed a great pleasure for me to present the First edition of **Human Anatomy & Physiology book.** As a teacher, I have noticed that many students are unable to understand and ultimately disoriented about the subject. The Prime motive behind this book is to provide basic knowledge of **Human Anatomy & Physiology** in a simple and interesting manner for the healthcare Professionals.

This book is written in a lucid language along with schematic diagrams to expand the horizon of conceptual understanding. It is designed to facilitate the meaningful learning experiences and also enables students to appreciate the beauty of the subject. The content of this book is beneficial for the study of Pathophysiology, Pharmacology and Pharmacotherapeutics. It is a humble attempt as per syllabus based on Education Regulations, 2020 prescribed by Pharmacy Council of India (PCI), New Delhi for Diploma Course in Pharmacy. I hope this book becomes valuable tool for students as-well-as teachers to achieve academic goals.

I will be happy to receive effective suggestions and constructive comments for improvements of the book in the next edition. I look forward to a positive response from every corner.

I would like to express my sincere thanks to my Parent society 'Pune District Education Association' and Principal Dr. Ashok Bhosale for their constant support and motivation.

I am grateful to my Parents and in laws, Husband Mr. Rahul Kenjale, Sons Atharva and Shivansh who plays significant role in my life.

I wish to extend my special thanks to Virender Kumar Arya at AITBS Publishers, India, for providing me such platform with this golden opportunity.

Seema Rahul Kenjale

Contents

With compliments from A.I.T.B.C
as SPECIMEN COPY FOR
RECOMMENDATION TO
STUDENTS
Mob.: 9999080104

Preface (v)

1. Introduction 1-7
2. The Cell 8-17
3. Tissues 18-32
4. Skeleton System 33-64
5. Haemopoietic System 65-79
6. Lymphatic System 80-85
7. Cardiovascular System/Circulatory System 86-111
8. Respiratory System 112-131
9. Digestive System 132-158
10. Muscular System (Skeletal Muscles) 159-170
11. Nervous System 171-187
12. Sense Organs 188-211
13. Urinary System 212-229
14. Endocrine System 230-244
15. Reproductive System 245-266

Index 267-276

1

CHAPTER

Introduction

The study of human body is divided into two major headings:

1. Anatomy
2. Physiology

Anatomy: It is the study of the structure of every part of the body and their relation to one another.

Physiology: It is the study of functioning of the every part the body, their relation to one another, how they work and integrated to produce co-ordinated action.

DEFINITIONS OF VARIOUS TERMS USED IN ANATOMY

- **Cell:** It is the smallest structural and functional unit of an organism.
- **Tissue:** Group of cells having same Physical characteristics (Size and Shape) and performing similar specialized functions is described as a tissue, e.g., epithelial tissue, muscular tissue.
- **Organ:** Group of tissues that performed specialized functions is described as an organ, e.g., heart pumps the blood, stomach digest food.
- **System:** Group of organs that perform specialized functions is called system, e.g., digestive system consists of organs such as stomach, small intestine, large intestine and perform the function of digestion of food.

Compound (Made-up of atoms, molecules, hydrogen, oxygen nitrogen, carbon etc.)

↓

Cell made-up of compounds like proteins, fats, carbohydrates, water

↓

Tissue (Made-up of cells)

↓

Organs (Made-up of tissues)

↓

Systems (Made-up of organs)

↓

Organism (Made up of systems)

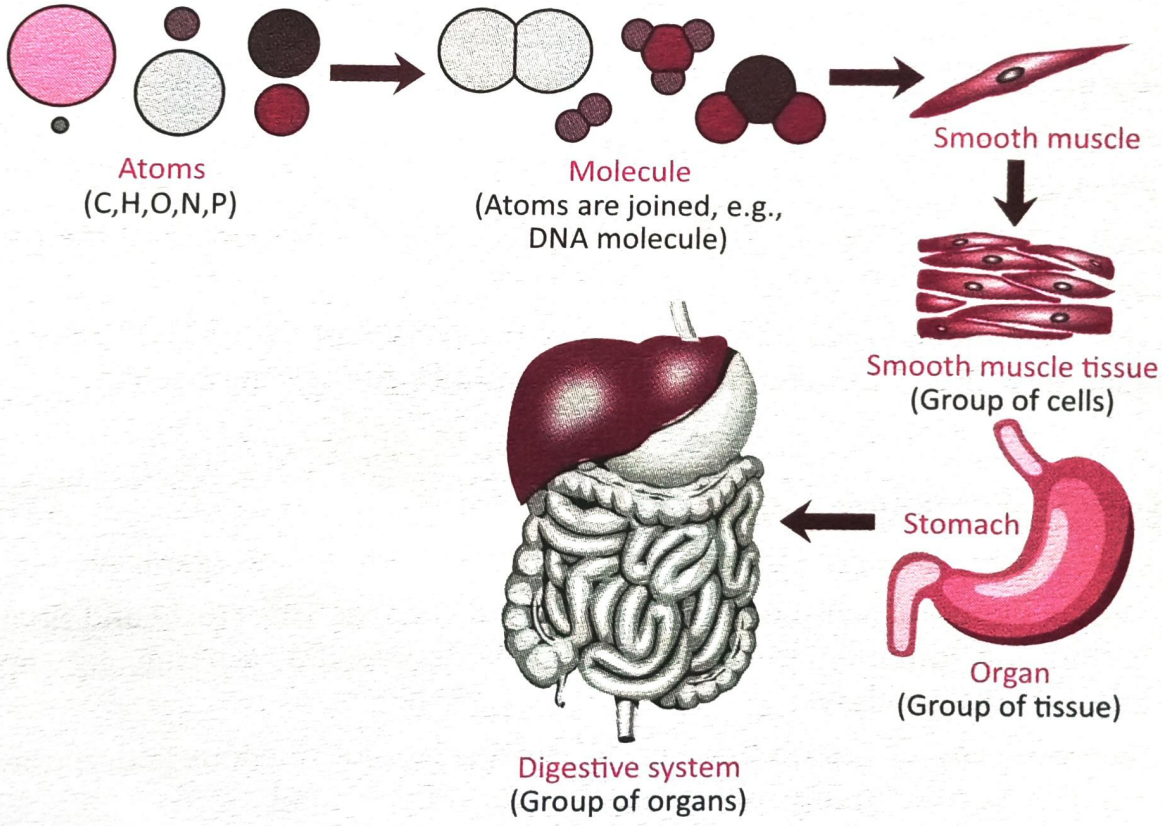

Fig. 1.1: ***Level of structural organization in the Human Body***

SYSTEMS OF THE HUMAN BODY

Sr. No.	System of the body	Organs of System	Functions of System
1.	Nervous System	Brain, spinal cord, nerves	• Mental activities (memory, learning, thinking). • Voluntary actions (walking, running). • Involuntary actions (heart beat, breathing, swallowing. • Sensations of visions, hearing and smell.
2.	Respiratory System	Nose, lungs, pharynx, larynx, trachea, bronchi	Respiration, i.e., exchange of gases means inhaling oxygen and exhaling carbon dioxide.
3.	Cardiovascular System	Heart, blood vessels	Circulation of oxygenated blood.
4.	Digestive System	Mouth, pharynx, oesophagus, stomach, small and large intestine	Digestion (breakdown) of food and its absorption.
5.	Urinary System	Kidneys, ureters, urinary bladder and urethra	Formation and excretion of urine, Maintains water balance, blood pressure and acid base balance.
6.	Reproductive System	Gonads (testes in males and ovaries in females)	Production of gametes (sperm in male, egg in female), regulates reproduction.
7.	Skeletal System	Bones and joints	Support and protect the body, movement of body, stores minerals, e.g., calcium.
8.	Muscular System	Skeletal muscles	Body movements, body posture.
9.	Endocrine System	Pituitary gland and all other endocrine glands	Releases hormones and regulate body activities.
10.	Lymphatic System	Lymph, lymph vessels, spleen, thymus gland,	Carries tissue fluid, transport lipids from G.I.T., give immunity, i.e., protect body against disease causing organism.
11.	Integumentary System	Skin, hairs, nails	Protect underlying tissue, regulate body temperature, remove waste.

BODY CAVITIES OR BODY SPACES

Body cavities are spaces within the body that protect, separate and support internal organs.

Cavity	Description
Dorsal Cavity	**Presents at back side of the body**
1. Cranial Cavity	Formed by cranial bones and contains brain
2. Vertebral Cavity	Formed by vertebral column and contains spinal cord, nerves
Ventral Cavity	**Presents at front side of the body**
1. Thoracic Cavity	It is formed by ribs, sternum and supporting muscles and contains lungs, heart, trachea, bronchi, oesophagus, large blood vessels.
2. Abdominal Cavity	It is formed by dome shaped diaphragm, lumbar vertebrae and supporting muscles. It contains stomach, spleen, liver, gallbladder, small intestine and large intestine.
3. Pelvic Cavity	It formed by the space between pelvis, sacrum, coccyx and muscles. It contain Urinary bladder, portion of large intestine, internal organs of reproduction.

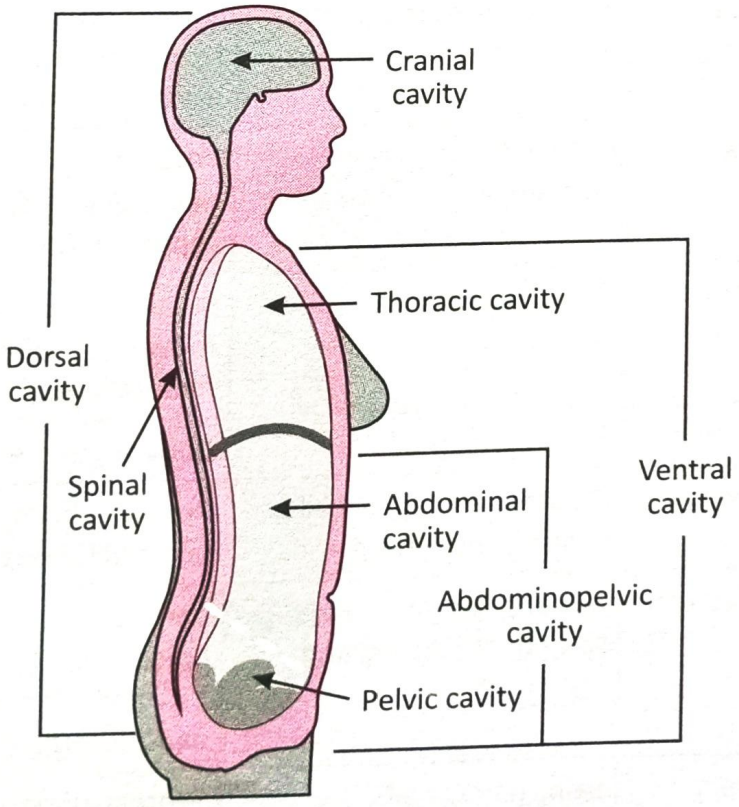

Fig. 1.2: *Cavities of Body*

ANATOMICAL TERMINOLOGIES

1. **Anatomical position:** This is the
   (a) Upright position of the human body
   (b) With the head facing forward
   (c) Arms at the sides
   (d) Palms of the hands facing forward
   (e) Feet together.

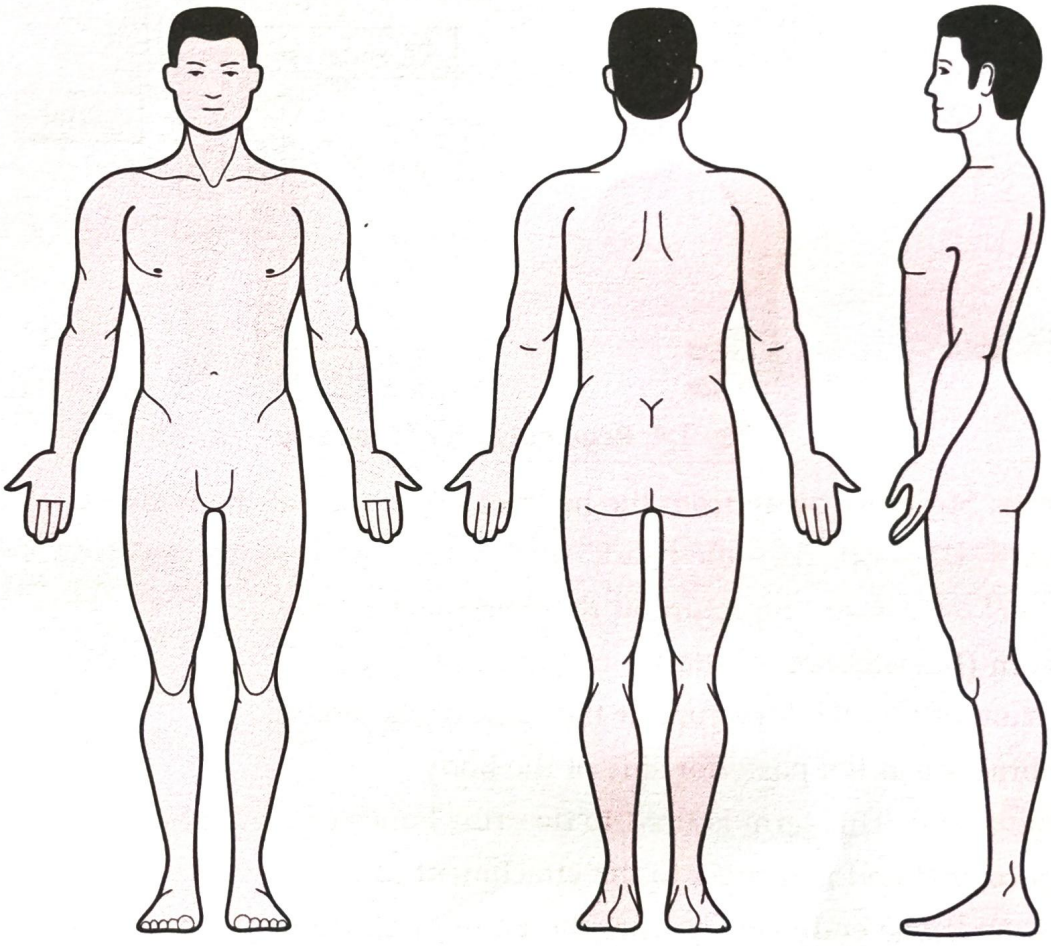

Fig. 1.3: ***Anatomical Position***

2. **Median plane:** When the body is in the anatomical position is divided longitudinally in two equal parts.
3. **Medial (midline):** Any structure nearer to the midline of the body
4. **Lateral (away):** Any structure away from the midline of the body.
5. **Superior:** Structure towards the head or upper part of the body.
   Heart is superior than the stomach.

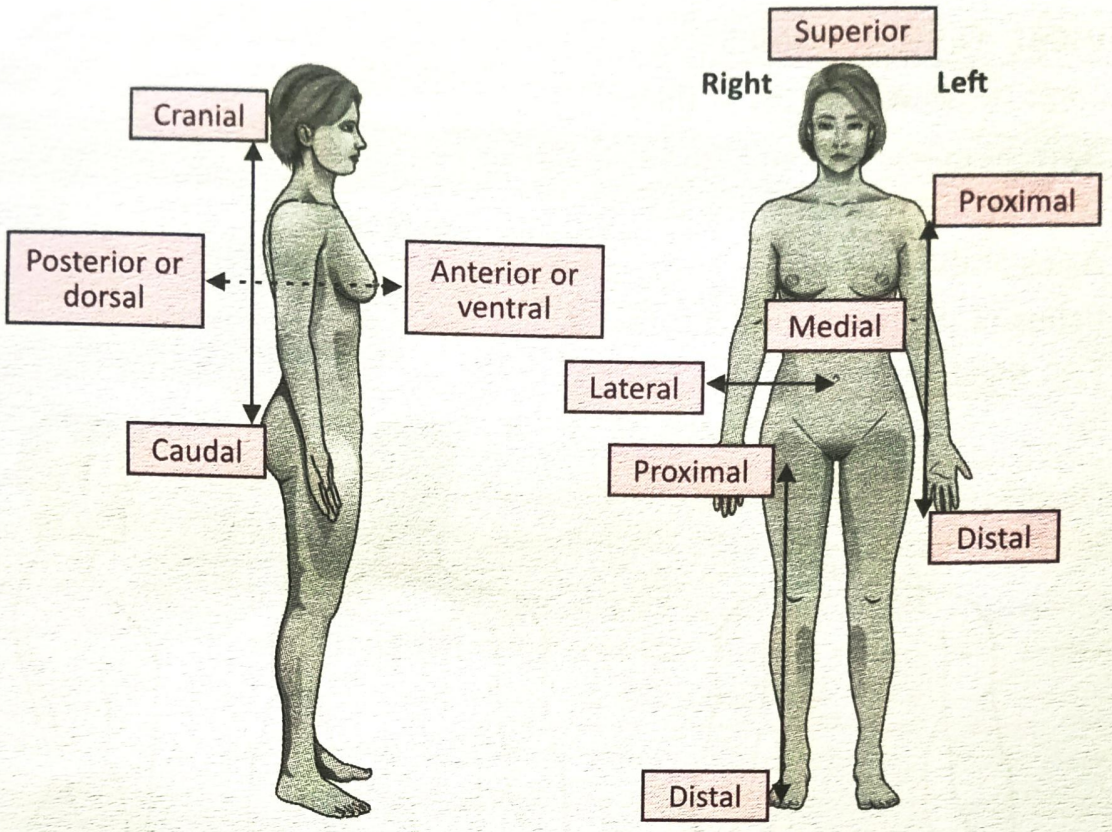

Fig. 1.4: ***Regional Part of the Body***

6. **Inferior:** Structure away from the head or lower part of the body.
   Stomach is inferior than the heart.
7. **Anterior or Ventral:** Structure at the front of the body.
   Sternum (Breastbone) is anterior of the body.
8. **Posterior or Dorsal:** Structure at the back of the body.
   Vertebrae are at the posterior side of the body.
9. **Proximal end:** This term is used to describe bones of the limbs.
   The proximal end is nearest to the attachment of limb.
10. **Distal end:** The end is away from the point of attachments of the limb.
11. **Border:** It is a ridge of bone which separates two surfaces of the bone.
12. **Spine/spinous process or crest:** It is a sharp ridge of bone.
13. **Tubercle:** These are small, roughened bony projections for attachments of muscle or ligaments.
14. **Condyle:** It is a smooth rounded projection of a bone which takes part in a joint.
15. **Fossa:** It is depression or hollow structure in a bone.
16. **Foramen:** It is a hole in a structure of the bone.
17. **Sinus:** A cavity within a bone is called sinus.

18. **Meatus:** A tube shaped cavity within a bone is called meatus, e.g., ear has meatus.
19. **Fissure or Cleft:** A deep and narrow cavity in a bone or tissue is called a fissure or cleft.
20. **Septum:** It is a partition separating two cavities, e.g., nose.
21. **Articulation:** It is a joint between two or more bones. OR It is the site where two or more bones come together.
22. **Articulating Surface:** It is a part or surface of bone participates in the formation of a joint is known as articulating surface.
23. **Facet:** It is a small, flat articulating surface of the bone.
24. **Sutures:** These are immovable joints between two or more bones, e.g., skull have sutures.

    Sutures are the band of the fibrous tissue that connect the bones of the skull.

    Sutures are of four types:

    (a) Frontal
    (b) Coronal
    (c) Saggital
    (d) Lambdoid suture

IMPORTANT QUESTIONS

1. Define Anatomy and Physiology. (S-96, 97, 99, 00; W-98, 01, 05)
2. Define Cell and Anatomical Position. (W-02)
3. Define Fossa and Foramen. (W-97; S-00)

2

CHAPTER

The Cell

DEFINITION

Cell is the smallest structural and functional unit of an organism.

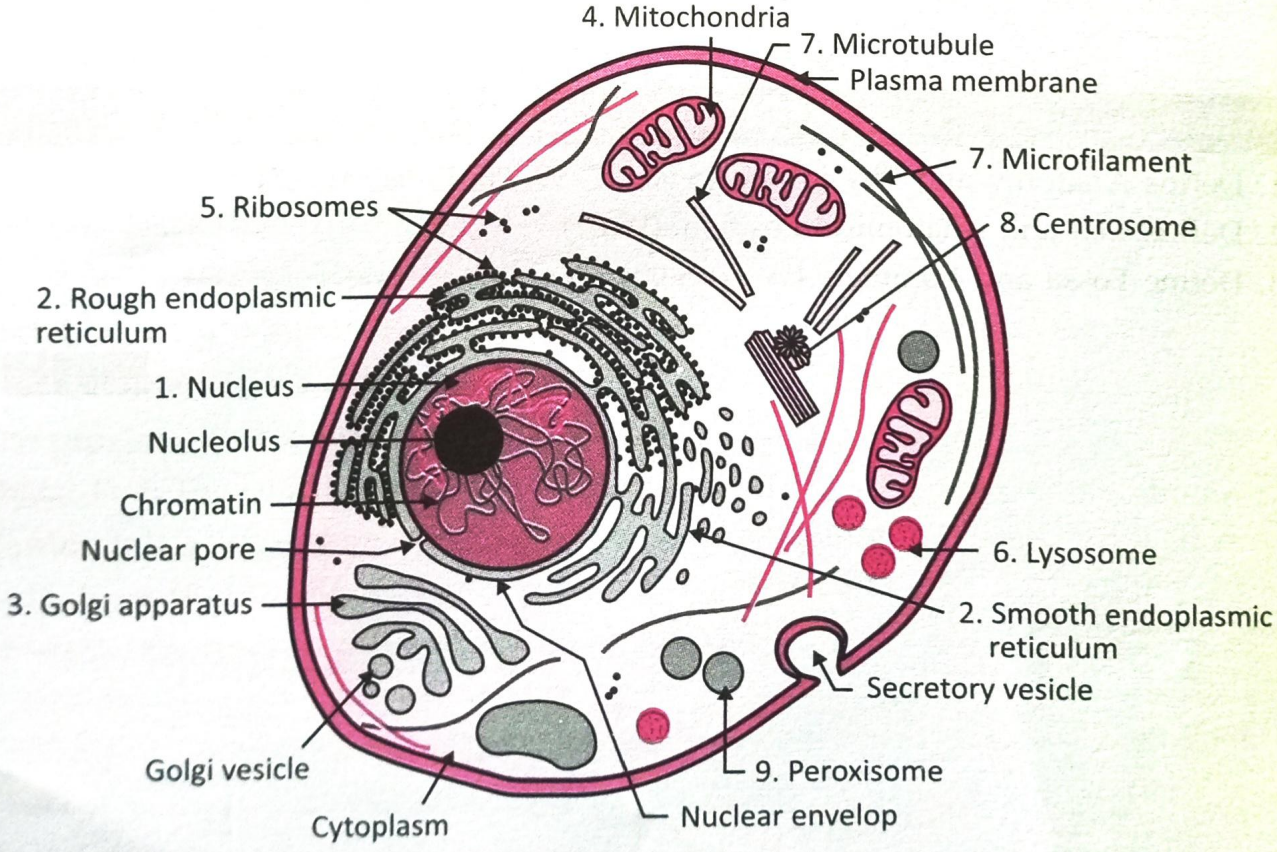

Fig. 2.1: *Structure of Cell*

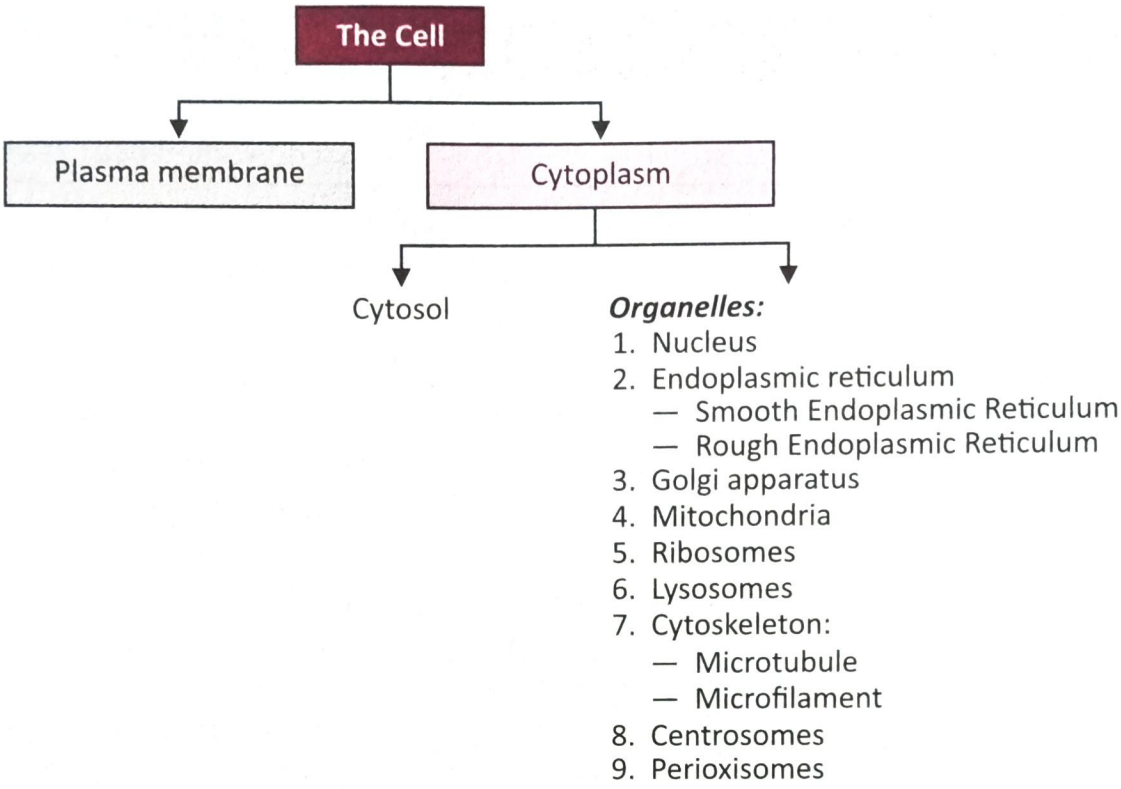

Fig. 2.2: ***Cell and its Organelles***

Table 2.1: Cell's Structural parts with their Functions

Part	Structure	Functions
1. Plasma membrane	Lipid bilayer with integral proteins	• Protects internal organelles of the cell. • Regulate movement of substances in and out of cells
2. Cytoplasm	Cytosol and organelles	Site where cellular activities takes place.
Cytosol (fluid inside the cytoplasm)	Cytosol consists of water, solutes suspended particles, carbohydrate, proteins, lipid solutes, inorganic substances and salts.	Cell organelles are embedded in cytosol, Medium in which cell's metabolic reactions occur.
Organelles	Specialized structures with shape	Each organelle has specific function.
1. Nucleus	Nuclear envelop with pores	• Controls cellular structure • Directs cellular activities • Produce ribosomes in nucleoli

Part	Structure	Functions
2. Ribosomes	Granules composed of of RNA and proteins	Synthesize proteins, i.e., enzymes required for metabolic reactions.
3. Mitochondria	Double unit membrane.	Releases its stored energy for performing cellular functions, i.e., ATP production and power house of cell.
4. Endoplasmic Reticulum (ER)	• Flattened sacs or tubules. Rough ER is covered by ribosomes and attached to nuclear envelop. • Smooth ER lacks ribosomes (Cells of Testes and Ovaries Produces lipid containing hormones Testosterone and Estrogen having large amount of Smooth ER)	• Rough ER synthesize proteins (glycoproteins and ER phospholipids) • Smooth ER synthesize lipids and steroid hormones • Detoxify drugs • Removes phosphate group from glucose 6 phosphate • Releases calcium ions in muscle cells
5. Golgi apparatus	Membranous sacs with bulging end	Take proteins from rough ER Sorts, storage, package proteins in vesicles and then transfer to other organelles of cell, i.e., lysosomes, also to plasma membrane and outside of the cell (extracellular fluid)
6. Lysosomes	Secretory vesicles formed from Golgi apparatus. Lysosomes contains digestive enzyme	Digestion (breakdown) of Macromolecules, i.e., carbohydrates, proteins, lipids, nucleic acid, cellular debris or waste within the cell.
7. Cytoskeleton: (a) Microfilament (b) Microtubules	 Smallest fibres Large proteins	 Give support and shape Give cellular movements
8. Centrosomes	Consists of centrioles (small cluster of microtubule rings)	Responsible for cell division.

PLASMA MEMBRANE

1. The plasma membrane consists of two layers of phospholipids (lipid bilayer) with protein and sugar molecules.
2. The phospholipids are arranged in parallel layers forming phospholipids bilayer which forms basic frame work of the plasma membrane. Phospholipids means lipids (fatty acids) with phosphate group.

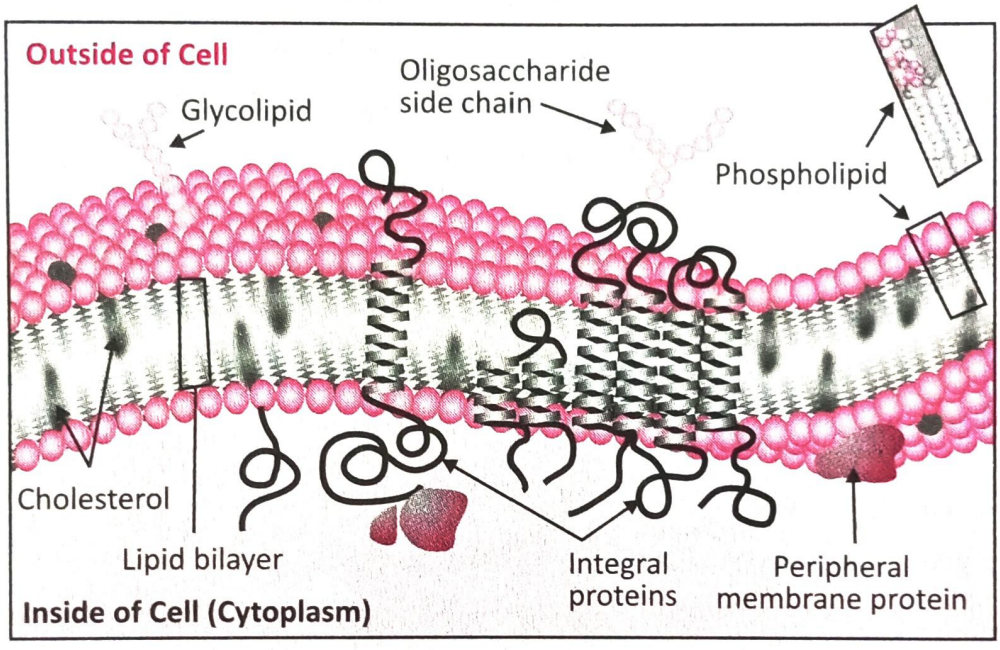

Fig. 2.3: ***Plasma Membrane***

3. The phospholipids molecule have a head and tail. Head is electrically charged that is hydrophilic (water loving). Tail is not charged and lipophilic (lipid loving) or hydrophobic (water hating)
4. Phospholipids bilayer is arranged like a sandwich that is head at the outer surface and tails at central layer.
5. **Proteins which are present are of three types:**
   (i) Integral proteins – present across or in the phospholipids.
   (ii) Peripheral proteins – present at outer or inner surface of plasma membrane.
   (iii) Glycoprotein – proteins with carbohydrate groups give immune response.

Functions of Plasma Membrane

1. It protects cellular contents.
2. It allow the entry and removal of substances.
3. It makes contact with other cells.

4. Proteins in the plasma membrane acts as channels, transporters, receptors, enzymes.
5. Glycoproteins gives immunity response.

ORGANELLES OF THE CELL

Organelles means small organs have specialized structures and shapes.

Nucleus

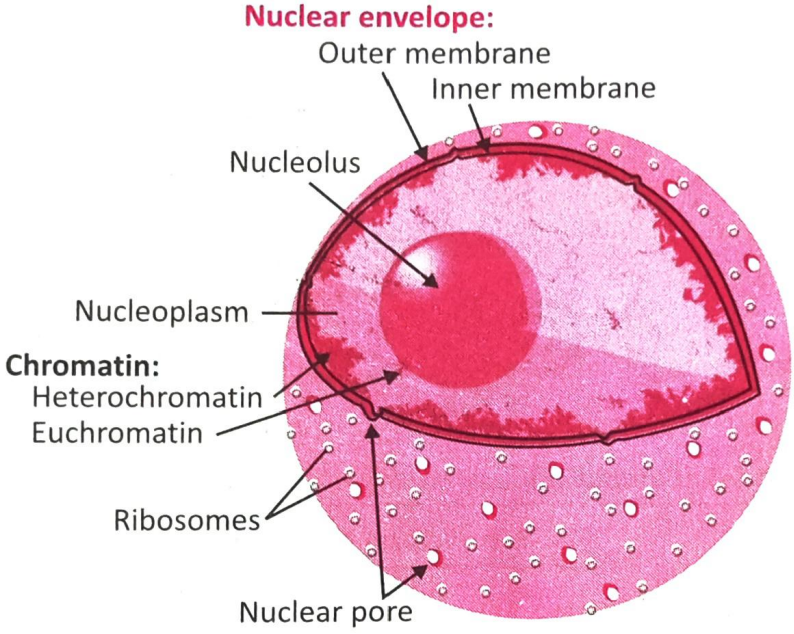

Fig. 2.4: ***Nucleus***

1. Nucleus is a spherical or oval shaped structure. Most body cells have a nucleus but red blood cells does not contain nucleus. Skeletal muscle cells have more than one nucleus.
2. Nucleus consists of double membrane nuclear envelop which is lipid bilayer.
3. In between the nuclear envelop, nuclear pores are present through which movement of substances takes place between nucleus and cytoplasm. Nuclear pore consists of a circular arrangement of proteins.
4. Inside the nucleus, one or more spherical bodies called nucleoli (single–nucleolus).

   Nucleolus synthesize large amount of proteins. It is made up of proteins and RNA (Ribonucleic Acid).
5. In the nucleus of each cell, the DNA (Deoxyribonucleic Acid) molecule is packaged into thread-like structures called chromosomes. Each chromosome is made up of DNA and tightly coiled many proteins.

6. Genes are present on the chromosomes which are hereditary units. RNA regulate gene expression. Thus, chromosomes contains genes, DNA and tightly coiled proteins. DNA contains information for the production of proteins.
7. Chromatin is the combination or complex of DNA and proteins that make up the contents of the nucleus of a cell. The primary functions of chromatin are:
   (a) to package DNA into a smaller volume to fit in the cell,
   (b) to strengthen the DNA to allow mitosis,
   (c) to prevent DNA damage and
   (d) to control gene expression and DNA replication.

Functions of Nucleus

1. Controls cellular structure or to control gene expression.
2. Directs cellular activities.
3. Mediate the replication of DNA during the cell cycle.

Endoplasmic Reticulum (ER)

1. Endoplasmic reticulum is network of flattened sacs or tubules that extends from nuclear envelop. It is of two types: 1. Rough ER and 2. Smooth ER
   A. **Rough Endoplasmic Reticulum:** They contain ribosomes.

   Functions: As it contain ribosomes, its function is to synthesize proteins and phospholipids that are transferred to other organelles, passes into the plasma membrane and secreted from the cell.

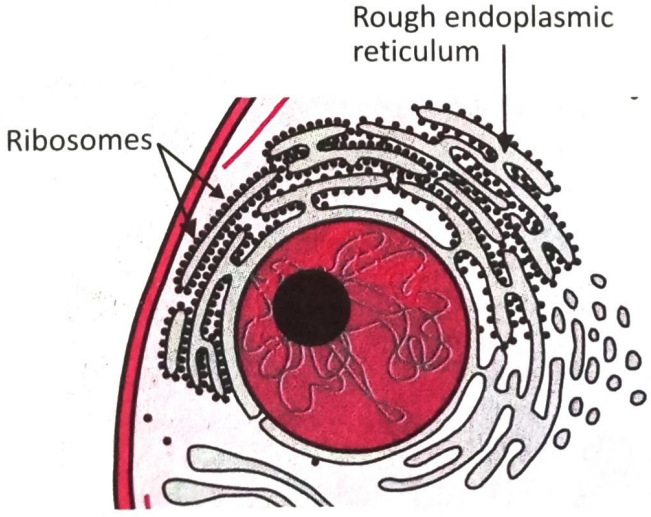

Fig. 2.5: ***Smooth Endoplasmic Reticulum***

B. **Smooth Endoplasmic Reticulum:** They do not contain ribosomes:

Functions:

1. Synthesize fatty acids and steroidal hormones such as estrogen and testosterone.
2. In liver cells, smooth ER detoxify drugs.
3. In liver, kidney, intestinal cells, smooth ER removes phosphate group from glucose 6 phosphate which allows free glucose to enter into blood.
4. In skeletal muscle cells, smooth ER releases calcium ions that causes contraction of skeletal muscles.

Ribosomes

These are tiny organelles or granules consists of Ribonucleic Acid (RNA).

Function:

Ribosomes involved in the synthesis of proteins.

Golgi Apparatus or Golgi Complex

1. Golgi complex are small flattened membranous sacs with bulging edges. It consists of 3 to 20 golgi cisternae.
2. These cisternae are situated upon each other like a pile of plates.

Functions:

(a) Golgi complex takes or receives proteins from the rough ER.

(b) After taking proteins from rough ER, Golgi complex modifies (changes) ,sorts and package these proteins.

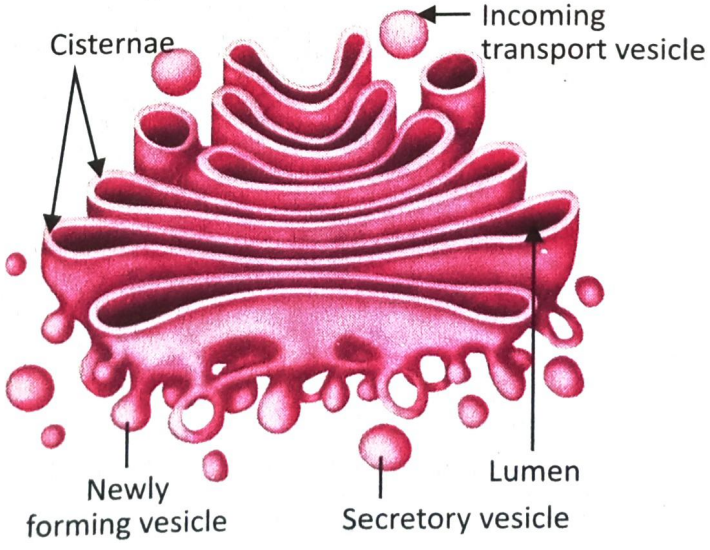

Fig. 2.6: *Golgi Apparatus or Golgi Complex*

(c) **Golgi complex forms three types of vesicles:**

(i) **Transport Vesicle:** They transport vesicle that carry protein molecules to another cellular organelles in cell, e.g., transport vesicles carry digestive enzymes (proteins) to lysosomes in the cell.

(ii) **Membrane Vesicles:** They deliver proteins or new molecules to plasma membrane of the cell.

(ii) **Secretory Vesicles:** They discharged processed proteins from plasma membrane into outside the cell, i.e., extracellular fluid. It also form membrane vesicles that deliver new molecules to plasma membrane.

Lysosomes

Lysosmes are secretory vesicles that produced from the Golgi complex. Lysosomes contain digestive or hydrolytic enzymes. Also called suicidal bags as lysosomes destroy cell macromolecules.

Functions:

1. Lysosomes carry out the Digestion (breakdown) of macromolecules like carbobydrates, proteins, lipids, nucleic acid, cellular debris or waste within the cell. Thus it is responsible for digestion and removal of waste from cell.
2. It also carry out extracellular digestion.

Perioxisomes

These are smaller bodies similar to lysosomes. Perioxisomes contain several oxidase enzymes that can oxidize (remove hydrogen atom) various organic substances like amino acids and fatty acids. Enzymes of Perioxisomes oxidize toxic substances, i.e., alcohol. So liver have more perioxisomes to detoxify alcohol and other damaging substances. Perioxisomes protect the cells against toxic effect of Hydrogen Peroxide as it has catalase enzyme.

Mitochondria

1. **Mitochondria (mito-thread, chondria-granules):** A cell may have one or many mitochondria.
2. **Active cells,** i.e., works more such as those found in the muscles, liver and kidney have large number of mitochondria as they use ATP at a high rate.
3. **Structures:**

(i) A mitochondrion consists of an outer membrane and inner membrane.

(ii) Inner membrane contains a series of folds or shelves called cristae (ridges) which provide surface area for chemical reactions. These shelves contains oxidative enzymes. When nutrients and oxygen come in contact with these enzymes they combine to form carbon dioxide, water and chemical energy.

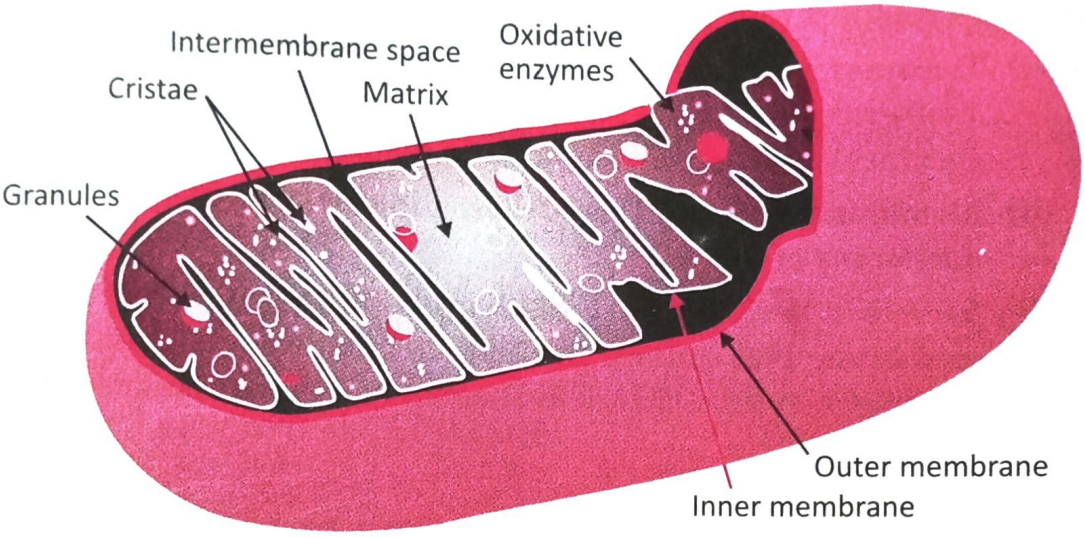

Fig. 2.7: *Mitochondria*

This chemical energy is stored in a small molecule called ATP (Adenosine Triphosphate). This ATP then diffuses throughout the cell and releases its stored energy for performing cellular function.

Nutrients + Oxygen + enzymes of mitochondria

↓

$CO_2 + H_2O$+ ATP (chemical energy) → releases its stored energy

Thus, mitochondria is called power house of the cell because it produces ATP, i.e., chemical energy for cellular reactions.

(iii) Inner membrane encloses a large centrally fluid filled cavity called matrix.

(iv) Mitochondria is self-replicative that is when energy demand more than number of mitochondria production increases.

Cytoskeleton

Cytoskeleton is a network of proteins filament. It includes:

1. **Microfilament:** They generate movement involved in muscle contraction, cell divison and cell locomotion. They give support and shape to cells.
2. **Microtubules:** These are tubes contain protein tubulin. They determine cell shape and function in the movement of organelles. They participate in the movement of chromosomes during cell divisions.

IMPORTANT QUESTIONS

1. Define cell. (S-97; W-98, 01)
2. Draw a well labelled diagram of cell. (S-98, 01; W-98, 01)

3. Discuss different components of cell. (S-97)
4. Write a note on endoplasmic reticulum. (S-03; W-97)
5. Write structure and function of Golgi body. (W-99)
6. What are lysosomes? Give their functions. (S-00, 02)

3

CHAPTER

Tissues

DEFINITION

Tissue is the group of cells having same physical characteristics (Size and Shape) and performing same specialized function.

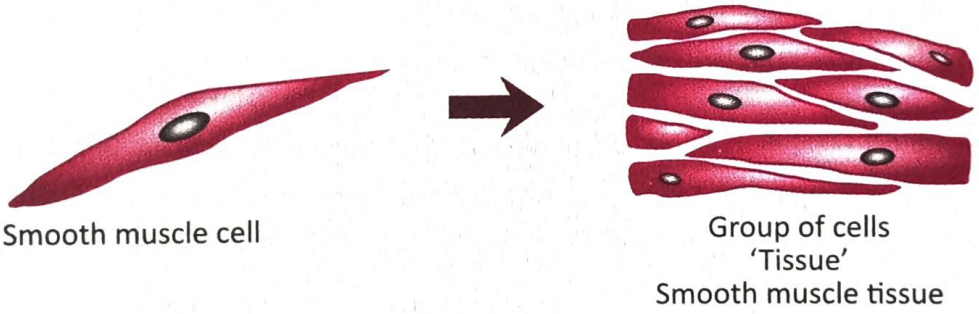

Fig. 3.1: ***Formation of Tissue***

FUNDAMENTAL TYPES OF TISSUES

According to the structure and functions, tissues are classified into:

1. **Epithelial Tissues**, e.g., covering of the body (skin), lining various cavities, hollow organs tubes.

   Functions: Protection, secreation, absorption.

2. **Connective Tissue**, e.g., blood and bones.

   Functions: Binding and structural support, transport.

3. **Muscle Tissue**: Skeletal muscle, smooth muscle, cardiac muscle.

   Functions: Movement that is contraction and relaxation.

4. Nervous Tissue, e.g., brain, spinal cord, pheripheral nerves.

Functions: Mental activities, sensation, detects and respond to changes inside and outside the body.

EPITHELIAL TISSUES

Characteristics of Epithelial Tissue

- The cells of the epithelial tissue are compactly arranged in sheets.
- The cells are lie on the basement membrane.
- Intracellular substance matrix is less.
- Nucleus of each cell is oval or sphere and is centrally located.

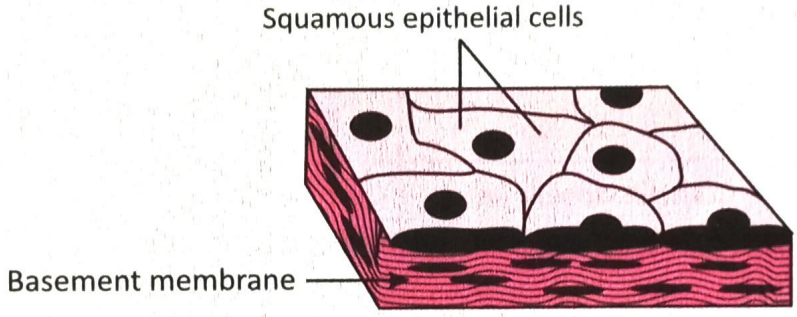

Fig. 3.2: *Epithelial Tissue*

Location of Epithelial Tissue

- It forms covering (skin) of the body.
- Lining cavities, covering (stomach), tubes (esophagus, glands.)

Functions of Epithelial Tissue

- Protection of inner tissue
- Absorption
- Excreation
- Secreation
- Filteration

Classification of Epithelial Tissue

Depending upon the layers of cells epithelial tissue classified into:

A. **Simple Epithelial Tissue (single layer of cells):** It is again classified into:

1. Simple Squamous Epithelium
2. Simple Cuboidal Epithelium

3. Simple Columnar Epithelium
4. Simple Ciliated Epithelium

B. **Compound/Stratified Epithelial Tissue (several layers of cells):** Classified into:

1. Stratified Squamous Epithelium
2. Transitional Epithelium (This tissue is located at the site of considerable wear and tear).

A. Simple Epithelial Tissue

Table 3.1: Types of Simple Epithelial Tissue

Simple Squamous Epithelium	Simple Cuboidal Epithelium	Simple Columnar Epithelium	Simple Ciliated Epithelium
Single layer flattened cells.	Single layer cube like cells.	Single layer column like cells.	Single layer column like with cilia (hair like processes).
Cells fit closely together like flat stones forming thin and smooth membrane.	Cells fit closely lie on basement membrane.	Cells fit closely lie on basement membrane. Some cells secrete muscus (sticky substance) so these cells called goblet cells.	Wave like movement of cilia moves the content/particles in only one direction.
Locations: • Lining of blood vessels, lymph vessels, Alveoli • In heart	**Locations:** • Kidney tubules • Thyroid, sweat, salivary glands • Ovaries	**Location:** • Lining of G.I.T. (Stomach, intestine)	**Locations:** • Upper respiratory track • In uterine tubes
Functions: • Protection, filteration and diffusion of substances	**Functions:** • Secreation • Absorption	**Functions:** • Protection • Secreation • Absorption	**Functions:** • In respiratory track, propel mucus towards throat • In uterine tubes propel ova towards uterus

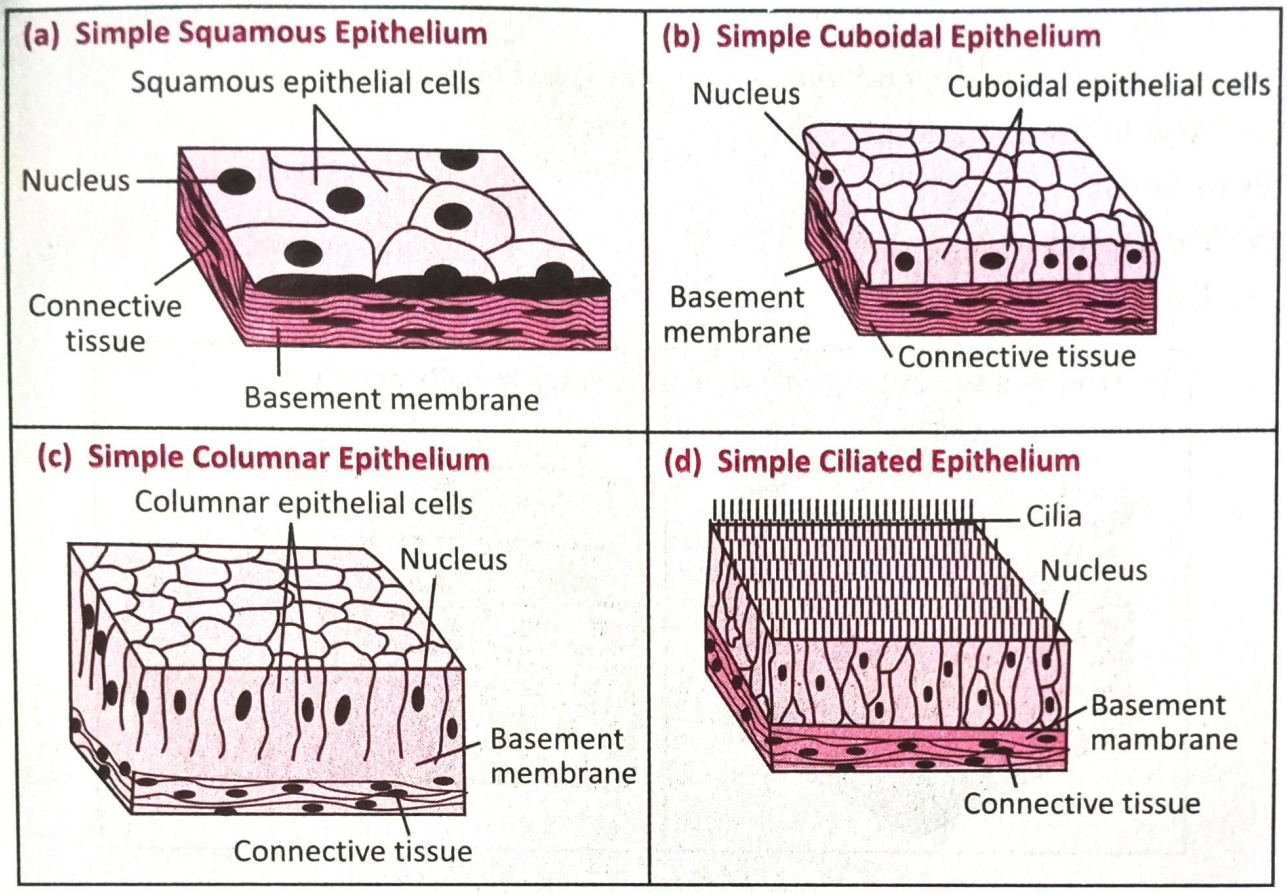

Fig. 3.3: ***Types of Epithelial Tissue***

B. Compound/Stratified Epithelial Tissue (Several Layers)

1. **Stratified Squamous Epithelium:** Cells at the upper surface are flattened and at the deepest layer – cells are mainly columnar.

   They are of two types:

   (a) **Keratinised Stratified Epithelium:** Surface layer consists dead epithelial cells that contain the protein keratin which is a tough fibrous protein that prevents drying of underlying tissue.

   Location: It is found in dry surface skin, hair, nails.

   (b) **Non-keratinised Stratified Epithelium:** Cell die but not contain protein keratin.

   Location: Found in wet places lining of mouth, esophagus, covers the tongue.

2. **Transitional Epithelium:**

   - This tissue has variable appearance.
   - Upper layer is cuboidal epithelium below that 3-4 layer of oval shaped cells.
   - All cells are held together by cement which is slimy in nature and allows cells to slip over one another.

Locations:

- In urinary bladder and allows stretching as bladder fills.
- Also in urethra and ureters.

Functions:

- Distension of organ.
- Excretion of urine.

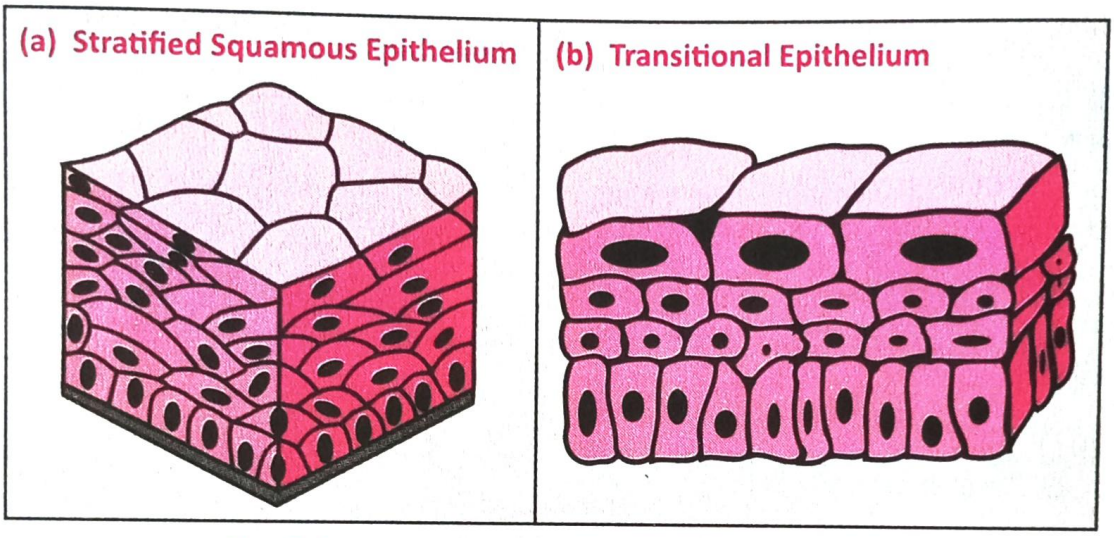

Fig. 3.4: *Types of Compound Epithelial Tissue*

CONNECTIVE TISSUE

Connective tissue is one of the most abundant and widely distributed tissues in the body.

Functions of Connective Tissue

- Binding and support
- Protects and insulates internal organ
- Acts as a major transport system, e.g., blood
- Give immune response.

General Characteristics of Connective Tissue

Connective tissue consists of cells, fibres and ground substance (Water & Polysaccharides proteins).

1. **Cells of connective tissue are as follows:**
   (a) **Fibroblast:** These are large, flat, with branching process.
   (b) **Fat cells or adipocytes:** These cells store fat.

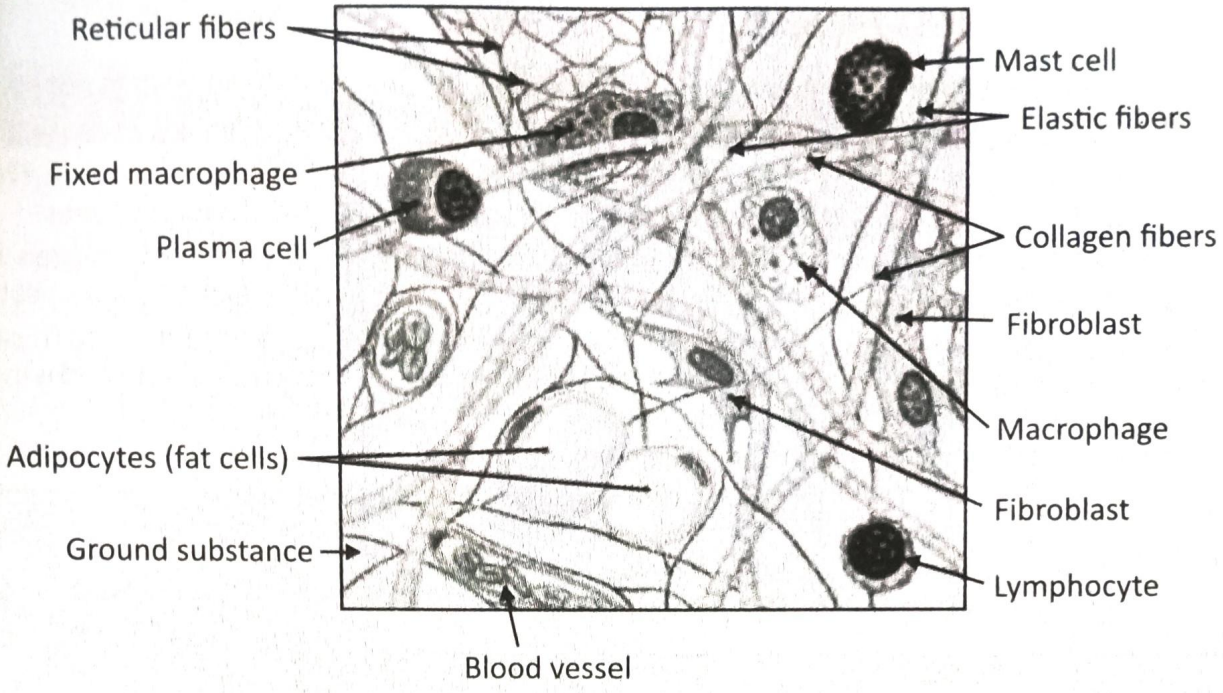

Fig. 3.5: ***Connective tissue with its cells, fibres and ground substance***

(c) **Macrophages (Macro-large, Phages-eater):** Macrophages develop from monocytes (white blood cells). Macrophages have irregular shape. Macrophages engulf bacteria and cellular debris by phagocytosis.

(d) **Mast Cells:** They produce histamine which dilate blood vessels in inflammatory response that body's reaction to injury or infection.

(e) **Plasma Cells:** These cells develop from B-lymphocytes (a type of WBCs). Plasma cells secrete antibodies (proteins) that attack on foreign substances in the body and neutralize them. Thus plasma cells are an important part of the body's immune system.

(f) **White Blood Cells:** In certain conditions like infections, WBCs move from blood into connective tissue, e.g., neutrophils gather at the site of infection, eosinophils move at the site of the allergic response. These cells prevent infections and allergic reactions.

2. **Fibres of the Connective Tissue:** They strengthens and support connective tissue.

Table 3.2: Three types of connective tissue fibers

Collagen Fibres	Elastic Fibres	Reticular Fibres
• Occur in bundles lying parallel to one another. • Bundles give great strength. • It consists of protein 'collagen'. • Found in bones, cartilage, tendons and ligament	• Smaller in diameter than collgen fibres branch and join together to form a network. • It consists of protein elastin. • These are strong and stretchable. • Have elasticity, i.e., ablity to return to their original shape after being stretched. • Found in blood vessels walls, lung tissue, skin.	• Reticular fibres are thinner than collagen fibres. • It consists of collagen which is covered by glycoprotein. • It is found in soft organs such as spleen and lymph.
	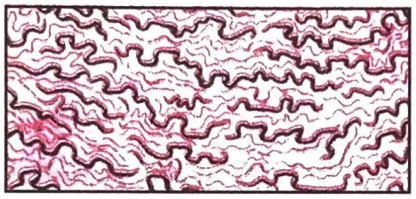	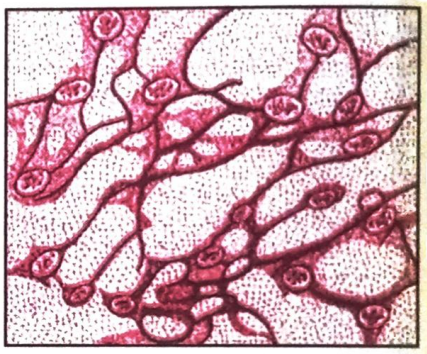

3. Reticular Fibres:

- Reticular fibres are thinner than collagen fibres.
- It consists of collagen which is covered by glycoprotein.
- It is found in soft organs such as spleen and lymph.

Classification of Connective Tissue

1. Areolar connective tissue
2. Adipose connective tissue
3. White fibrous tissue
4. Yellow elastic tissue
5. Blood
6. Bone tissue
7. Lymphoid tissue
8. Cartilage:
   (a) Hyaline cartilage
   (b) Fibro cartilage
   (c) Elastic cartilage

Table 3.3: Areolar and Adipose Connective Tissue

Areolar Connective Tissue	Adipose Connective Tissue
It is most widely distributed and found in almost every part of the body between muscles, blood vessels, nerves in the alimentary canal, body organs and attaches skin to underlying tissue. It contains fibers (collagen, elastic and reticular) and several kinds of cells fibroblasts, macrophages, plasma cells, mast cells, adipocytes and a few white blood cells embedded in a semifluide ground substance. **Functions:** • Provides elasticity and tensile strength, support. • It connects and supports other tissue. 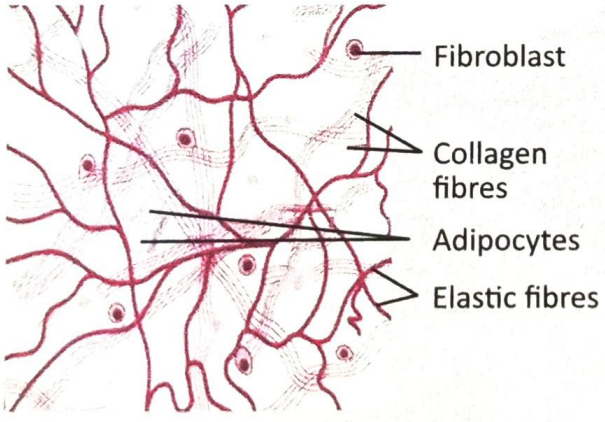 	It is present deep subcutaneous layer of the skin, around the heart and kidneys, padding around the joints and behind the eye ball in eye socket. Adipose tissue consists of cells that are called adipocytes. Adipocytes specifically store triglycerides (fat) as a large centrally located droplet. Nucleus and cytoplasm are peripherally located. **Functions:** • Supports and protects various organs. • Reduces heat loss through skin or maintain heat in the body. • Serves as energy reserve. 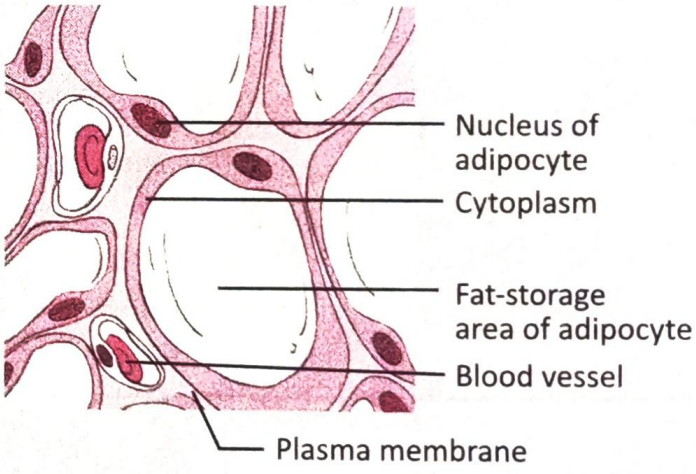

Table 3.4: Areolar and Adipose Connective Tissue

White Fibrous Tissue	Yellow Elastic Tissue
It consists of bundles of collagen fibres. Fibrocytes (old & inactive fibroblasts) found in rows between the bundles of fibres. **Function:** Provides strong attachments. **Locations:** • Tendons (attach muscle to bone) • Ligaments (attach bone to bone or binds bone together) • As an outer protective covering of bone called periosteum. • As an outer protective covering of some organs, e.g., kidney, lymphnodes, brain	Elastic tissue extends and recoils. It consists of elastic fibres. **Function:** Allows stretching of various organs. **Location:** It is found in organs where stretching or alteration of shape is required, e.g., in large blood vessels walls, trachea and bronchi and the lungs.
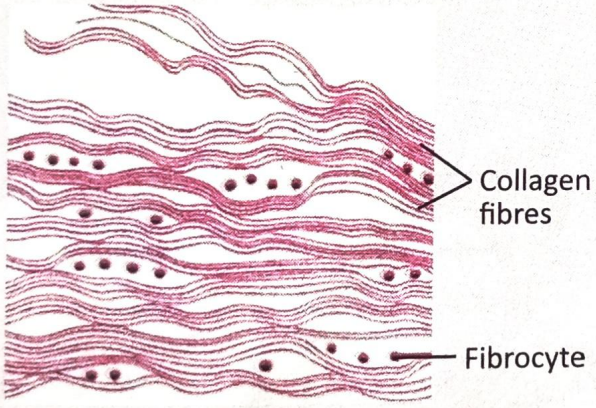	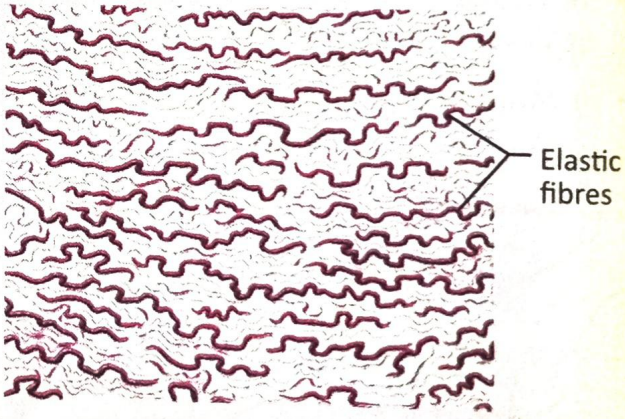

Blood

See Blood Chapter

Bone Tissue

Bone is the one of the hardest connective tissue in the body. It consists of a specialized type fibrous material hardened by calcium and phosphate.

Table 3.5: Classification of Bone Tissue

Compact Bone	Spongy Bone (Cancellous or Trabecular Bone)
• Hard or solid connective tissue. • Overall, about 80% of the skeleton is compact bone. • Compact bone tissue consists of a large number of concentric rings called Haversian system or osteons. • At the center, each osteons consists of a Haversian canal. It runs longitudinally and contains nerves, lymphatics and blood vessels. • The Haversian canals are surrounded by concentric plates called lamellae. • Between lamellae, there are small spaces called lacunae. It contains mature bone cells called Osteocytes. • Projecting from lacunae are Canaliculi. Due to Canaliculi. Haversian canals linked with lacunae. Through Canaliculi nutrients goes to the osteocytes and leave waste.	• Sponge or fine honey comb appearance. • Overall, about 20% of the skeleton is sponge bone. • Spongy bone do not contain Osteons or Haversian system but consists of thin columns called Trabeculae. • The central Haversian canal are much larger and there are fewer lamellae as compared to compact bone.

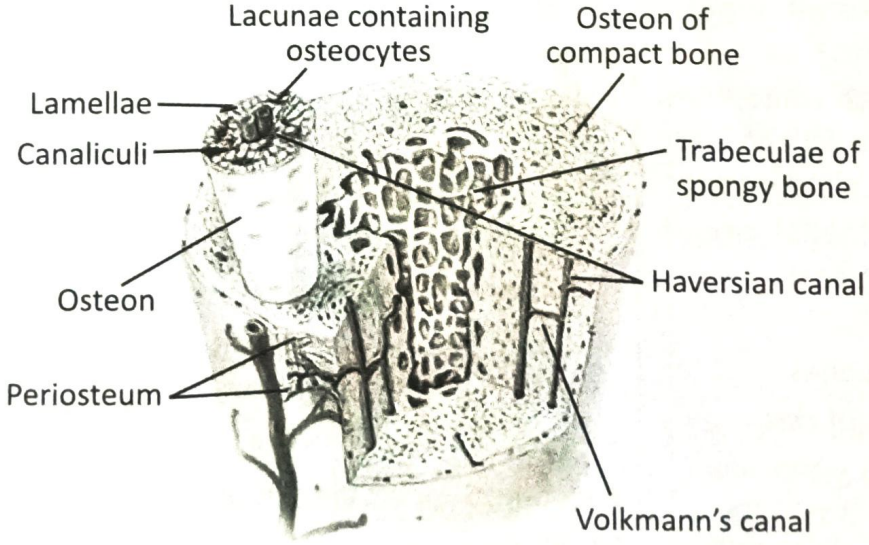

Fig. 3.6: ***Bone Tissue***

Location of Bone Tissue:

Both compact and spongy bone tissue make up the various parts of bones of the body.

Functions of Bone Tissue:

- Assists in movements
- Protect internal organs
- Support soft tissue and provides attachment for skeletal muscles.
- Stores and releases minerals, e.g., calcium, phosphate.
- Contains red bone marrow which produces blood cells.
- Contains yellow bone marrow which stores fats (Triglycerides).

Lymphoid Tissue

See Lymphatic Chapter

Cartilage

It consists of a dense network of collagen fibres and elastic fibres. The cell of mature cartilage called chondrocytes occurs singly or in groups.

Table 3.6: Types of Cartilages

Hyaline cartilage	Fibro cartilage	Elastic cartilage
It is most abundant type of cartilage. It consists of bluish white, shiny ground substance with collagen fibres and many chondrocytes. Chondrocytes (cells) are in group within cell nest. **Locations:** • Ends of long bones • Anterior ends of ribs • Nose • Part of larynx • Trachea • Bronchi, bronchial tubes. **Functions:** • Provide flexibility and support. • Allow movement to bones.	It consists of chondrocytes scattered among bundles of collagen fibres within the matrix. **Locations:** • Intervertebral disc (disc between vertebrae) • Pubic symphysis (point where hip bones join) • Cartilage pads of knee. **Function:** Support and fusion to bones.	It consists of thread like network of elastic fibres within the matrix. Chondrocytes located in a fibres. **Locations:** • Pinna or lobe of ear • Epiglottis • Auditory tubes. **Function:** Gives support and maintains shape.

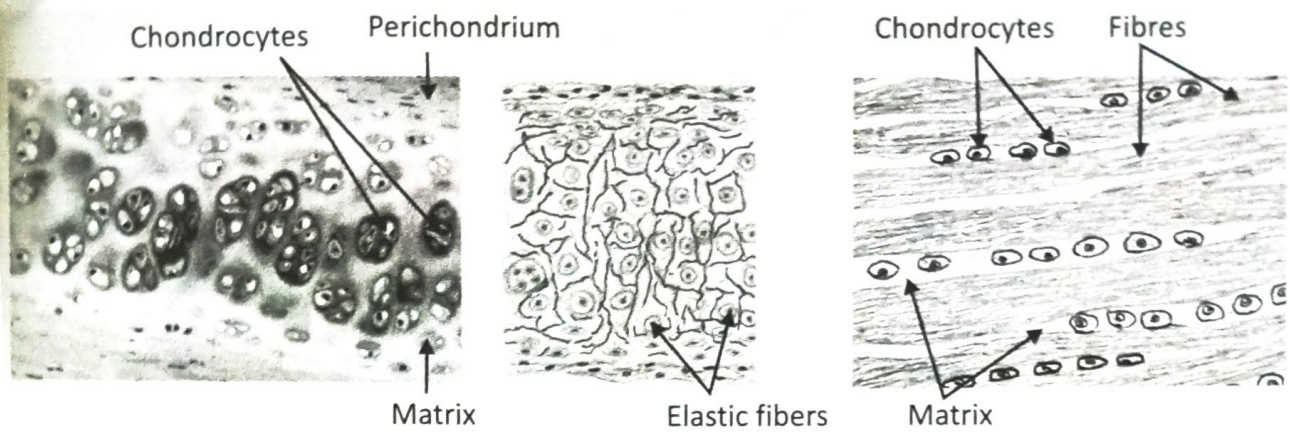

Fig. 3.7: *Types of Cartilages*

MUSCLE TISSUE

Muscle tissue consists of elongated cells called muscle fibres. These muscle fibres use ATP (Adenosine Triphosphate) to generate force. Due to this force, muscle tissue produces body movements, maintain posture and generate heat.

Based on location and structural and functional features muscle tissue is classified into three types:

Skeletal Muscles (Voluntary Muscles)	Cardiac Muscles (Involuntary Muscles)	Smooth Muscles (Involuntary Muscles)
Location: Attached to the bones of the skeleton.	**Location:** In the wall of the heart.	**Location:** In the internal structures of visceral organs such as blood vessels, stomach, intestine, gallbladder
It is also called striated because muscle cells or fibres contain alternating light and dark bands seen under microscope.	It is also striated because striations are seen under microscope.	They are non striated, does not have striations hence called smooth muscles.
Skeletal muscles are voluntary because it can under the control of our will that is contract or relax by conscious level.	Cardiac muscles is involuntary because it cannot under the control of our will that is not contract or relax by conscious level.	Smooth muscle muscles are involuntary because it can not under the control of our will that is not contract or relax by conscious level
These are long, cylindrical in shape.	These are cylindrical in shape.	These are spindle shaped.

Skeletal Muscles (Voluntary Muscles)	Cardiac Muscles (Involuntary Muscles)	Smooth Muscles (Involuntary Muscles)
Their ends are blunt	Their ends are blunt	Their ends are tapering
These are unbranched	These are branched	These are unbranched
These are occur in bundles	They form three dimensional network.	They occursingly, in sheets and small bundles.
Blood supply is abundance	They are rich in blood supply	Blood supply is poor
They are innervated by the branches from cranial and spinal nerves.	They are innervated by the autonomus system.	They are innervated by the Autonomus system.
Striated muscle fibers are multi-nucleated.	Cardiac muscle fibres are uninucleated.	Smooth muscle fibres are multi-nucleated.
They easily get fatigued.	They do not fatigued.	They do not fatigued.
They contract quickly	They show rhythmic contraction.	They contract slowly.

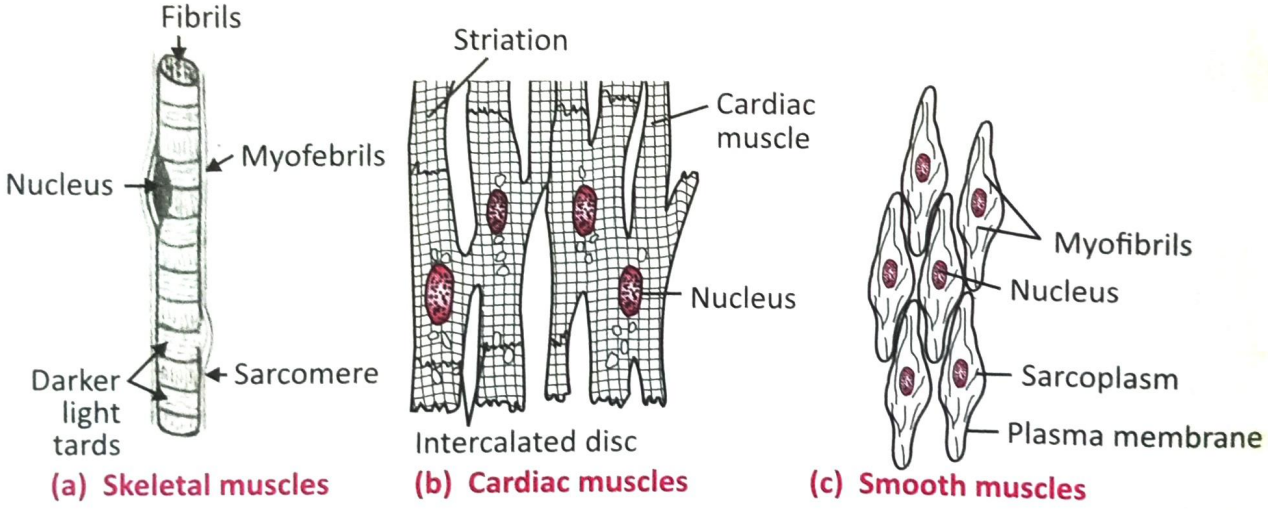

Fig. 3.8: ***Types of Muscle tissue***

NERVOUS TISSUE

Nervous tissue is located in nervous system (brain). Nervous tissue consists of:

- Nerve cells that is neurons (excitable cells to produce action potential or impulse in response to stimuli).
- Neuroglia (protective and supporting cells).

Functions of Nervous Tissue

Give response to various type of stimuli. Neurons converts stimuli into nerve impulse (action potential) and conduct these impulse to other neurons to muscle tissue or to glands.

Neuron

Neurons consists of:

1. The Cell body
2. Dendrites cell processes
3. Axons

1. **The cell body:** Cell body contains a nucleus surrounded by cytoplasm and other organelles like golgi apparatus mitochondrian, ER.
2. **Dendrites (dend-tree)** are tapering, highly branched and usually short cell processes. They receive and carry impulses towards the cell bodies.

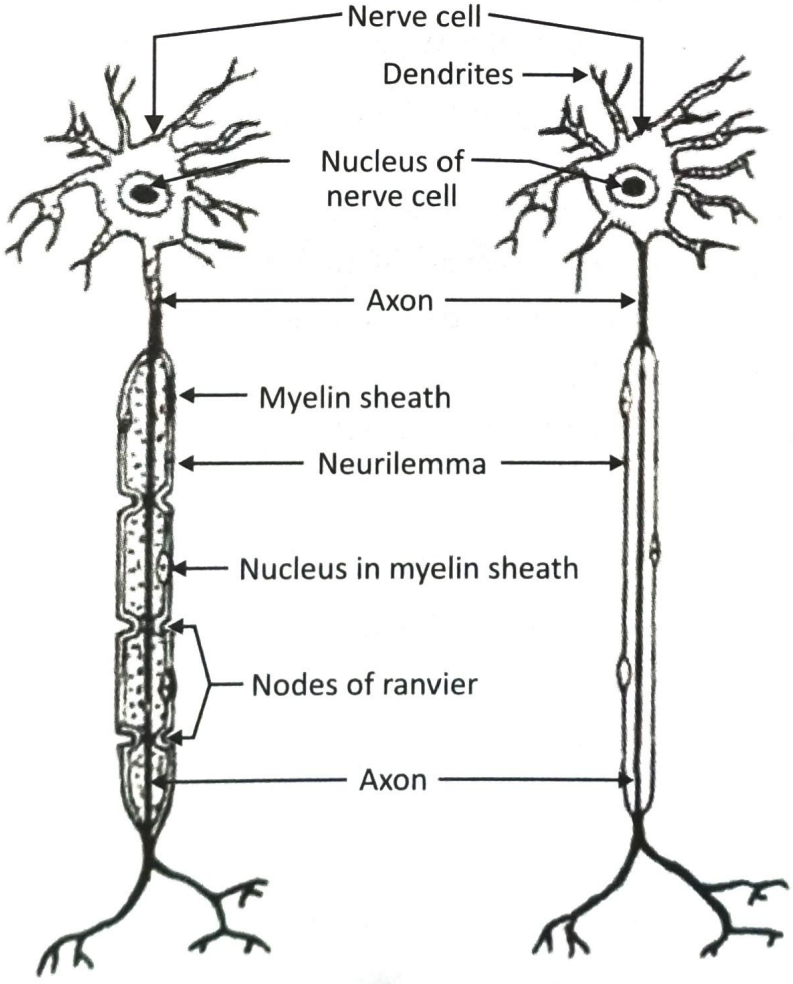

(a) Myelinated neuron (b) Non-myelinated neuron

Fig. 3.9: *Neuron*

3. Axons: Axons consists of the following parts:
   (a) **Axolemma:** It is the membrane of axon and contains axoplasm.
   (b) **Myeline sheath:** It is a sheath of fatty material which surrounds most axons and gives them white appearance.

   The myeline sheath is absent at intervals along the length of the axon. These intervals are called 'Nodes of Ranvier'. They contribute to rapid transmission of nerve impulse along myelinatedfibres.
   (c) **Neurilemma:** It is the outermost covering of the axon and the myelin sheath.

   Bundles of axon bound together are called together nerves.

IMPORTANT QUESTIONS

1. Name the fundamental tissues which make up the body as a whole. (W-96, 00; S-97, 98, 00)
2. Describe different types of Epithelial tissue. (S-96; W-02)
3. Classify connective tissue. (S-01, 02; W-98)
4. Describe cartilage as a tissue. (S-99, 2000)
5. Define bone. (S-2000)
6. Describe microscopic structure of bone. (S-01)
7. Classify muscular tissue. Give example of each (S-98; W-99)
8. Differentiate between smooth and striates muscles. (S-96, 00; W-02)
9. Explain neuron. (S-00; W-02)
10. Explain the terms neurons and neuroglia (W-01)

4

CHAPTER

Skeleton System

INTRODUCTION

Skeleton or skeletal system is the bony cartilaginous framework of the body. The bones, muscles and joints together form an integrated system called the musculoskeletal system.

FUNCTIONS OF SKELETON OR SKELETAL SYSTEM

1. Skeleton gives shape to the body.
2. It gives support to the body.
3. It gives protection to delicate organs.
4. Skeleton form joints which give movement to the body.
5. It provides attachment for the muscles.
6. It acts as as store house of minerals like Calcium and Phosphorus.
7. Skeleton forms red blood cells (haemopoietic function) in its red bone marrow.

CLASSIFICATION OF SKELETON

Skeleton is classified into two types:

1. **Axial Skeleton:** It includes bones along axis of the body. These are total 80 bon Skull, hyoid, auditory ossicles (bones of middle ear), vertebral column, thora
2. **Appendicular Skeleton:** It includes bones of appendages and girdles that connected to axial skeleton. These are 126 bones. Pectoral (shoulder girdles), u fore limbs, pelvic girdle, lower/hind limbs.

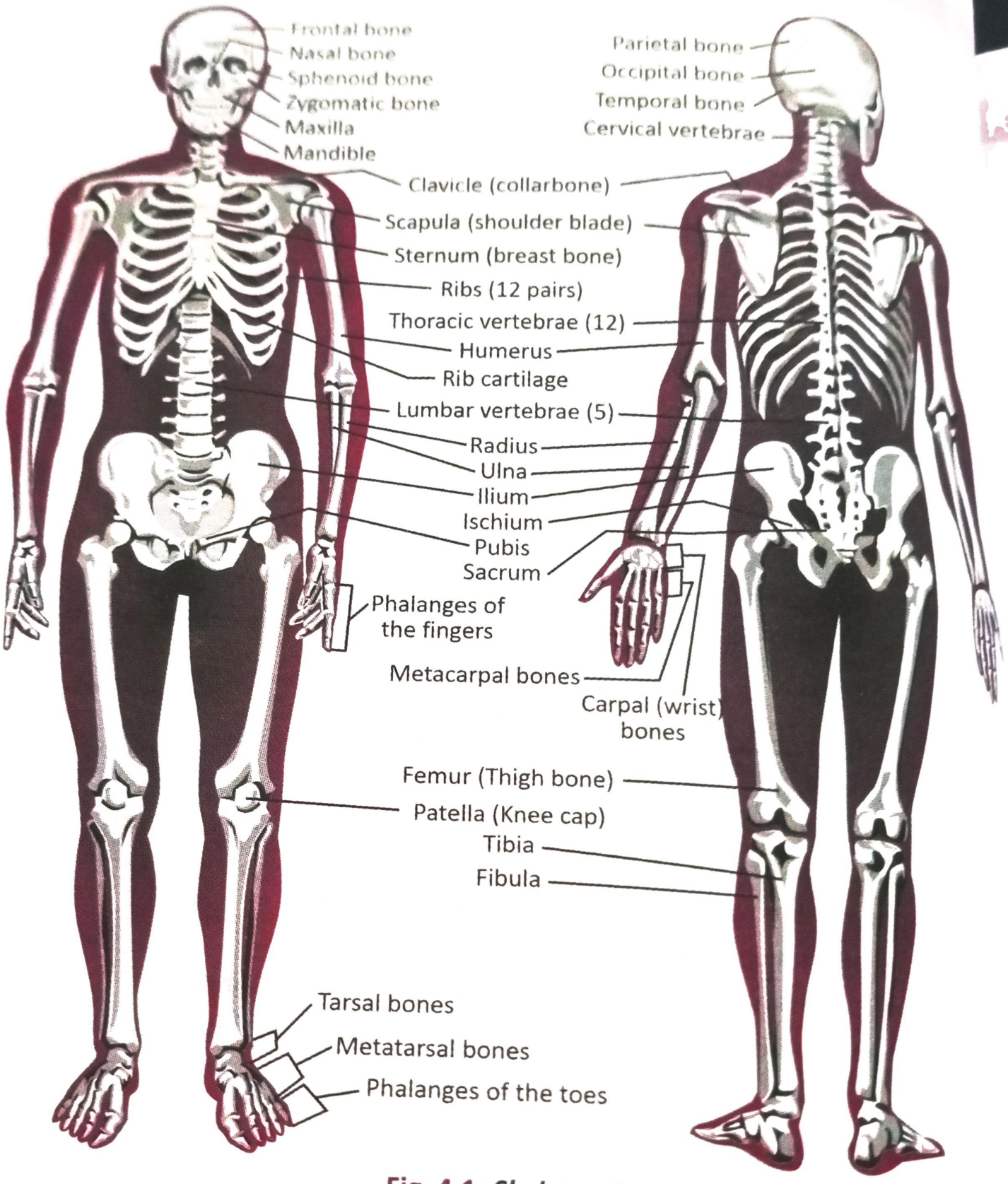

Fig. 4.1: *Skeleton System*

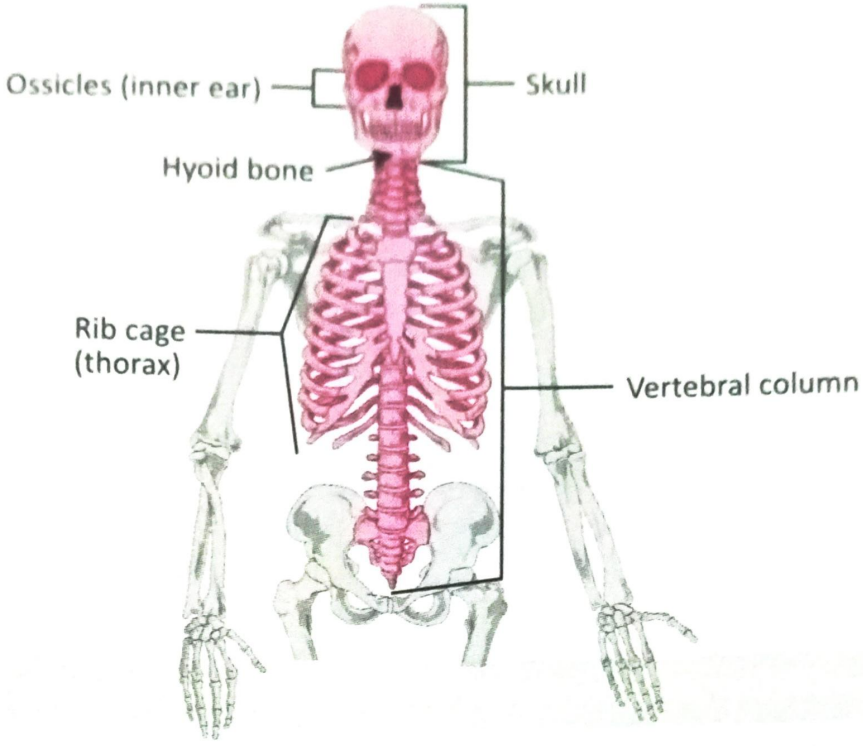

Fig. 4.2: *Axial Skeleton Structure*

Axial Skeleton—Total Number of bones are 80	
1. Skull–Cranium: Frontal bone-1 Parietal bone-2 Temporal bones-2 Occipital bone-1 Sphenoid bone-1 Ethmoid bone-1	Total bones of cranium are 8
2. Face: Zygomatic or cheek Bones-2 Maxilla-2 Nasal bones-2 Turbinated or inferior Nasal conchae-2 Vomer-1 Lacrimal bones-2 Palatine bones-2 Mandible-1	Total bones of face are 14

3. **Hyoid Bone**-1 between mandible and larynx, hyoid bone support the tongue.	Hyoid bone-1
4. **Auditory Ossicles** (bones of middle ear)	Total auditory ossicles-6
5. **Vertebral Column:** Cervical vertebrae-7 Thoracic vertebrae-12 Lumbar vertebrae-05 Sacrum-01 Coccyx-01	Total bones of vertebral column-26
6. **Thorax:** Sternum-1 Ribs-24	Total bones of thorax-27
Appendicular skeleton-structure – Total Number of bones are 126	
1. **Pectoral (Shoulder) Girdles:** Clavicle-2 Scapula-2	Total bones of pectoral girdles-4
2. **Upper or Lower Limbs:** Humerus-2 (arms) Ulna-2 (forearms) Radius-2 (forearms) Carpals-16 (wrist) Metacarpals-10 (Palm) Phalanges-28 (digits bones in hands)	Total bones of hands or upper limbs-60
3. **Pelvic (hip) Girdle Hip,** pelvic or coxal bones-2	Total bones of Pelvic (hip) Girdle-2
4. **Lower or Hind Limbs:** Femur-2 Tibia -2 Fibula-2 Patella-2 Tarsals (7-7)-14 Metatarsals (5-5)-10 Phalanges (14-14)-28	Total bones of legs or lower limbs-60

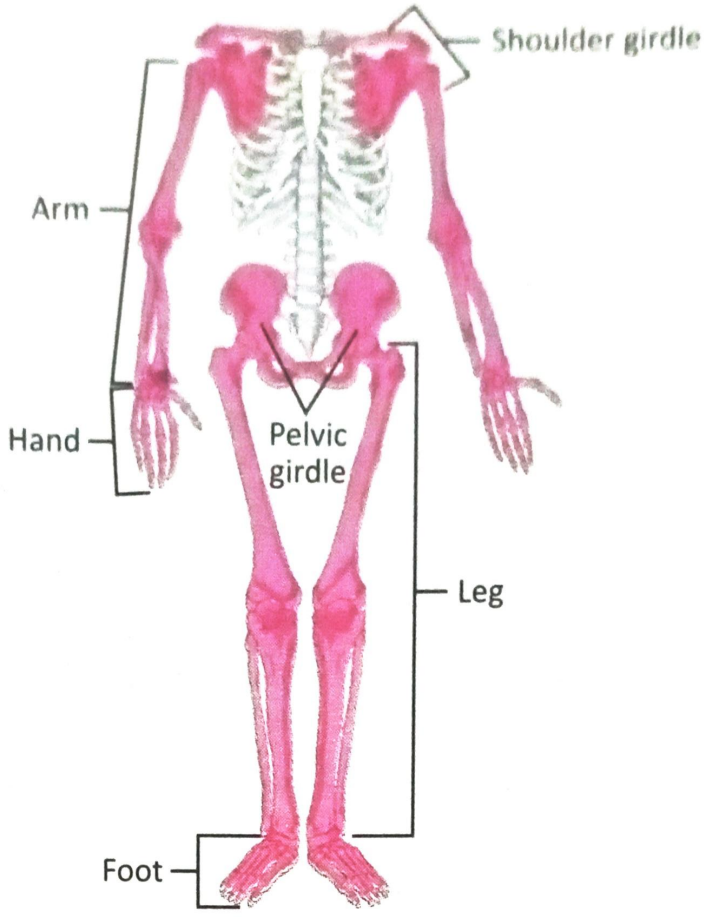

Fig. 4.3: ***Appendicular Skeleton Structure***

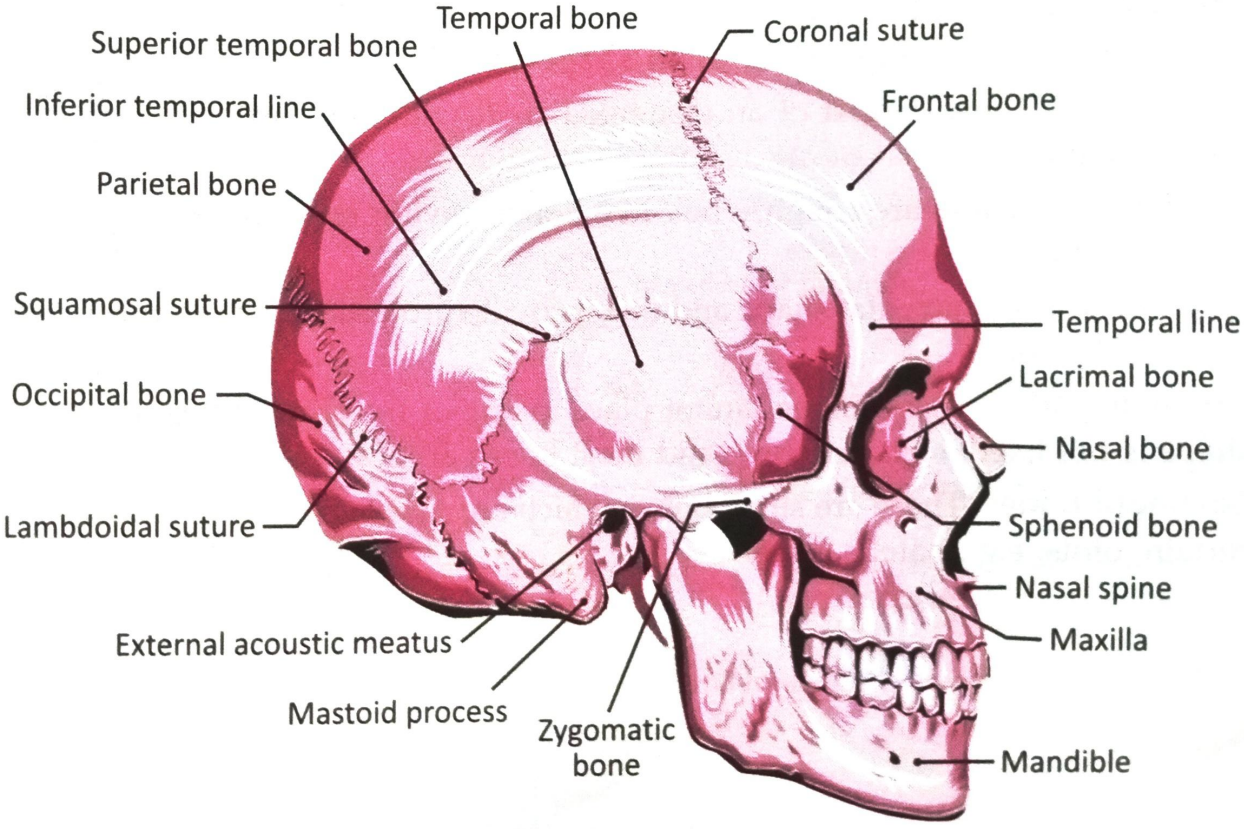

Fig. 4.4: ***Bones of Skull***

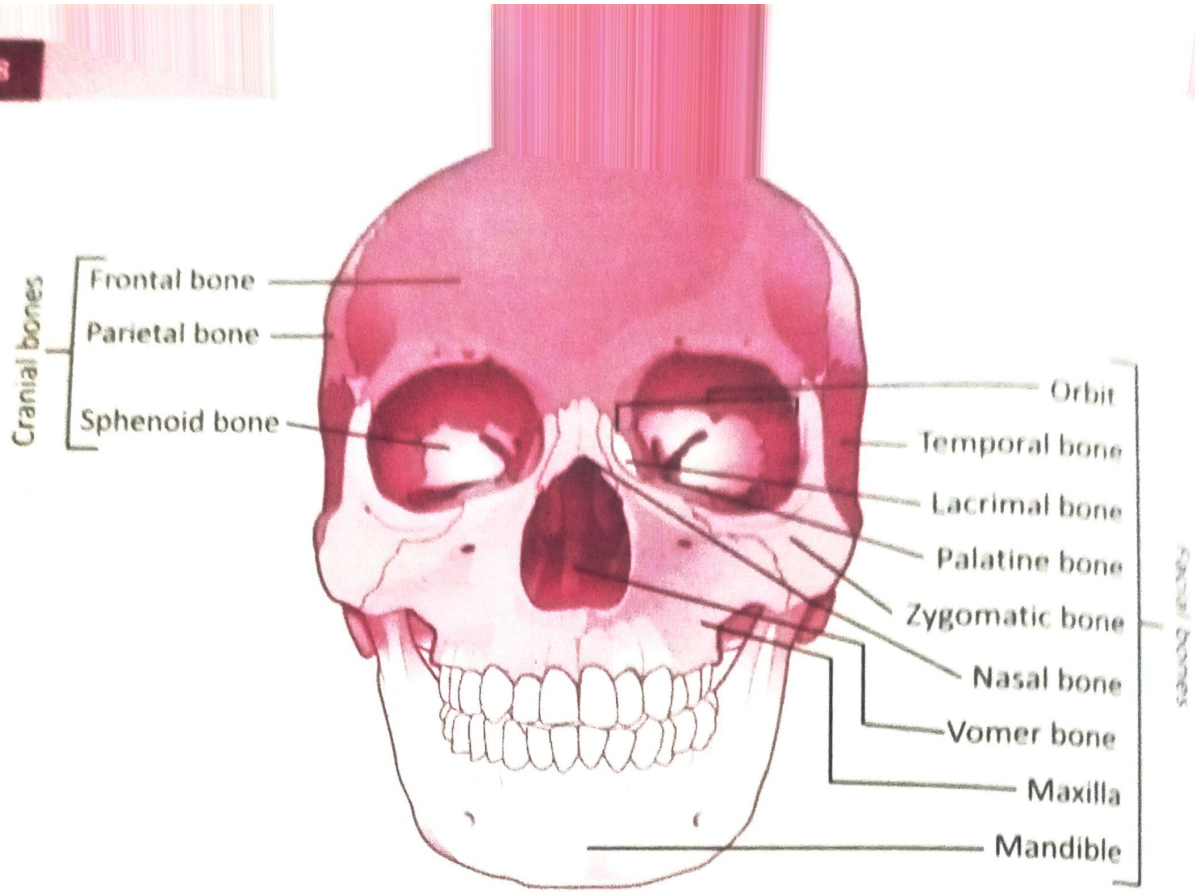

Fig. 4.5: *Facial Bones*

CLASSIFICATION OF BONES

Classification of Bones depending upon shape and size:

1. **Long Bones**: These consist of an elongated shaft with two extremities, e.g., femur, tibia, fibula.
2. **Short Bones**: These are roughly box like bones having no shaft, e.g., wrist, carpal and tarsal bones.
3. **Flat Bones**: They have flat shape and they provide protection, e.g., sternum, scapula, bones of the skull.
4. **Irregular Bones:** These bones cannot place in any of the above categories and their shape is not fixed, e.g., vertebrae and most bones of face.
5. **Sesamoid Bones:** These are small bones which are developed in the tendons around certain joints, e.g., patella bone.

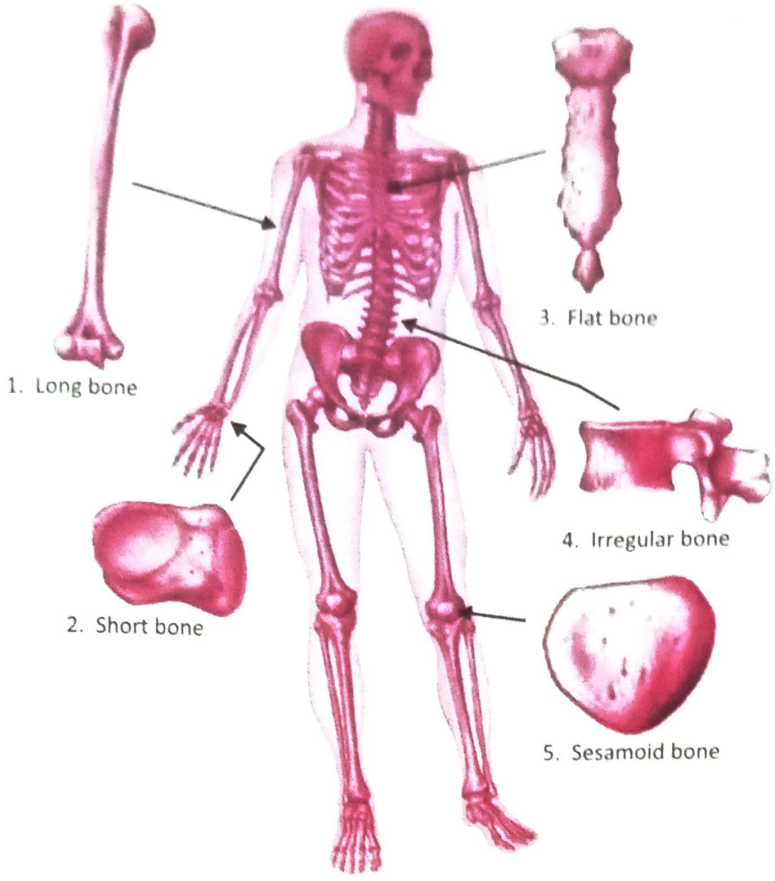

Fig. 4.6: ***Classification of the Bones***

ule (mand –to chew) or lower jaw is the largest, strongest and movable facial bone. ,nates as two identical parts and these parts unite at a midline.

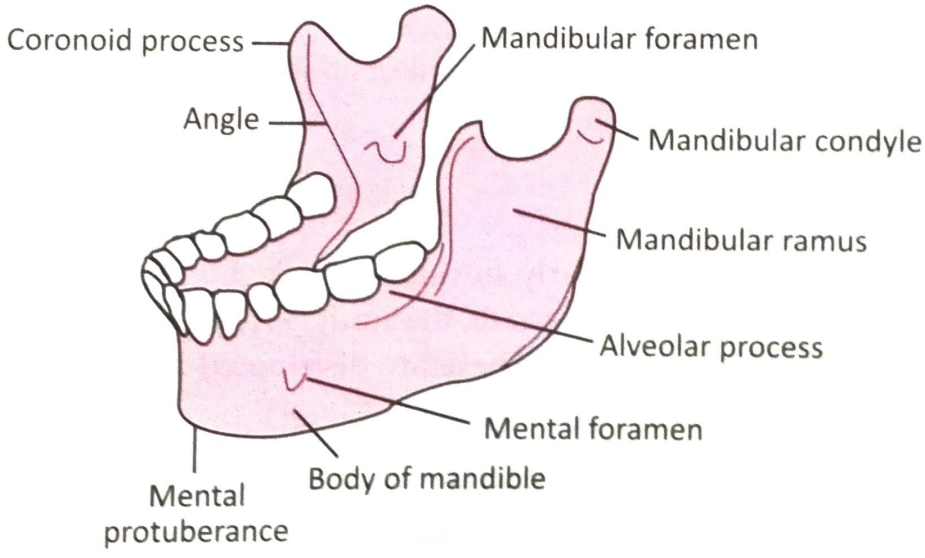

Fig. 4.7: ***Mandible***

Every part consists of two sub-parts:

1. A curved body on the superior surface of which there is a alveolar ridge containing the lower teeth.
2. Ramus which are perpendicular portions protrude upwards at right angles to the body. This is known as angle of jaw.

At the upper end, each ramus has two two processes:

1. **Condylar Process:** This articulates with temporal bone and form temporomandibular joint.
2. **Coronoid Process:** Which joins with temporalis muscle.

VERTEBRAL COLUMN

The vertebral column is also called spine or backbone. It consists of a series of bones called vertebrae (singular-vertebra). It is the major axis of the human body.

Location

Vertebral column is located mid dorsally along the axis of the body.

Functions of Vertebral Column

- Vertebral column forms major supporting axis of the body.
- It gives strength, support and balance to the body
- It provides rigidity and flexibility needed for trunk.
- It provided the site for the attachment of muscles.
- It protect the spinal cord.
- It supports the head and serves as apoint of attachment for the ribs, pelvic girdles and muscles of the back.

Structure

Total number of vertebrae during early development is 33. Then several vertebrae in sacral and coccygeal regions fuse. As a result, the adult vertebral column also called spinal column, typically contain 26 vertebrae. These are distributed as:

- 7 cervical vertebrae (cervic-neck) in neck region.
- 12 thoracic vertebrae (thorax-chest) in back of thoracic cavity.
- 5 lumbar vertebrae (lumb-loin) is at lower back.
- 1 sacrum (sacred bone) consists of 5 fused sacral vertebrae.

- 1 coccyx (cuckoo, because the shape resembles the bill of a cuckoo bird) consists of 4 fused coccygeal vertebrae.

Whereas Cervical Thoracic Lumbar vertebrae are movable but Sacrum & Coccyx are not movable.

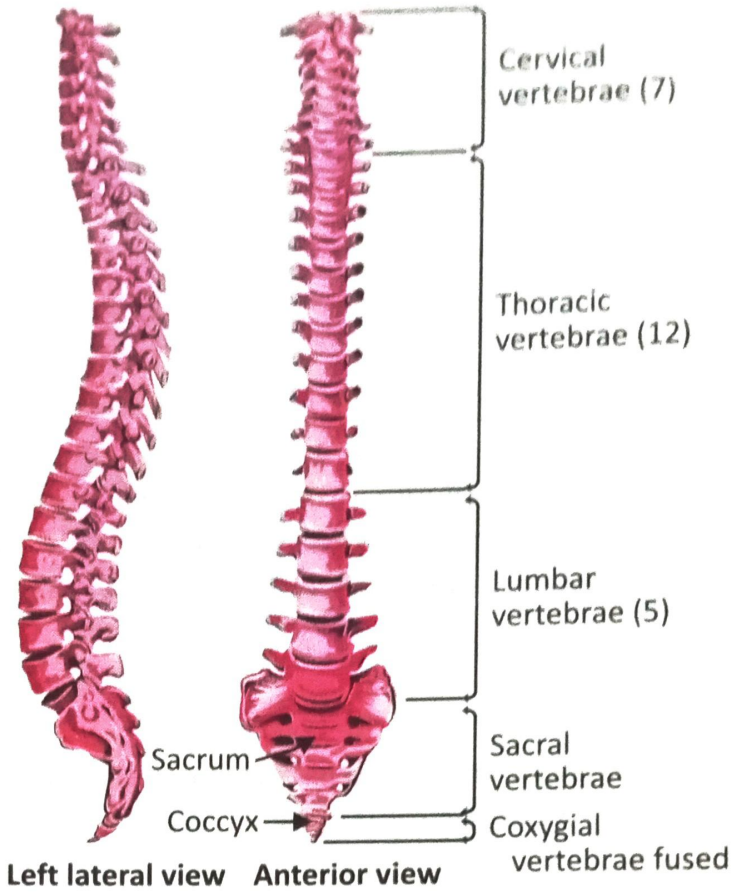

Fig. 4.8: ***Vertebral Column with Vertebrae***

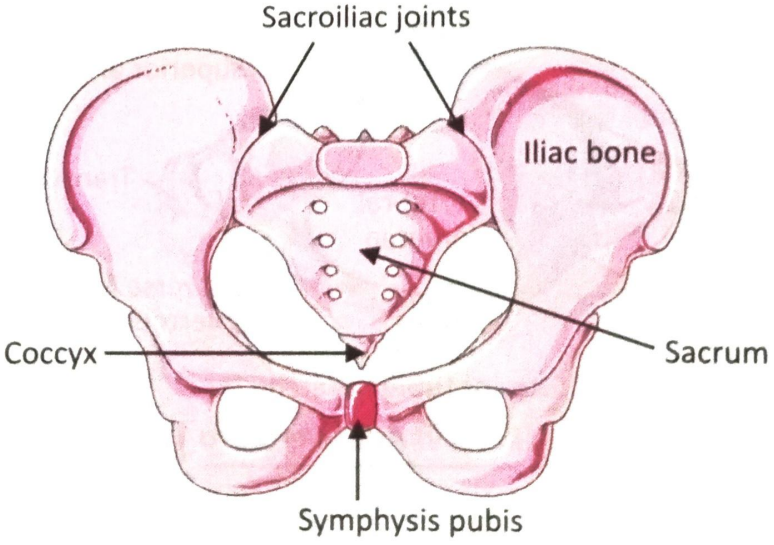

Fig. 4.9: ***Pelvic Girdle***

CHARACTERISTICS OF TYPICAL VERTEBRA

Vertebrae in different regions of vertebral column shows difference in their shape, size and structure but all of them shows a basic structure.

A typical vertebra has following structures:

- **A body or centrum:** It situated anteriorly. It is thick, flat solid and disc shaped part. The size varies according to its position. It is smaller in the cervical region and becomes larger towards the lumbar end.
- **Vertebral or neural arch:** Extends posterior from the body. This arch encloses a large foramen called as vertebral foramen through which spinal cord passes. Neural arch on its superior and inferior surface shows paired articular facets to articulate with adjacent vertebrae.
- **Processes:** Mid–dorsally the neural arch shows a elongated spine like structure called spinous processes and are bifid at the ends giving attachment for muscles. A bony ridges at the base of spinous processes are called lamina. Laterally, neural arch shows a pair of transverse processes for muscle attachment. Each transverse process exhibits a foramen through a vertebral artery passes to the brain.

CERVICAL VERTEBRAE

Vertebrae located in the neck region are called as cervical vertebrae. These are 7 in number. First 2 are atypical (different) where as remaining as five are typical.

First cervical vertebra or Atlas vertebra:

- Body is highly reduced and is located anteriorly.

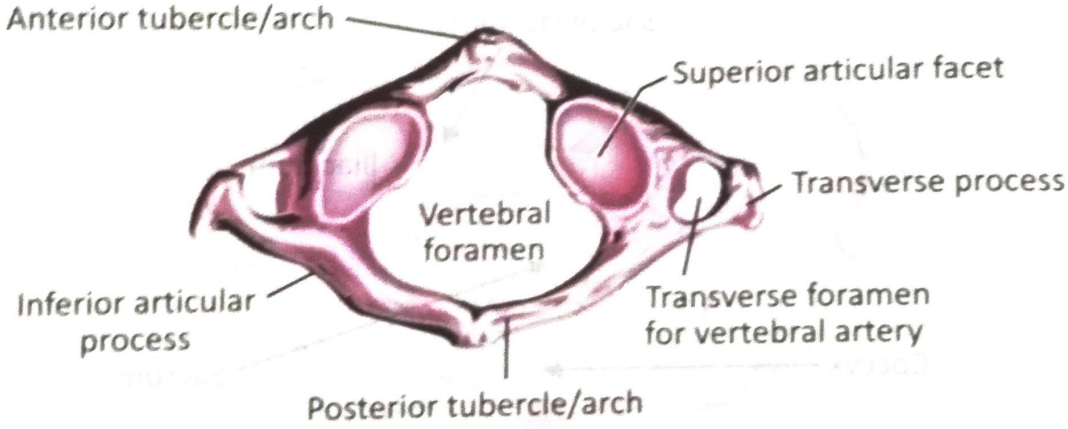

Fig. 4.10: *Atlas Vertebra*

- Vertebral arch is bony ring like structure which has two short transverse processes. The anterior part is occupied by odontoid process or dens (tooth) of second cervical vertebra (axis). This represents the body of atlas and form pivot joint. This joint permits sidewise movement.

The posterior part of the ring is the true vertebral foramen and is occupied by spinal cord.

The superior surface of the bone presents two articular facets. These facets forms joint with two condyles of occipital bone of the skull. (Atlanto-occipital joints) which is responsible for nodding movement of head.

Second cervical vertebra or Axis vertebra

- It is the second atypical vertebra present below the atlas.

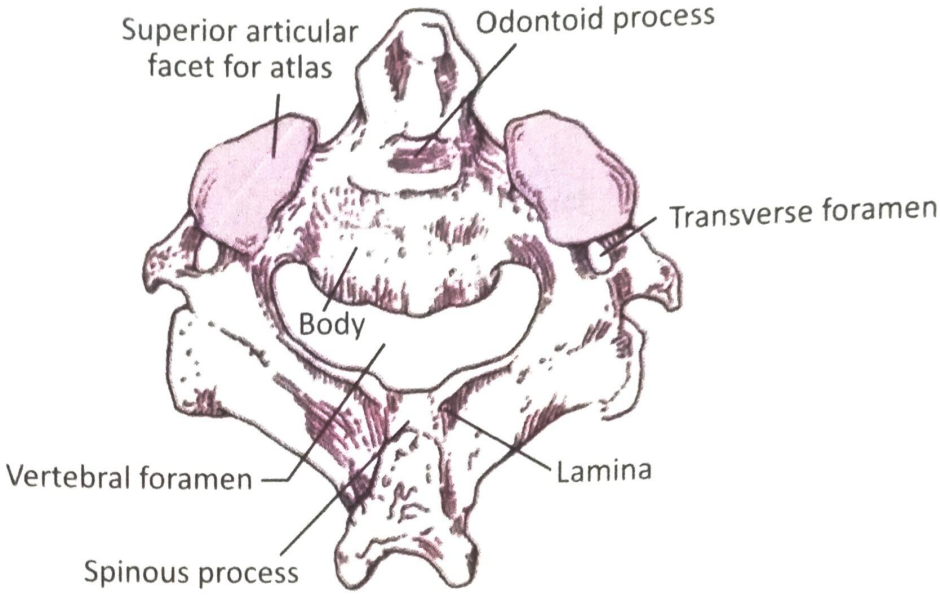

Fig. 4.11: ***Axis Vertebra***

- **Its characteristics are:** Body is modified and reduced and an elongated process called odontoid process/dens (tooth) arise from the body. The dens articulates with anterior cavity of first vertebra to form pivot joint (atlanto-axial joint) which allows rotation-turning of the head from side-to-side.

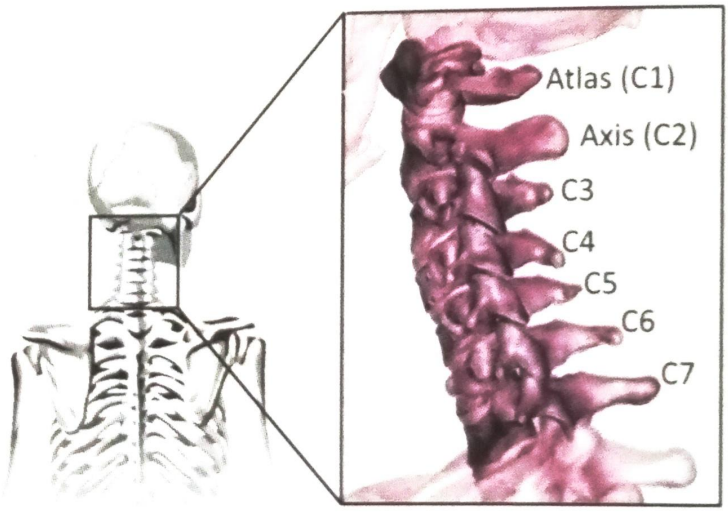

Fig. 4.12: ***Cervical Spine***

THORACIC VERTEBRAE

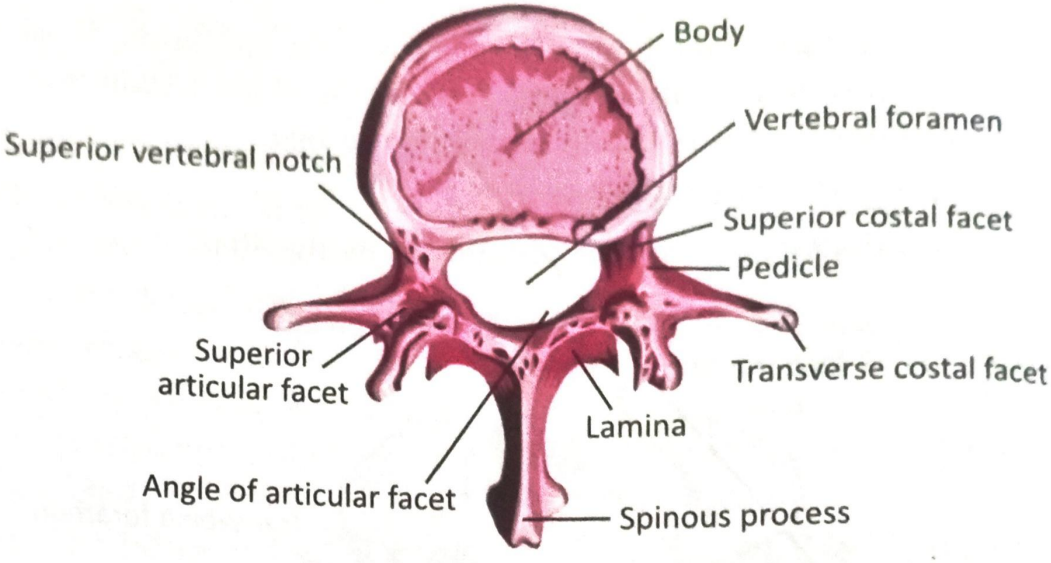

Fig. 4.13: ***Thoracic Vertebrae***

The vertebrae in the thoracic region are known as thoracic vertebrae. The characteristics of thoracic vertebra are:

1. They are larger &stronger than cervical vertebrae.
2. Its transverse processes have longer and larger than cervical vertebrae.
3. The spinous processes on T1 and T2 are long, flat directed inferiorly (downwards) so that they partly overlap each other.
4. In contrast, the spinous processes on T11 & T12 are shorter, broader & directed more posteriorly (to back side)
5. The bodies and transverse processes have facets for articulation with ribs.

LUMBAR VERTEBRAE

The vertebrae in the lumbar region are called as lumbar vertebrae. They are largest and strongest to bear the weight of above vertebrae. The spinous Processes are thick and broad and point downwards for the attachment of larger back muscles.

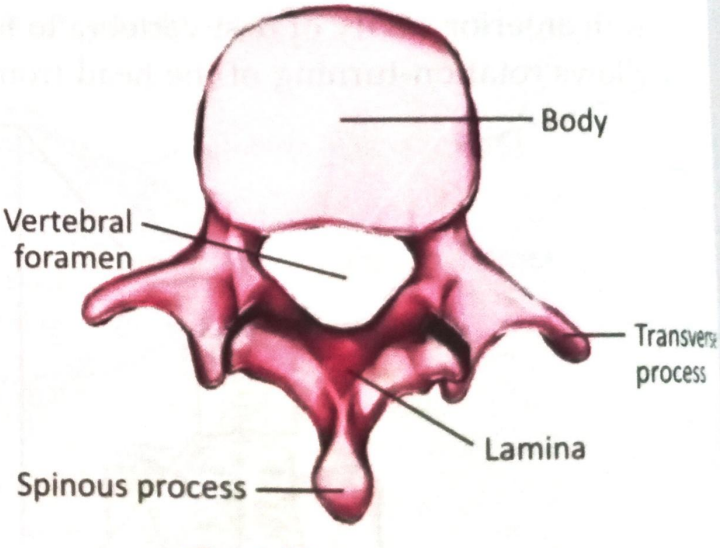

Fig. 4.14: ***Lumbar Vertebrae***

SACRUM

Sacrum is located below the last lumbar vertebra and in between the two hip bones of pelvic girdle. It is triangular bone formed by the union of 5 vertebrae. The ventral surface of sacrum is smooth and concave whereas dorsal surface is rough and convex.

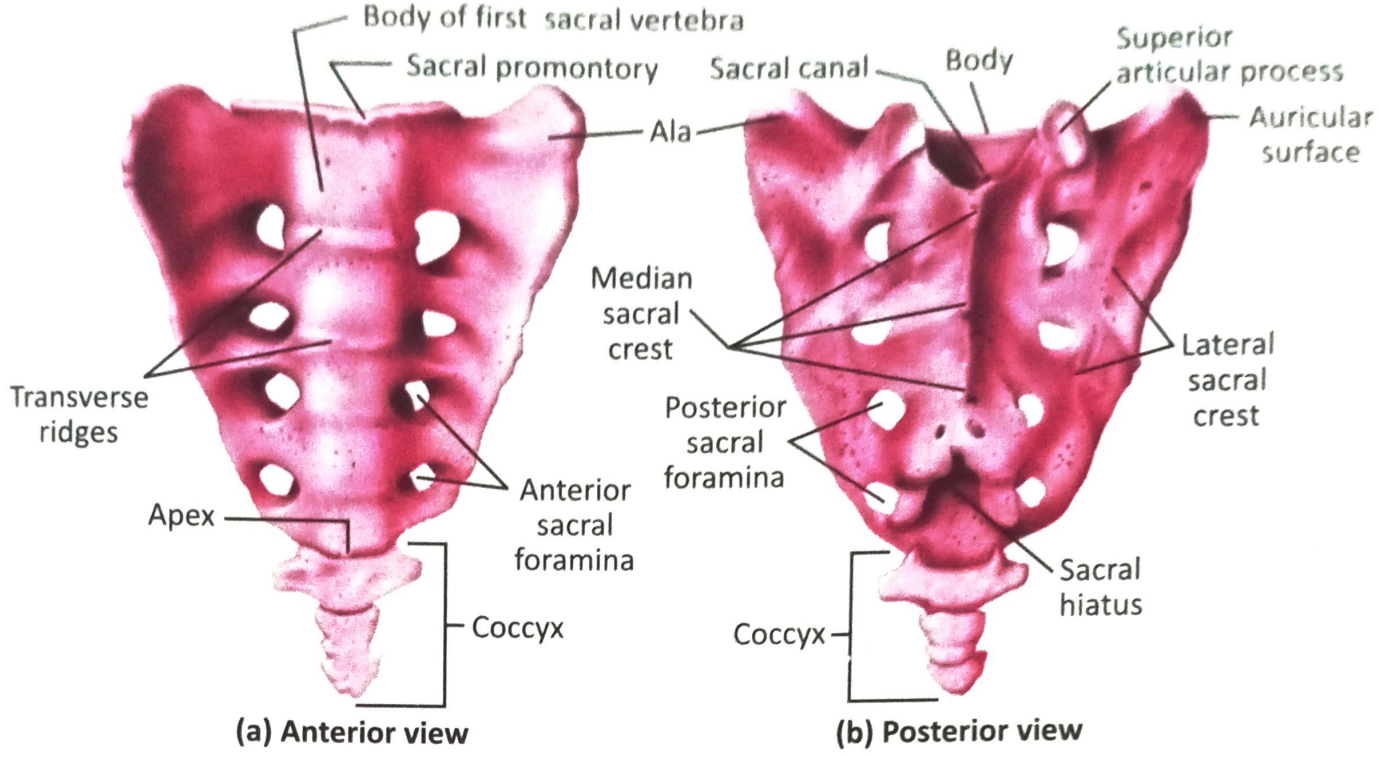

Fig. 4.15: ***Sacrum and Coccyx***

Laterally sacrum shows 4 pairs of opening between the fused vertebrae. These opening are called sacral foramen through spinal nerves passes out. In female sacrum is shorter, wider and more curved anteriorly where as in male sacrum is longer, narrower and less curved anteriorly.

COCCYX OR TAIL BONE

It shows four terminal vertebrae fused together to form a very small triangular bone. The broad base articulates with tip of the sacrum.

THORAX OR THORACIC CAGE

Thorax or Thoracic cage is bony enclosure formed by the sternum, costal cartilage, ribs and the bodies of the thoracic vertebrae. It is narrow at superior end and broader at its inferior end.

Function of Thoracic Cage:

- It protects the vital organs of thorax namely heart, lungs, major blood ves
- It provides support for the shoulder girdle and upper limbs.

Sternum or Breastbone

This is flat narrow bone located in the center of the chest. It is about 15 cm long

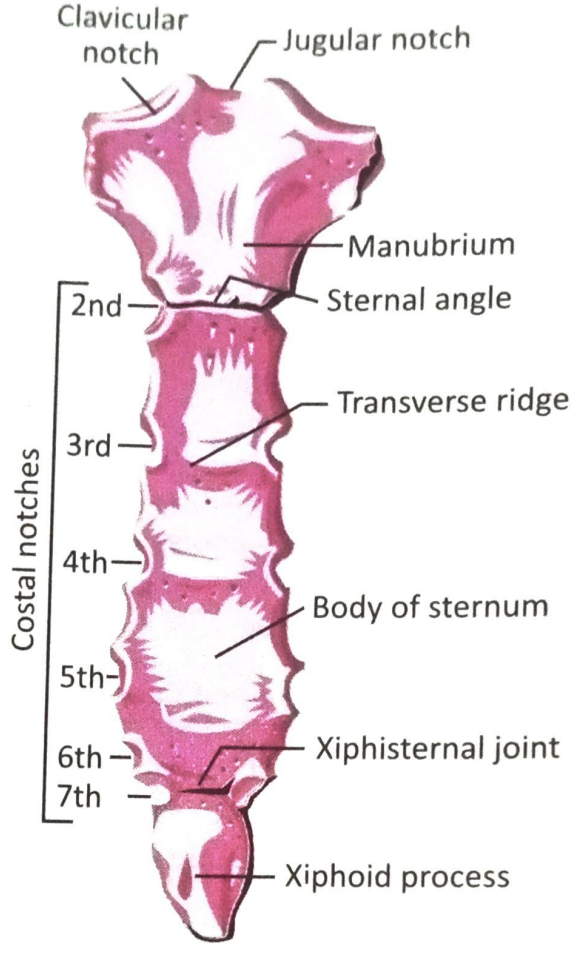

Fig. 4.16: *Sternum*

Sternum consists of three parts:

1. **Manubrium:** It is the upper part and has a depression on its superior side called suprasternal notch Lateral to suprasternal notch there are notches for articulation with clavicles to form sternoclavicular joint.
2. **Body:** It is the middle and largest part. It has facets on its lateral borders for the attachment of ribs.
3. **The Xiphoid Process:** It the tip (last) of the bone. It has surface for attachment of diaphragm and abdominal muscles.

RIBS

Ribs are 12 pairs of curved bones located in the either lateral sides of thoracic wall. The first seven pairs of ribs are described as true ribs as they anteriorly attached to the sternum by coastal cartilage. The 8th, 9th, 10th ribs are termed as false ribs because these are attached coastal cartilage of the above ribs so that they are indirectly attached to sternum. Last two pairs that is 11th and 12th ribs are referred as floating ribs as they have no anterior attachment. All 12 pairs of ribs articulate with thoracic vertebrae posteriorly.

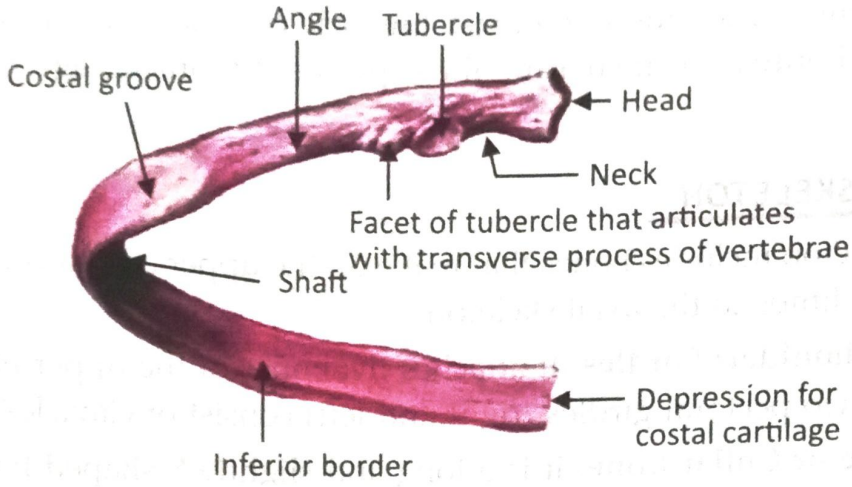

Fig. 4.17: *The Rib*

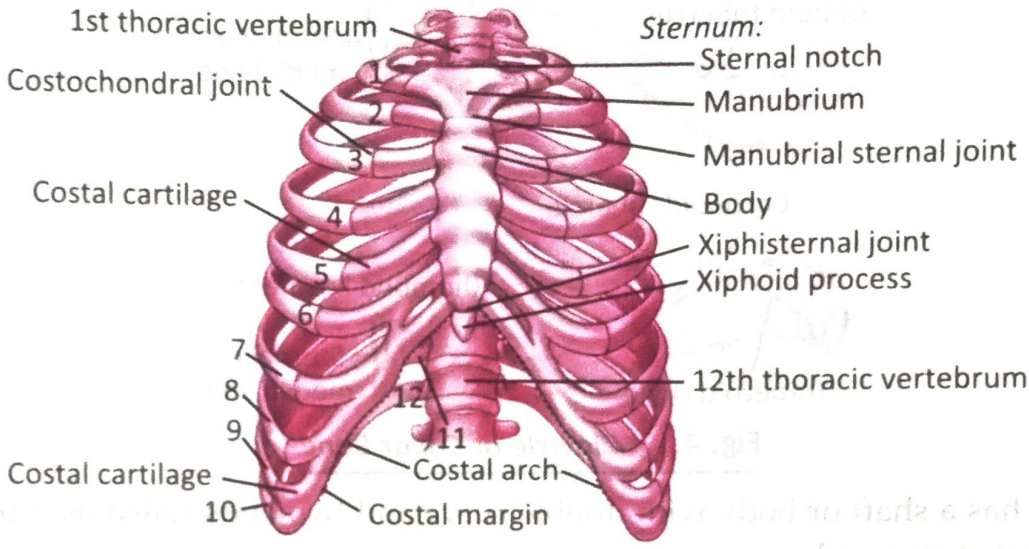

Fig. 4.18: *Rib Cage (Thoracic Cavity)*

Characteristics of a Rib

It is flat curve bone. It has head, neck, tubercle, angle, costal groove.

- **Head:** It is the projection at the posterior end of the rib and articulates with the facets of the bodies of adjacent thoracic vertebrae.

- **Neck:** It is a constricted portion just lateral to the head.
- **Tubercle:** It is the posterior surface to the neck and articulates with the transverse process of thoracic vertebra.
- **Angle:** It is the point at which the bone bends.
- **Costal groove:** It at inner surface of the rib that protects blood vessels and a small nerve.

The spaces between ribs are occupied by intercostals muscles.

During inspiration when these intercostal muscle contracts the ribs and sternum are lifted upwards and outwards, increasing the capacity of thoracic cage.

APPENDICULAR SKELETON

Appendicular skeleton includes bones that make up the upper and lower limbs as well as girdles that attach limbs to the axial skeleton.

A. **Pectoral (shoulder) Girdles:** It attaches the bones of the upper limbs to the axial skeleton. Two pectoral girdles (right and left) consist of clavicle-2 Scapula-2.

1. **Clavicle or Collar Bone:** it is a long and slightly S shaped bone. It is located across upper thorax region connecting shoulder to the sternum.

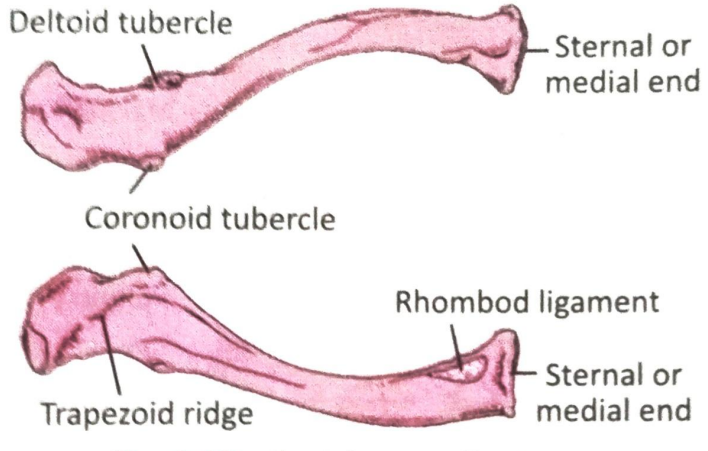

Fig. 4.19: ***Clavicle or Collar Bone***

It has a shaft or body with double curve and two ends called as acromial end and sterna end.

The acromial end is flat and forms acromial joint with the acromian process of scapula.

The sternal end is quadrangular articulates with the manubrium of the sternum at clavicular notch.

2. **Scapula or Shoulder Blade:** It is a large, triangular, flat bone situated in the superior part of the posterior thorax. Scapula has 3 borders, three angles, three fossa.

Three borders are:

(a) **Superior border:** It is the superior edge of the scapula. Superior border projects a anterior surface called coracoid process to which tendons of muscles attach.

(b) **Medial (vertebral) border:** It is the thin edge near the vertebral column.

(c) **Lateral (axillary) border:** It is the thick edge close to the arm.

Three angles are:

(a) **Superior angle:** It is the point at which the superior and the medial border of the scapula meet superiorly.

(b) **Inferior angle:** It is the point at which the superior and medial border of the scapula meet inferiorly.

(c) **Lateral angle or glenoid cavity:** It articulates with head of the humerus and forms shoulder joint and forms ball socket type of joint.

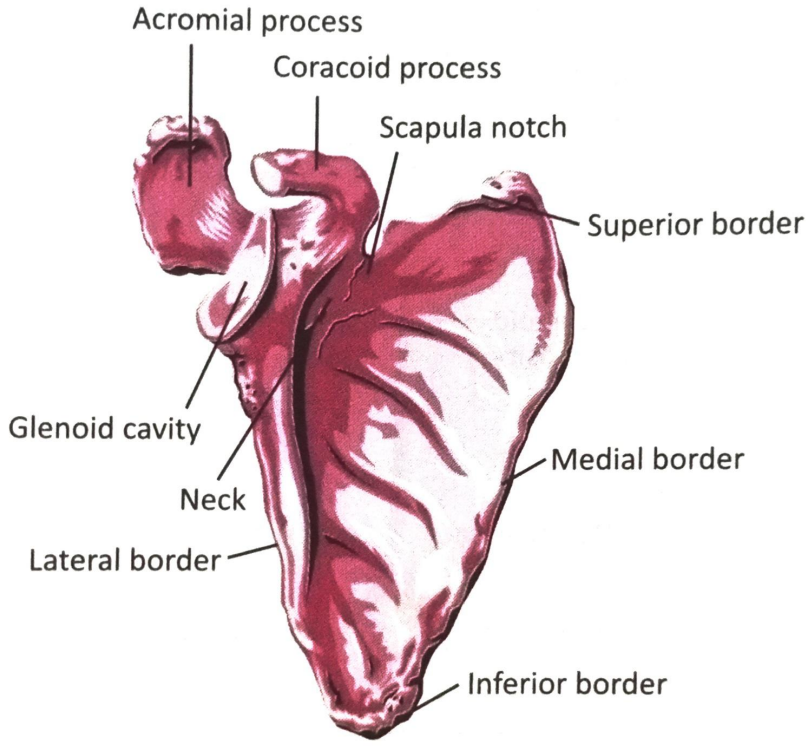

Fig. 4.20: ***Scapula Bone***

The body of scapula is flattened and triangular have following parts:

(a) **Spine:** A sharp ridge runs diagonally across the posterior surface of the body. Spine projects as a flattened, expanded process called acromian process which articulates with the clavicle.

(b) Upper and lower side of the spine are two fossa, the supraspinous fossa and infraspinous fossa. Both these serves as surfaces for attachment of tendons of muscles.

Anterior surface is a slightly hollowed out area called the subscapular fossa also surface of attachment for tendons of shoulder muscles.

B. **Upper or lower limbs:** Each upper limb has 30 bones in three locations.

1. 1 Humerus in the arm
2. 1 ulna, 1 radius in the forearm
3. 8 carpals in the wrist, 5 metacarpals (palm) and 14 phalanges in hand

HUMERUS

It is the longest and largest bone of upper extremity. It consists of three parts:

1. Proximal end
2. The body shaft
3. Distal end.

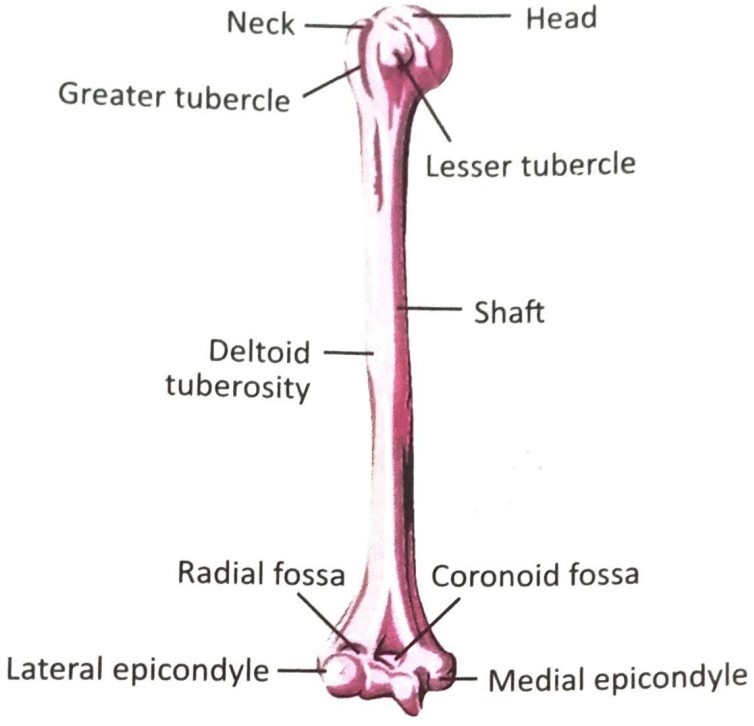

Fig. 4.21: *Humerus*

1. **Proximal end** consists of head, neck, greater tubercle, lesser tubercles.
   - **Head:** rounded end articulates with the glenoid cavity of scapula forms ball and socket joint (shoulder joint).
   - **Neck** is constricted part distal to the head.
   - **Greater Tubercle:** It is the lateral projection distal to the neck.
   - **Lesser Tubercle:** It projects anteriorly. Between these two tubercles, there is a groove called intertubercular groove which give attachment to muscles and ligaments.

2. The body (Shaft) of the humerus is cylindrical at its proximal end. Laterally, at the middle portion of the shaft, there is ridge called deltoid tuberosity for deltoid muscle attachment.
3. At the distal end humerus shows a rounded capitulum and a pulley like structure called trochlea.

   Capitulum articulates with the head of the radius and trochlea articulates with trochlear notch of ulna.

   The distal end shows lateral and medial epicondyle for muscle attachment.

RADIUS AND ULNA

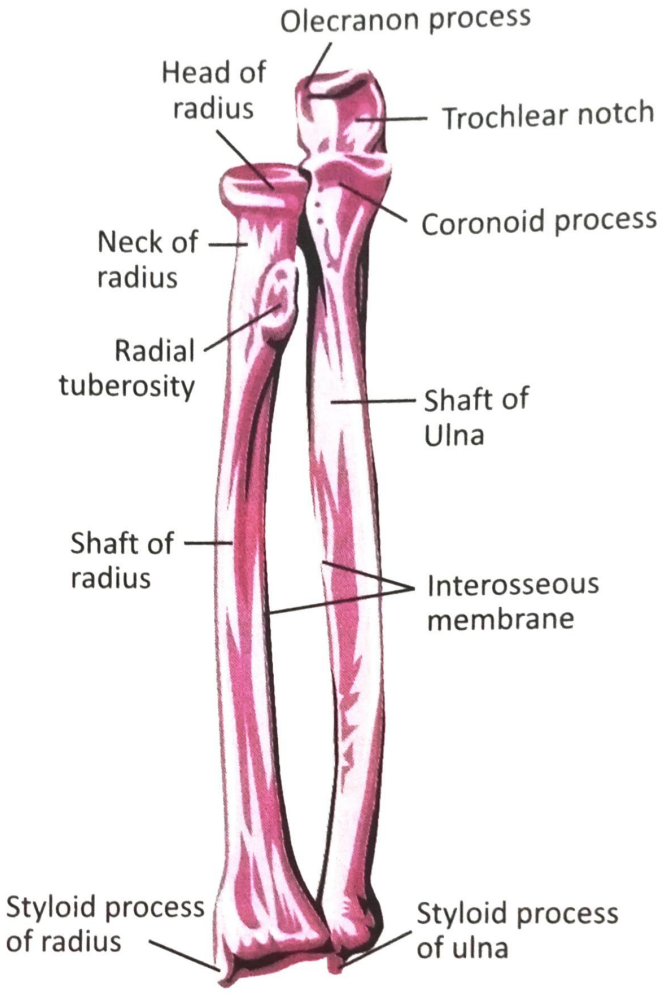

Fig. 4.22: *Radius and Ulna*

1. Radius is at lateral aspect (thumb side) of the forearm.
2. Radius is shorter than ulna.
3. It has proximalend end, shaft, distal end. The Proximal end includes head, neck and tuberosity.

Head is a rounded part which articulates with capitulum of humerus forming elbow joint.

The neck is the constricted part just below the head.

Tuberosity is the portion or projection below the medial side of the neck. It gives attachment to muscles and ligaments.

The shaft (body) of the radius is triangular area for attachment of muscles and ligaments.

4. The distal end is slightly wide and it articulates with proximal row of carpals. (wrist bones).
5. The shaft expand distally to form styloid processes for attachment of ligaments and muscles.

ULNA

1. Ulna is at on the medial aspect (the little finger side) of the fore arm.
2. Ulna is longer than radius.
3. It has Proximal end, shaft, distal end. The proximal end is thick and look like a hook with concavity forward. At the proximal end ulna have olecranon and coronoid process, both receives the trochlea of humerus. The trochlear notch is a large curved area between olecranon and coronoid process form elbow joint.

The shaft (body) is triangular area for attachment of muscles and ligaments.

The distal end of the ulna consists of head that is separated from the wrist by a fibro cartilage disc.

The styloid processes is present at distal end for attachment of ligaments and muscles.

BONES OF HAND, WRIST AND FINGERS

Carpals-16 (Wrist) Metacarpals-10 (Palm) Phalanges-28 (digits bones or finger bones)

The carpus region is the proximal part of the hand and includes 8 carpal bones joined each other by ligaments. These carpals are arranged in two rows. and their name reflect their shapes

Proximal row – Scaphoid (boatlike), lunate (moon like), triquetrum (three-corned), pisiform (pea shaped)

Distal row-trapezium, trapezoid (four sides), Capitate (head shaped), hamate (hooked)

Proximal carpal forms joint with radius (wrist joint) and ulna where as distal row carpals forms joint with metacarpals.

Metacarpals: These are total elongated 10 bones (5 bones in each palm) located at the palm region of the hands. Metacarpals are numbered I to V (or 1-5) starting with thumb. Their proximal end articulates with distal rows of carpal bones and distal end articulates with phalanges.

Phalanges (28 digits bones or finger bones): These are 14 phalanges in each hand arranged so that three in each finger and two in the thumb single bone of a finger calles as a phalanx. They are named as thumb index finger, middle finger, ring finger and little finger. Each phalanx consists of a proximal base, an intermediate shaft and distal head. Proximal phalanges (first row) articulates with metacarpals. Joints between phalanges (first, second, third rows) are called interphalangeal joints

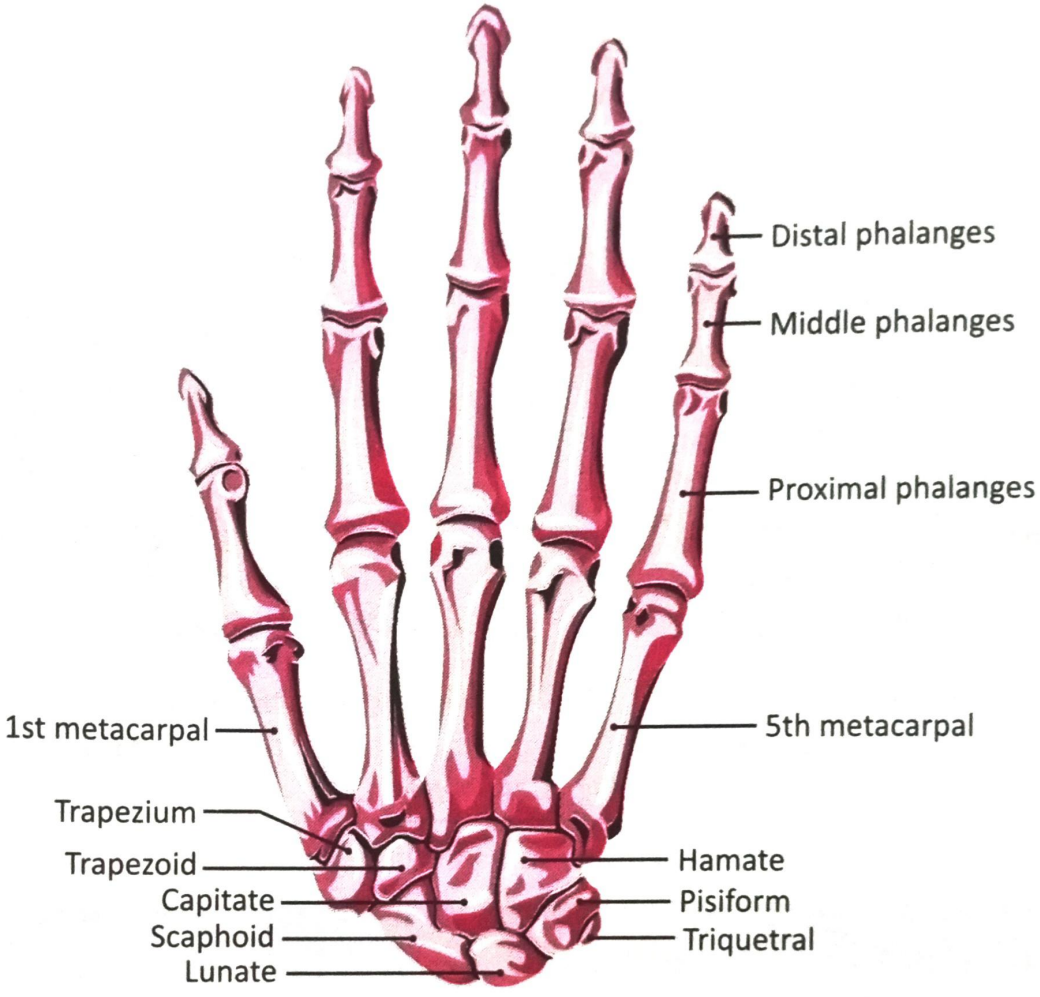

Fig. 4.23: ***Bones of Hand, Wrist and Fingers***

PELVIC (HIP) GIRDLE

The pelvic (hip) girdle consists of the two hip bones, also called coxal bones. The 2 hip bones unite anteriorly (front side) at a joint called pubic symphysis and posteriorly with the sacrum at the sacroiliac joints. The complete ring consist of 2 hip bones, pubic

symphysis and sacrum, coccyx forms a deep, basin like structure. This basin like structure is called as bony pelvis.

Each hip bone consists of 3 fused bones: illum, ischium, ischium.

1. **A superior illum:** It is the largest flattened plate form the acetabulum which acts as a socket or cavity for the head of the femur). Its upper border called iliac crest. Along the inner margin, ilium articulates with sacrum by sacroiliac joints.
2. **Interior posterior ischium:** It is the part below and behind the acetabulum with obuturator foramen. This is the largest foramen in skeleton from which blood vessels and nerves passes.
3. **Interior and anterior pubis:** It is the part in front and below theacetabulum with obuturator foramen.

All these 3 bones are fused together to form one large irregular bone. It has a cup shaped cavity called acetabulum. The head of femur articulates with acetabulum cavity forms hip joint.

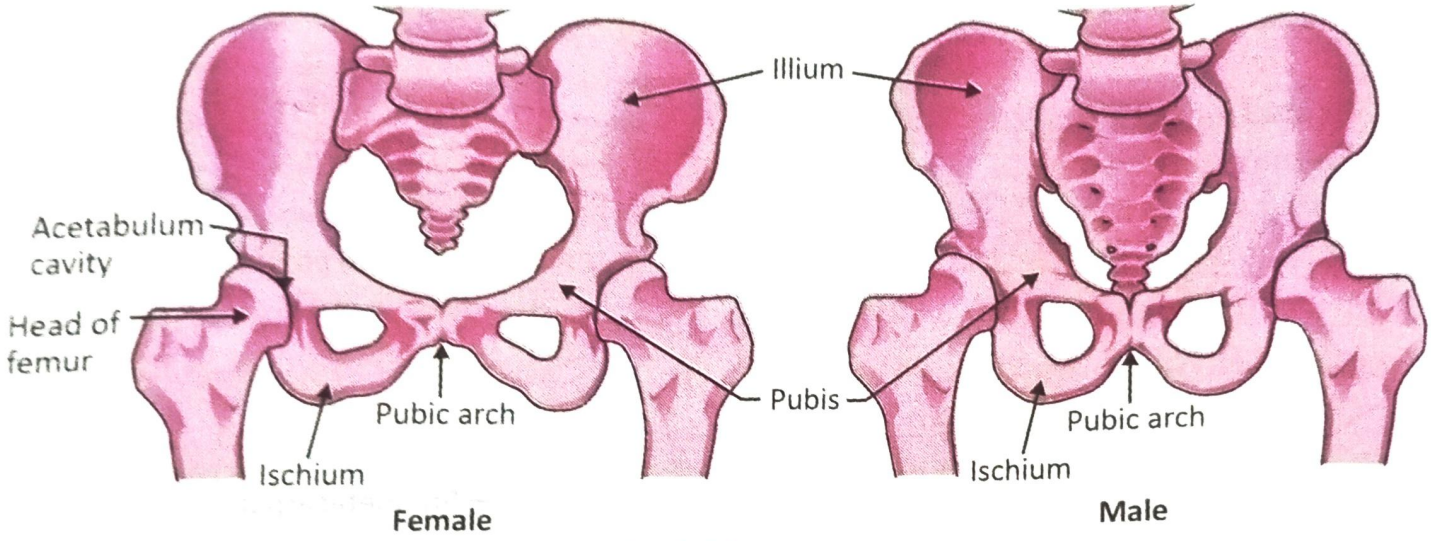

Fig. 4.24: *Pelvis*

Table 4.1: Difference or comparson between Female and Male Pelvis

	Female Pelvis	Male Pelvis
1. Bones	Lighter and smaller	Heavier and longer
2. Pelvic cavity	Larger and round	Smaller and heart or funnel shaped
3. Sacrum	Shorter, wider and more curved anteriorly	Longer, narrower and less curved anteriorly.
4. Coccyx	More movable and more curved anteriorly	Less movable and less curved anteriorly
5. Pubic arch	Wider or greater than 90° angle	Narrower or less than 90° angle

Function of Pelvic Girdle

1. It provides a strong and stable support for the vertebral column and pelvic organs.
2. It also accepts the bones of the lower limbs, connecting them to the axial skeleton.

Table 4.2: Difference or comparison between Pectoral girdle and Pelvic girdle

Pectoral Girdle	Pelvic Girdle
1. Pectoral girdle does not articulate with the vertebral column	Pelvic girdle directly articulates with vertebral column via sacroiliac joint.
2. The sockets for the upper limbs are shallow and allow more movement.	The sockets for the lower limbs are deep and allow less movement.
3. It offers more mobility and less strength.	It offers less mobility and more strength

LOWER LIMB

Each lower limb has 30 bones in four locations-femur in thigh, patella (kneecap), tibia and fibula in the leg, 7 tarsals in the tarsus (ankle), 5 metatarsals in the metatarsus and 14 phalanges (bones of the digits).

Femur or Thigh Bone

It is the longest, heaviest and strongest bone in the body. It has proximalend, intermediate shaft and distal end.

The proximal end shows a rounded head articulates with the acetabulum cavity of the hip bone form ball and socket type of joint. (Hip or coxal joint). Neck is the constricted region distal to the head. Below the neck, femur have projections called greater and lesser trochanters for muscle attachment.

A elongated cylindrical part of femur is called shaft. Along the shaft a longitudinal ridge is present called linea aspera for muscle attachment.

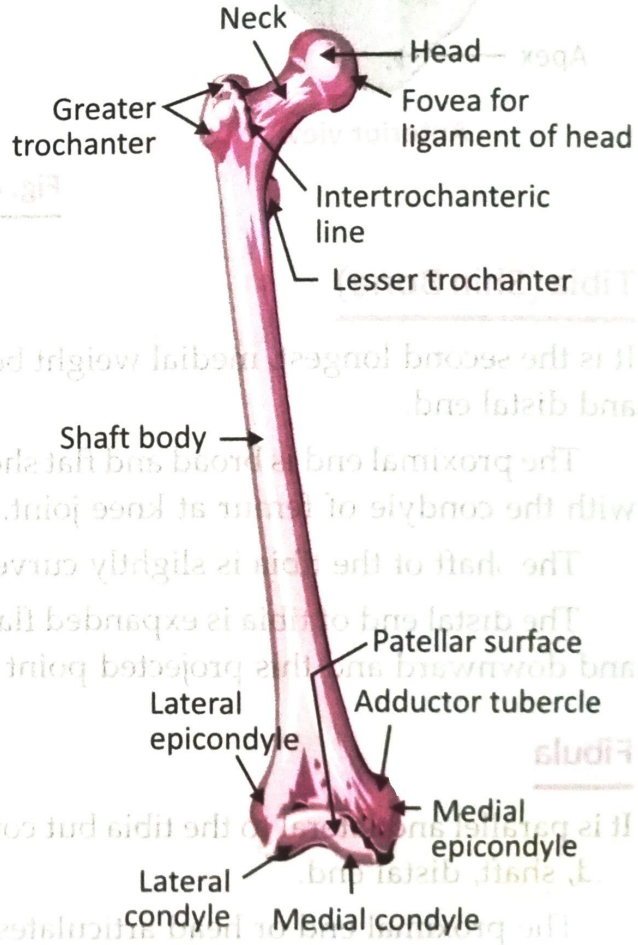

Fig. 4.25: *Femur Bone*

The distal end of femur is expanded that includes the medial condyle and lateral condyle. These condyles articulate with proximal end of tibia and take part in the knee joint. In between the two condyles, there is a depression called intercondyl fossa.

Patella (Little Dish) or Knee Cap

It is a small triangular bone located in the anterior region of knee joint. It attached to the tibia and femur by ligaments. Its superior broad region is called base where as the narrow region is apex. On the posterior surface, patella shows articular surface for articulation with distal end of the femur. Patella maintains positions of tendons and ligaments during movement.

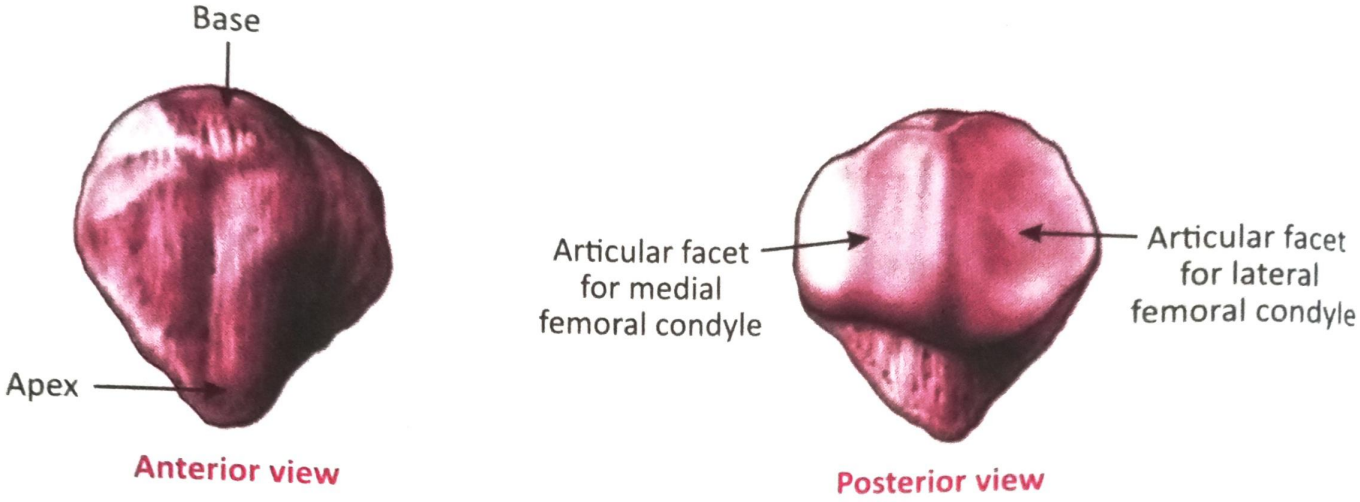

Fig. 4.26: *Patella*

Tibia (Shin Bone)

It is the second longest, medial weight bearing bone of the leg. It has proximal end, shaft and distal end.

The proximal end is broad and flat shows the presence of two condyles for articulation with the condyle of femur at knee joint.

The shaft of the tibia is slightly curved.

The distal end of tibia is expanded flat form ankle joint with talus. It projects medially and downward and this projected point is called medial malleolus.

Fibula

It is parallel and lateral to the tibia but considerably smaller than the tibia. It has proximal end, shaft, distal end.

The proximal end or head articulates with the lateral condyle of tibia.

The distal end has projection laterally called lateral malleolus form ankle joint with talus.

The shaft of the tibia is ridged for the attachment of muscles. Between the shaft of and fibula the interosseous membrane is present.

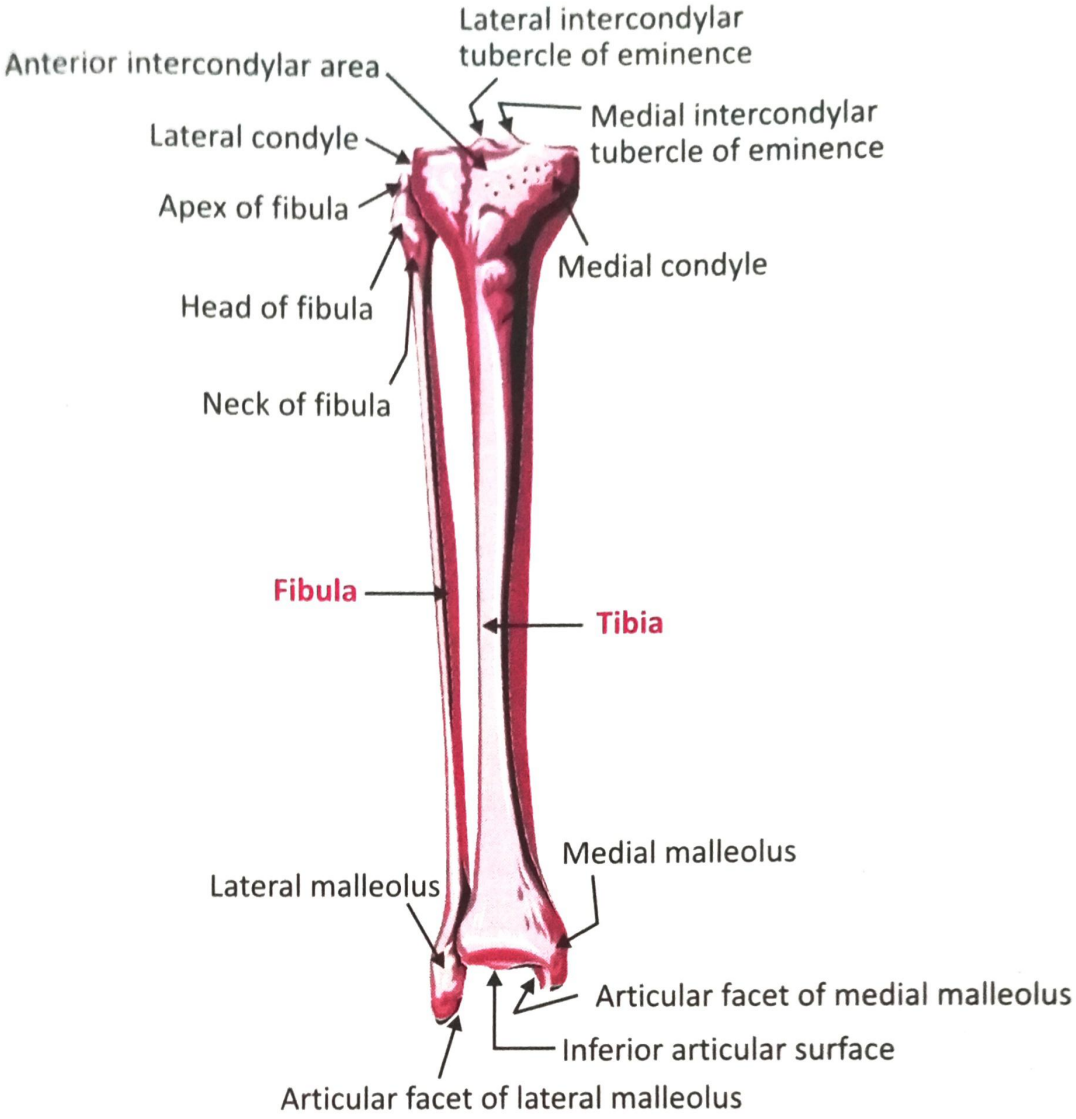

Fig. 4.27: *Tibia and Fibula Bone*

TARSALS, METATARSALS, PHALANGES

Tarsals

The tarsus (ankle) is the proximal region of the foot consists of 7 tarsal bones in each foot.

Talus (ankle bone), Calcaneus (heel bone) located in the posterior part of foot.

The anterior tarsal bones are cuboid (cube shaped), navicular (a little boat shaped), 3 cuneiform bones-first or medial, second or intermediate, third or lateral (wedge shaped) cuneiform bones These forms ankle joint with tibia and fibula.

Metatarsal

It is the intermediate region of the foot and consists of 5 metatarsal bones numbered I to V (or 1-5). Metatarsals proximally articulates with first, second and third cuneiform and cuboid bones. Distally they articulate with the phalanges.

Phalanges

They are 14 in number. They are arranged 3 in each of the toes and 2 on each great toe. Joints between the phalanges of the foot are called interphalanges joints.

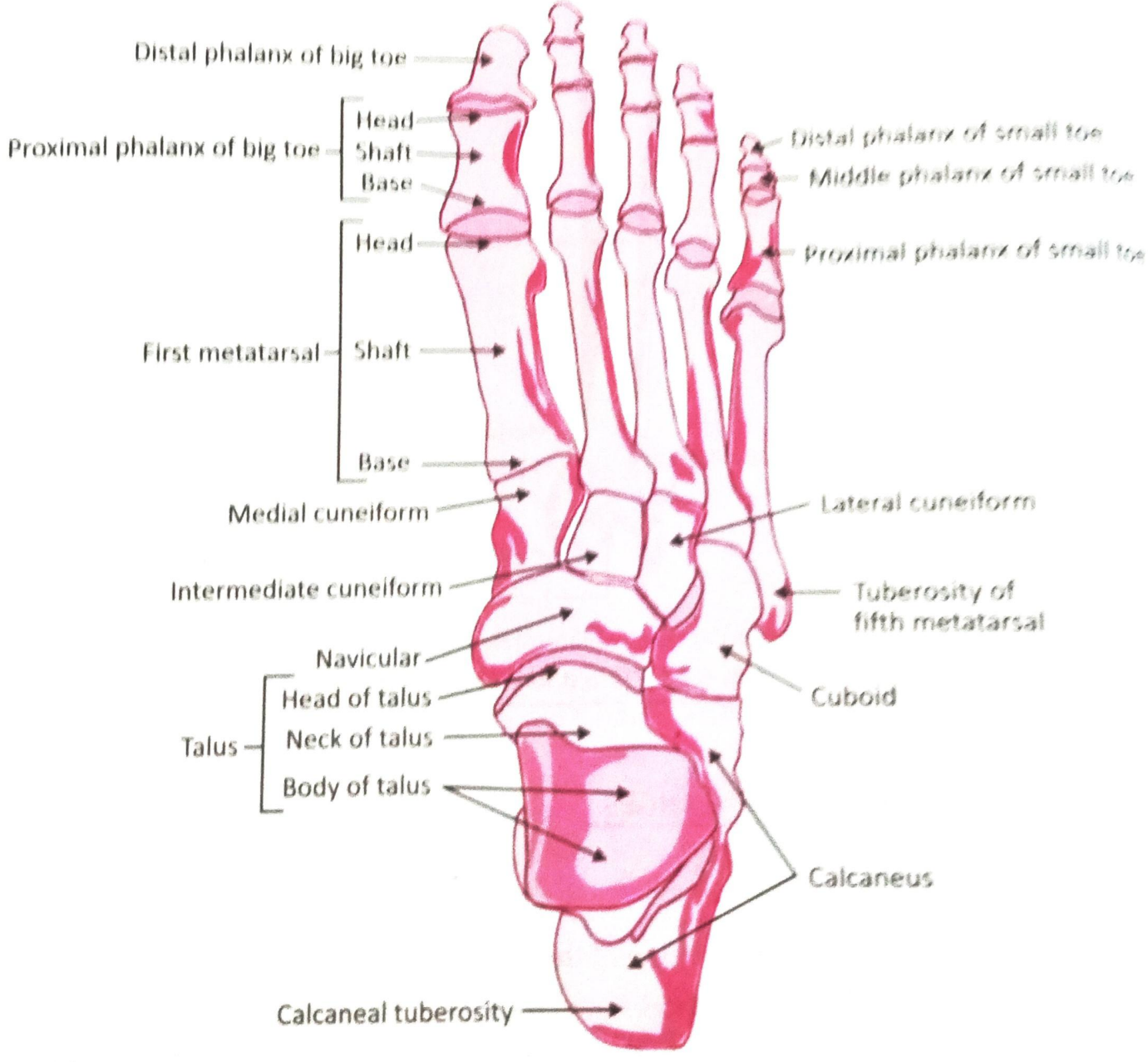

Fig. 4.28: *Foot Bones*

JOINTS

Joints means articulation of two or more bones.

Joint is a site where two or more bones come together.

FUNCTIONS OF JOINTS

- Joints causes various types of movements like flexion, extension, rotation, abduction etc.
- They also help in the locomotor activities.

CLASSIFICATION

Joints are classified according to their structure and movement:

1. Fibrous Joints or Fixed Joints or Immovable Joint
2. Cartilaginous Joints or Slightly Movable Joint
3. Synovial Joints or Freely Movable Joint

Table 4.3: Classification of Joints

Fibrous Joint or Immovable Joint	Cartilagenous Joints or Slightly Movable Joint	Synovial Joints or Freely Movable Joints
Here, fibrous tissue is present between two bones.	Here, pad of white fibro-cartilage is present between the ends of the bones.	It contains synovial cavity between two bones and outside synovial membrane.
There is no movement.	Slight movement is possible because compression of the pad of cartilage.	Free but limited movement is possible.
Examples: • Joints between the bones of the skull (Sutures). • Joints between the teeth and maxilla and mandible.	**Examples:** • Joints between the bodies of the vertebrae • Symphysis pubis (in Pelvic girdle).	**Examples:** • Hip joint • Hinge joint • Shoulder joint • Elbow joint

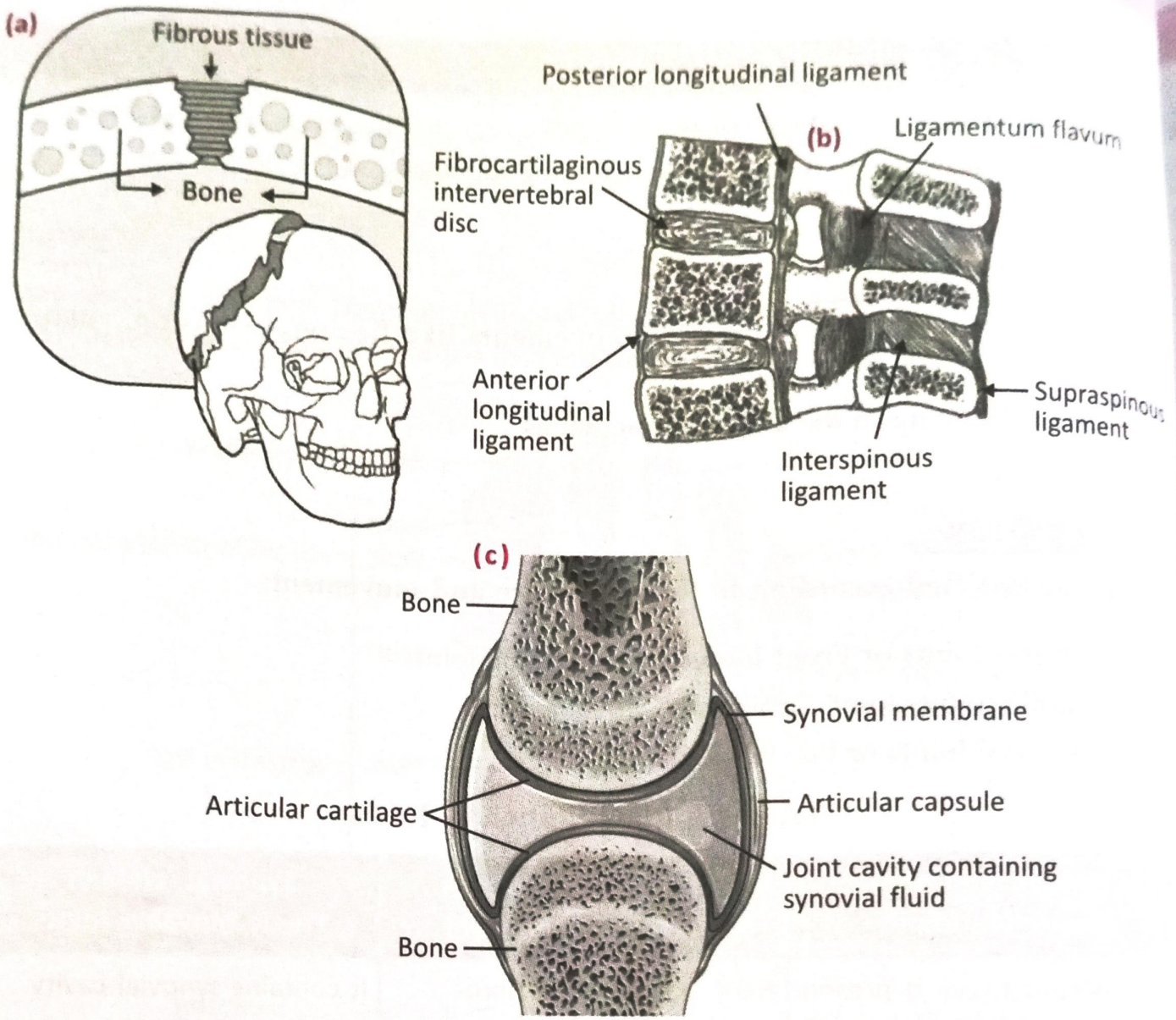

Fig. 4.29: ***Types of Joints according to their structures: (a) Fibrous Joint, (b) Cartilagenous Joint, (c) Synovial Joint***

SYNOVIAL JOINT

Synovial joint again classified into:

1. **Ball and Socket Joint:** Here, ball shaped head of one bone fits into a cup shaped cavity of another bone. It allows movement in all direction

   Hip joint: Head of Femur fits into acetabulum cavity of hip bone.

   Shoulder joint: Head Humerus fits into glenoide cavity of Scapula.

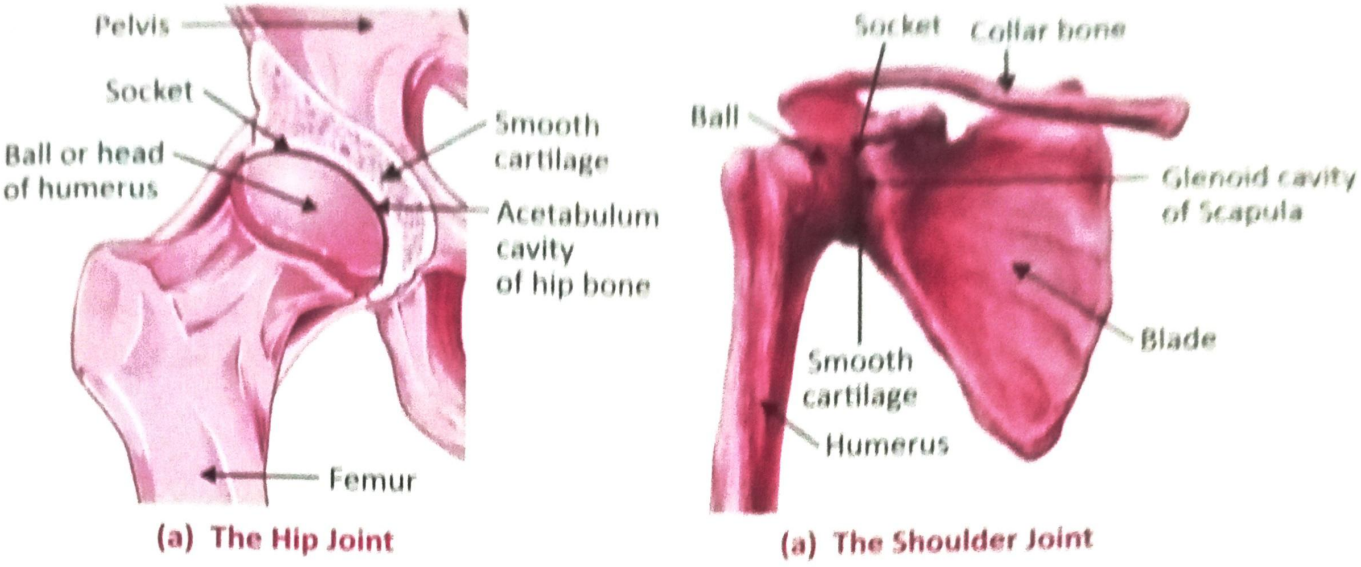

Fig. 4.30: *Ball and Socket Joint*

2. **Hing Joint:** Here, cylindrical surface of one bone fits into groove (depression) of another bone. This allows movement like a Hinge means movement in one direction or plane only.

   Elbow Joint: Cylindrical surface of Humerus fits into groove of ulna.

   Knee Joint: Cylindrical surface of Patella fits into groove of femur.

   Ankle Joint: Cylindrical surface of talus fits into groove of tibia and fibula.

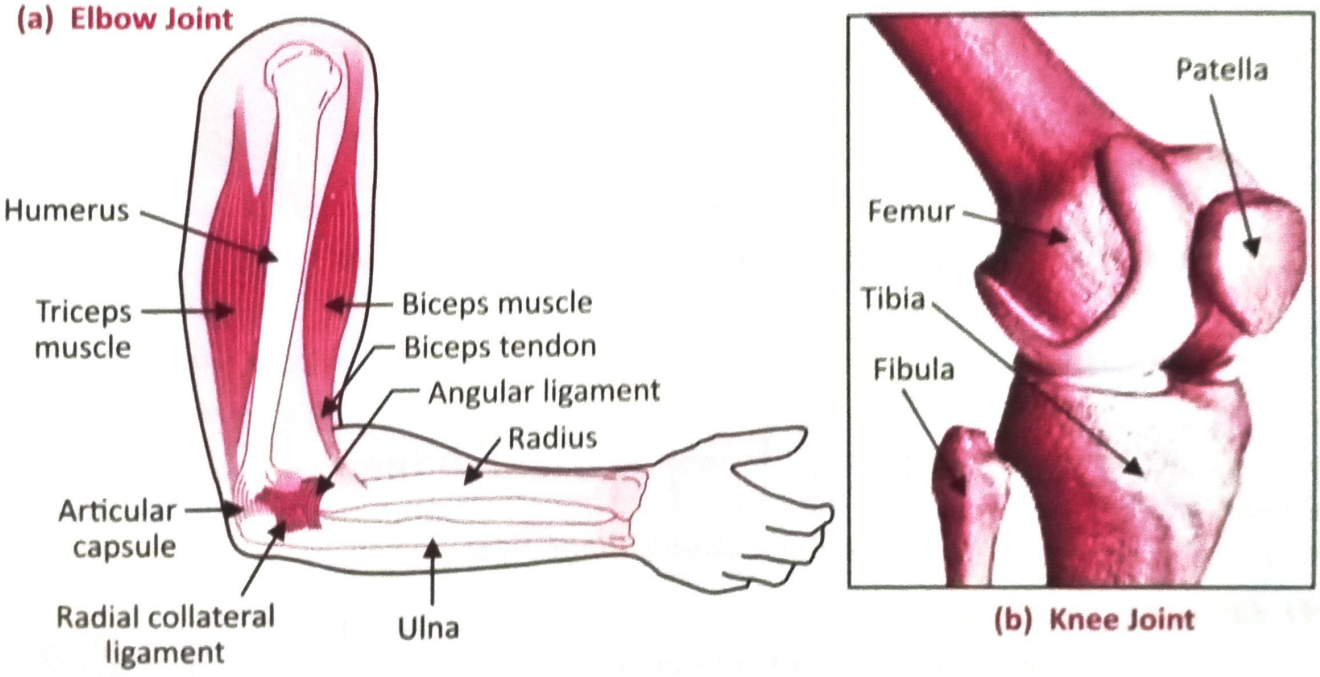

Fig. 4.31: *Hinge Joint*

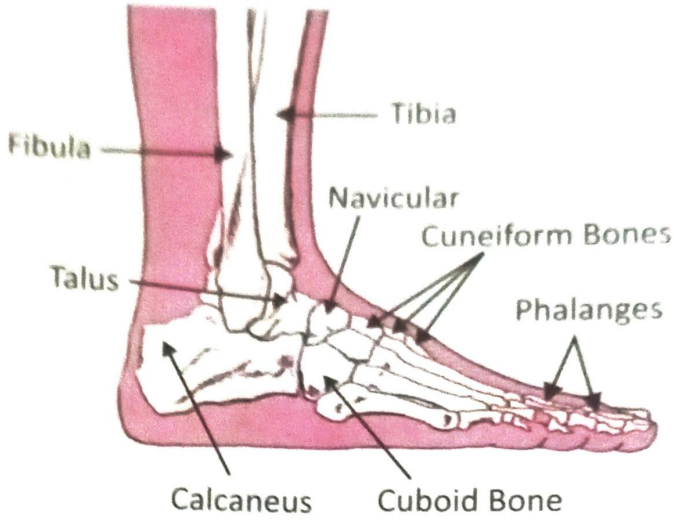

Fig. 4.32: *Ankle Joint*

3. **Double Hinge Joint or Ellipsoidal Joint or Condyloid Joint:** Here, oval ends of one bone fits into oval cup (elliptical cavity) of another bone. These allow movement in two directions.

   Example: Wrist joint (joint between carpals and radius ulna), Radiocarpal joint (joint between radius and carpals), Metacarpo-Phalangeal joint means joint between metacarpal and Phalanges.

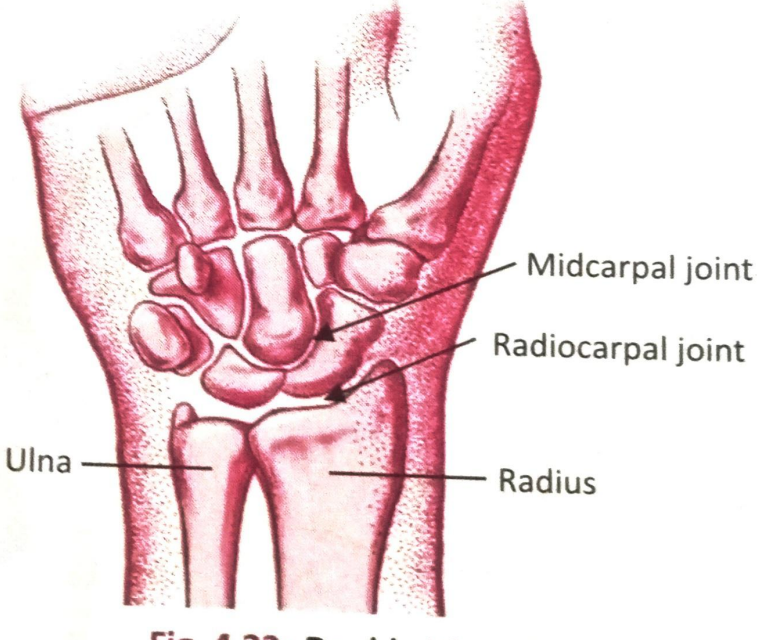

Fig. 4.33: *Double Hinge Joint*

4. **Gliding Joint:** It formed due to flat surfaces of bones. Due to flat surfaces bones glide on one another (move back and forth and side-to-side with respect to one another), e.g., Carpals joints of Hand, tarsals joint of feet.

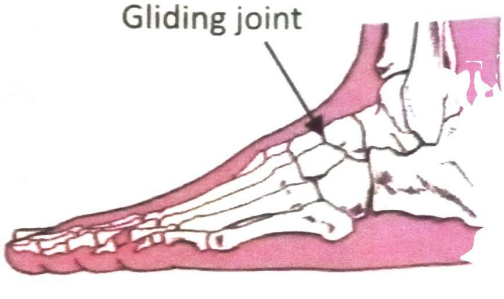

5. **Pivot Joint:** One bone rotates within another bone.

   Example: Joint between atlas and axis at neck allow head to turns either side.

6. **Saddle Joint:** Here one bone joins to another bone at its right angle. These bones can rotate a little and move sideways and back and forth, e.g., joints at the base of thumb.

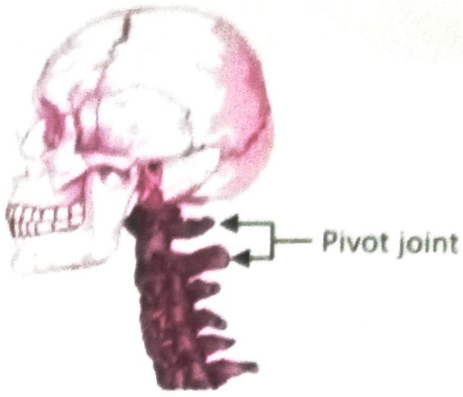

Fig. 4.34: *Pivot Joint*

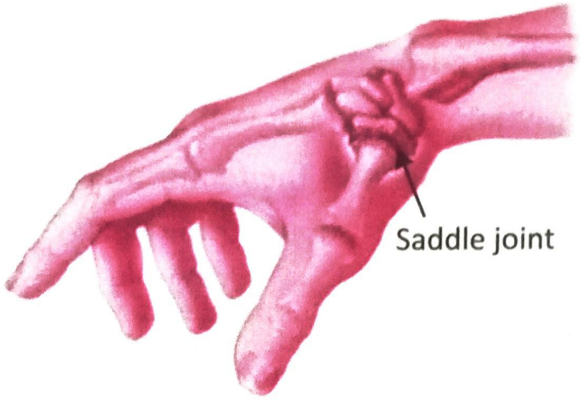

Fig. 4.35: *Saddle Joint*

JOINT DISORDERS

1. **Arthritis:** Inflammation (redness, swelling, pain) of joints.
2. **Gout:** It is the arthritis (Inflammation of joints) in which there is excess uric acid in blood.
3. **Osteoarthritis:** Inflammation of bones due to degeneration of articular cartilage. It is observed after age of 45 years.
4. **Rheumatoid Arthritis (RA):** It is autoimmune disorder in which the immune system of the body attacks on cartilage and joint lining. RA is characterized by inflammation of synovial joint which causes swelling, pain and loss of function.
5. **Gouty Arthritis:** Inflammation of joints due to deposition of uric acid crystals.

IMPORTANT QUESTIONS

1. Define:
   (a) Skeleton (S-97; W-96, 98, 00)
   (b) Bone (W-96)
   (c) Articulation (S-96; W-96)
2. Discuss the structure of Human skeleton. (S-96)
3. Give the functions of Skeleton. (W-96, 98; S-96, 97)
4. Give any four functions of Bones. (S-99)
5. Name the bones of Cranium. (W-02)
6. Name the bones in upper limb. (S-02)
7. Differentiate between male and female pelvic girdle. (S-96, 99; W-96, 98, 99, 0
8. Name the bones in elbow joint. (S-98, 00; W-98)
9. Name the bones which articulate with the femur and humerus. (W-99, 02)
10. Name the bones which take part in shoulder joints? (W-99, 02)
11. Classify joints with example of each class. (W-02)
12. Give classification of freely movable joints or synovial joints. (S-96; W-96, 01)
13. Give the diagram of typical synovial joint. (W-01)
14. Name the bones involved in knee joint. (W-01)
15. Name the bones involved in ankle joint. (W-00)
16. What are true and false ribs? (S-00)
17. What are sutures? Name the important sutures with their position. (S-00)
18. What are sinuses of Skull? Name two such sinuses write their function (S-03)
19. Describe the meaning of dislocation, arthritis and fracture (S-96; W-96)
20. Write down the functions of vertebral column. (W-96)

5

CHAPTER

Haemopoietic System

BLOOD

Blood is a fluid or liquid connective tissue.

Functions of Blood

A. **Transportations:**

1. Blood transports gases, i.e., oxygen from lungs to the tissues and carbon dioxide from tissues to lungs for exhalation
2. Blood transports or carries nutrients (carbohydrates, proteins, fats) from intestine (Gastrointestinal track) to body cells.
3. Blood transports hormones from endocrine glands to other body cells.
4. Blood transports heat throughout the body.
5. Blood transports waste products to the lungs, kidney and skin for elimination from the body.

B. **Regulations:**

1. Blood regulate pH.
2. Blood regulate body temperature and homeostasis in all body fluids.

C. **Protections:**

1. Blood (White Blood Cells and Antibodies) protect our the body against diseases (infections).
2. Blood (Platelets) protects our body against excessive blood loss by clot formation.

Physical Properties of Blood

1. Blood feels slightly sticky, denser and more viscus (thick consistency) than water.
2. Temperature of blood is 38°C (100.4°F).
3. Blood has slightly alkaline pH ranging from 7.35 to 7.45.
4. Blood volume is 5 to 6 litres in an average adult male and 4 to 5 liters in an average female.
5. The colour of the blood varies with its oxygen content. In arteries colour of blood is bright due to presence of oxygen and in veins is dark red or bluish because of lack of oxygen.

COMPOSITION OF BLOOD WITH THEIR FUNCTIONS

Composition of Blood

A. 55% Plasma

Dissolved substances + Water (90-92%)

1. **Plasma proteins**: Exerts osmotic pressure transport oxygen which helps to maintain water balance between blood and tissues.
   - Protect the body against diseases.
   - Regulate blood volume (Viscosity).
   - **Albumins:** As transport proteins for several Steroidal Hormones and for fatty acids
   - **Globulins:** Transport iron, lipids and fat soluble vitamins.
   - **Fibrinogen:** Blood clotting
2. **Nutrients:** Glucose, amino acids, vitamins, minerals. They provide energy, heat. They provide materials for repair and replacement (in wound). Nutrients are used for synthesis of other blood components and body secretions.
3. **Electrolytes:** Na^+, Ca^{++}, Mg^{++}
   - Maintain osmotic pressure and play essential roles in the functions of cells
4. **Gases:** O_2, CO_2, N
   - O_2 combine with hemoglobin inside RBCs
   - CO_2 dissolves in plasma.
   - Nitrogen has no physiological functions.
5. **Enzymes**: Enzymes produced by body cells.
   - Enzymes catalyze chemical reactions.

6. **Hormones:** Regulate growth and development metabolism of the body.
7. **Waste products,** e.g., urea, uric acid and creatinne. These are the waste products of protein metabolism.

B. 45% cells

1. Erythrocytes or Red Blood Cells (RBCs)
2. Leucocytes or White Blood Cells (WBCs)
3. Thrombocytes or platelets protect the body against excessive blood loss.

Plasma Versus Serum

Plasma is obtained by centrifugation of blood with addition of anticoagulants. Here, all blood cells are precipitate or separate all cells and clear supernatant liquid is called **Plasma.** Plasma without the clotting proteins (Fibrinogen) is called **Serum.** It is obtained by keeping withdrawn blood in test tube for 10 min. The blood will coagulate in test tube. The filtered portion of blood after coagulation is serum.

CLASSIFICATION OF BLOOD CELLS

Table 5.1: Classification of blood cells with their functions, normal count and life span

Cells	Normal count	Life span	Functions
Erthrocytes/Red blood cells Biconcave disc with diameter 7 μ meter without a nucleus buthave haemoglobin molecule	*Male:* 4.5-6.5 millions per cubic mm of blood *Female:* 3.5-5.5 millions per cubic mm of blood	100-120 days	Haemoglobin binds with O_2 RBCs transport O_2 to the body tissues.
Leukocytes/White blood cells Largest blood cells contain nuclei and with or without granules in their cytoplasm	6000-10,000 per cubic mm of blood	Few hours to a few days.	Body's Defense mechanism that is protects the body against infections by phagocytosis mechanism.
Thrombocytes/Platelets non-nucleated disc 2 to 4 μ meter. These are cell fragments. Contain many vesicles but no nucleus.	1.5-4 Lakh	8 to 11 days	Helps in haemostasis by forming blood clott. Thus platelets protect our body against excessive blood loss by clot formation.

FORMATION OF BLOOD CELLS

The process of Formation of blood cells is called **haemeopoises**.

Blood cells are made in the bone marrow, i.e., a spongy tissue located inside bones. It contains young parent cells called **stem cells**. These blood-forming stem cells grow into all three types of blood cells – red cells, white cells and platelets. When blood are fully mature and functional, they leave the bone marrow and enter the blood.

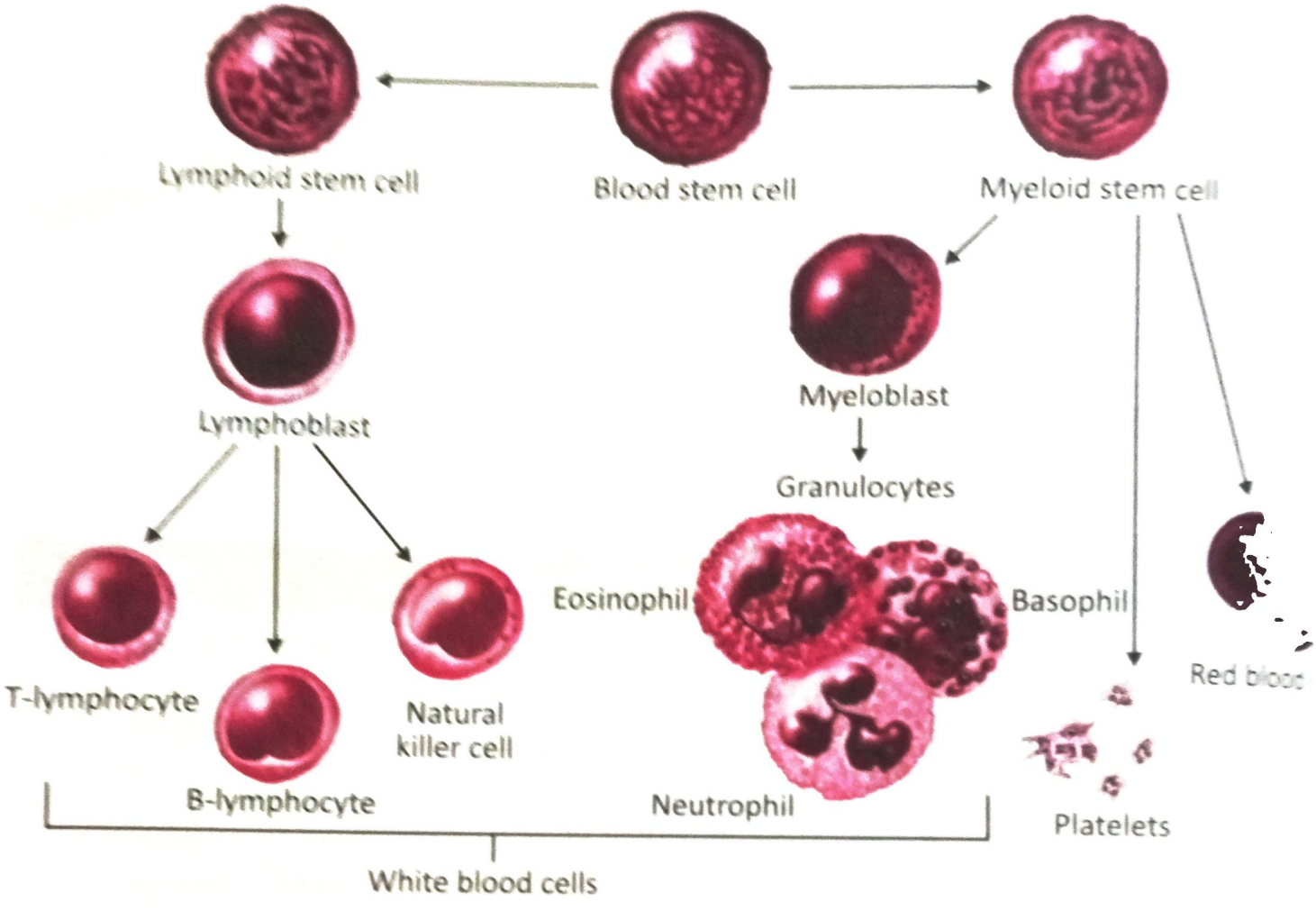

Fig. 5.1: *Blood Cells*

RED BLOOD CELLS OR ERYTHROCYTES (ERYTHRO-RED, CYTES-CELLS)

1. **Red Blood Cells** are produced in Liver in foetal life. After birth, they are produced in the red bone marrow, which is present in the end of the long bones. (Bone marrow is the vascularized connective tissue present within bones).
2. The process of formation of erythrocytes or RBCs in bone marrow is called erythropoiesis which takes place by following ways:
   (i) When there is less oxygen supply to the tissues, i.e., hypoxia.
   (ii) Then kidney produces hormone erythropoietin.
   (iii) Erythropoietin stimulate bone marrow for erythropoiesis synthesis of RBC.

Tissue hypoxia, i.e., decreases oxygen carrying capacity of blood

↓

Kidney secrete erythropoietin in blood

↓

Stimulate bone marrow for erythropoiesis

↓

Bone marrow increases erythropoiesis

↓

Red Blood cells increases.

↓

Rises oxygen carrying capacity of blood.

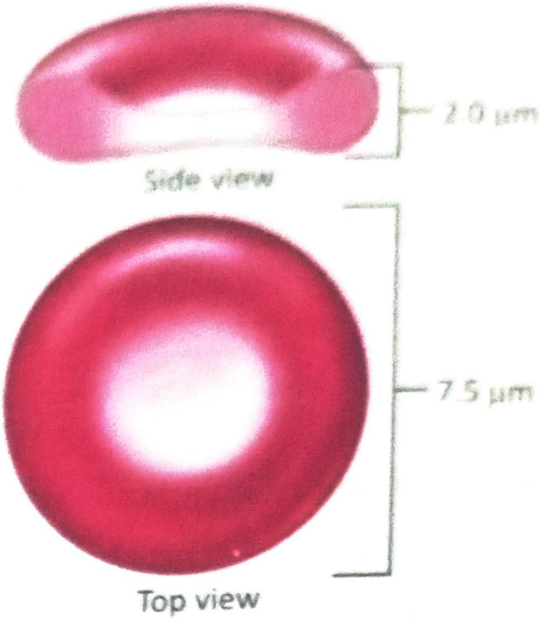

Fig. 5.2: *Red Blood Cell*

3. Erythrocytes develop from pluripotent stem cells within 7 days. The immature cells are releases into the blood stream as reticulocytes an then mature into erythrocytes. During this time, they lose nucleus and not divide. This stages of development of blood cells are called Haemopoiesis.

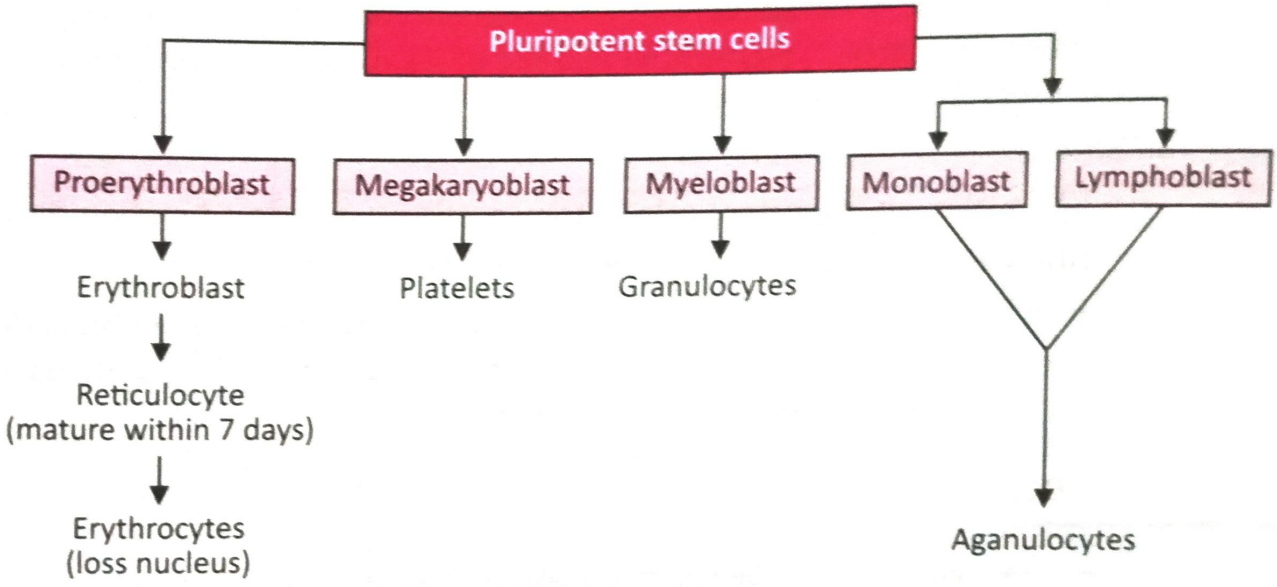

4. **Factors are required for red blood synthesis:** Both Vitamin B_{12} and folic acid are required for red blood cell synthesis. They are absorbed in the intestines, Vitamin B_{12} must bebound to intrinsic factor of stomach to allow absorption to take place.

5. **Functions of RBCs:** RBCs does not contain nucleus but they contains Haemoglobı molecules.

Haemoglobin	→	Haem	+	globin
(Hb) (Iron material)		(protein part)		

(a) **Haemoglobin binds with oxygen and form oxyhemoglobin** In oxyhemoglobin goes to the tissues and breakdown into oxygen and Hemoglobin. Oxygen used by tissues.

In tissues, hemoglobin binds with carbon dioxide to form carboxyhemoglobin and then goes to the lungs for excretion.

Haemoglobin + Oxygen ↔ Oxyhemoglobin (goes to tissues)

↓

Oxygen (Used by tissue)

↓

Haemoglobin binds with Cabon Dioxide to form Carboxyhaemoglobin.

↓

Carboxyhaemoglobin goes to lungs for excretion

As the oxygen content of blood increases, its colour becomes red.

If the oxygen content of blood is low, its colour becomes dark bluish.

(b) **Haemoglobin bind with gaseous hormone nitric oxide** (NO), produced by the endothelial cells of blood vessels. Under some circumstances, Haemoglobin releases NO. The released NO causes vasodilation (an increase in blood vessel diameter), so increases blood flow and increases oxygen delivery to cells and blood pressure becomes low.

In short,

(i) RBCs play an important role in transporting oxygen and carbon dioxide.

(ii) RBCs also regulate the blood flow and blood pressure.

6. **Destruction of RBCs**: The life span of RBCs is about 120 days and their breakdown process is called haemolysis. Haemolysis is carried out by reticuloendothelial cells present in the spleen, bone marrow and liver.

Hemolysis of RBCs

RBCs ⟶ Hem + Globin (transported to the liver and break down into amino acids to synthesize other proteins)

RBCs ⟶ Hem ⟶ Iron portion reused in bone marrow to form new Hb molecule form

RBCs ⟶ Hem ⟶ Non-iron portion of Hem is convert into biliverdin (green pigment) and into bilirubin (yellow pigment)

BLOOD GROUPS

1. Based on these antigens, blood is categorized into different Blood groups A, B, AB, O.
2. In addition to antigens, blood plasma contain different antibodies not same (not their own type). If antigen and antibody are same they react with each other and form transfusion reaction (haemolysis, release Hb into plasma). So Blood group A having anti-B antibodies.
3. Depending upon A, B antigens and Rhesus antigen Blood groups are classified into:

   (a) ABO system

   (b) Rhesus system

ABO System

Table 5.2: ABO System of Blood Group

Blood Group	Antigen	Antibodies	
A	A	Anti-B	
B	B	Anti-A	
AB	A and B	No antibodies	Universal recipient
O	No antigens	Anti-A, Anti-B	Universal donar

- Blood group AB is called universal recipient because person with blood group AB receive or take blood from all four blood groups. Blood group AB have no antibodies to attack antigens on donated (given) RBCs.
- Blood group O is called universal donor because person with blood group O, donate or given blood to all four blood groups. Blood group O have no antigens on their RBCs. So no formation of antibodies against antigens.

Rhesus System (Rh)

The Rh blood group is so named because the antigen is discovered in the blood of the Rhesus monkey.

People those RBCs have Rh antigen are called Rh+ (Rh positive)

People do not have Rh antigen on RBCs are called Rh– (Rh negative)

Table 5.3: Rhesus System of Blood Group

Blood group	Antigen	Antibodies
Rh+ve	Rh	No antibodies
Rh-ve	No antigen	Anti-Rh antibodies

If an Rh –ve person take an Rh +ve blood for the first time, immune system starts to make anti-Rh antibodies that will remain in blood.

If an Rh –ve person take an Rh +ve blood for the second time, formed anti-antibodies will cause haemolysis (rupture of RBCs and a severe reaction may occur).

Rhesus system has great significance in Pregancy or Haemolytic Disease of Newborn (HDN) or Erythroblastosis Fetalis.

Hemolytic Disease of the Newborn (HDN) or Erythroblastosis Fetalis

It is a haemolytic disease of fetus (baby in mother's womb) and newborn that occurs when the immune system of an Rh –ve mother produces antibodies to an antigen in the blood of an Rh +ve fetus. This antibodies cross the placenta and destroy the erythrocytes (RBCs) of fetus. That is cause erythroblastosis (breakdown of RBCs). Then baby is suffering from anemia and jaundice.

Rh –ve mother ⟶ Rh +ve Baby ⟶ No problem (first time)

Rh –ve mother ⟶ Rh +ve Baby ⟶ Problem (second time)

Anit-Rh antibodies + Rh antigen ⟶ Antibodies + antigen reactions and jaundice in baby. (HDN) ⟶ Haemolysis of Baby's RBCs

Treatment for HDN

An injection of anti-Rh antibodies (anti-Rhgammaglobulin) can be given to Rh-ve women soon after every delivery (within 72 hours) that is from first delivery.

These antibodies bind to foetal/baby antigen and inactivate it. Antigen does not enter in mother and does not form antibodies. So problem cannot create for second and third delivery. So no availability of antigen then mother could not recognize as foreign antigen does not produce antibodies.

DISORDERS OF RED BLOOD CELLS (ANEMIA & POLYCYTHEMIA)

Normal count of Red Blood Cells (RBCs):

- Male (4.5-6.5 million per cu. mm.)
- Female (3.5-5.5 million per cu. mm)

Anemia: RBCs count decreases.

Polycythemia: RBCs count increases

Anemia

Anemia is a condition in which:

1. Number of RBCs are reduced.
2. Amount of haemoglobin (Hb) in blood is reduced.
3. Oxygen carrying capacity of blood is reduced.

Signs and Symptoms of Anemia

- Person feels fatigued and is intolerance of cold because less oxygen, less ATP and less heat production.
- Skin becomes pale blue because less Hb.

Causes and Types of Anemia

- **Iron deficiency Anemia:** due to less iron, hypochromic (faint coloured) cell. Microcytic (small size) cell.
- **Pernicious Anemia:** It is a type of megaloblastic (large sized cells) anemia and is autoimmune as lack of intrinsic factor which results in deficiency of Vitamin B_{12}.
- **Megaloblastic Anemia:** It is a type of macrocytic anemia (big cell) due to deficiency of folic acid. Deficiency of Folic acid, Macrocytic (big) cell.
- **Hypoplastic and Aplastic Anemia:** Bone marrow failure. So less or no RBCs production.
- **Haemolytic Anemia:** Abnormal RBCs enzymes, RBCs get ruptured.
- **Thalassemia:** Less Hb synthesis.
- **Sickle cell anemia:** Abnormal kind of Hb, RBCs become sickle shaped.
- **Haemorrhagic Anemia:** RBCs loss due to bleeding.

Polycythemia

Polycythemia means abnormally large number of RBCs in the blood.

Increased number of RBCs increases the viscosity of the blood and increase Blood pressure, increases resistance to blood flow, make the blood flow more difficult for the heart to pump.

Name	Number	Characteristics	Function
Basophils	0.5-1% of all WBCs	1. Nucleus has 2 lobes. 2. Cytoplasm have blue granules as these take up basic dye, i.e., methylene blue.	Basophils liberate heparin, histamine and serotonin in allergic reactions that intensify (make strong). Inflammation (pain, redness and swelling). Basophils are also called as mast cells.

Agranulocytes

Agranulocytes divided into two types:

1. **Lymphocytes:** Divided into T-Lymphoctes (cell mediated immunity) and B-Lymphoctes-antibody mediated immunity.
2. **Monocytes:** Function is Phagocytosis.

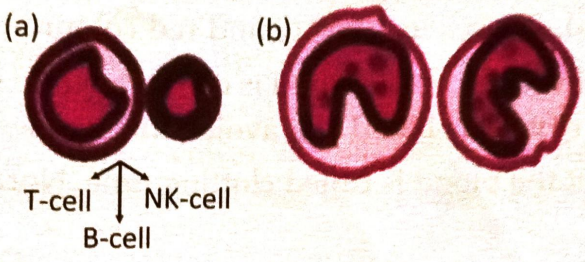

Fig. 5.4: ***Agranulocytes (a) Lymphocytes, (b) Monocytes***

LEUKOCYTES DISORDERS

Normal leukocyte count is 6000 to 10, 000 per cubic mm of blood

Table 5.5: Diseases of WBCs

Leukopenia	Leukocytosis	Leukaemia
Total WBCs count is less than normal, i.e., abnormally low below 4000 per cubic mm Causes: Radiations, shock and certain chemical agents used for diseases (chemo-therapy).	Total WBCs count is increase, i.e., above 10,000 per cubic mm in pathological conditions, i.e., infections. It is a normal protec-tive response to infections. When infection decreases, WBCs count returns to normal. Causes: Infections, strong exercise, ana-esthesia and surgery.	Abnormal or uncontrolle increase in the production o WBCs. It is an cancer of bon Marrow. It is an malignar Proliferation of WBC Causes: Ionising radiatior Chemicals, genetic factor

Platelets/Thrombocytes

1. These are very small, non nucleated.
2. Their diameter is 2 to 4 micrometer
3. They contain a variety of substances that promateclotting.
4. When platelet count is fall, then kidney release a substance called thrombopoietin which stimulate platelet synthesis.
5. Their life span is 8 to 11 days.
6. Platelets are destroyed by macrophages mainly in spleen.
7. Platelets play vital role in the haemostasis. Which takes place by 3 steps
   (a) Vascular spasm
   (b) Platelet plug formation
   (c) Blood clotting (Coagulation)

Haemostasis/Coagulation Process/Clotting Mechanism

1. When blood is shed, it loses its fluidity and red colour.

   Thus the fluide (solution) form of blood is converted into semisolid gel (soft mass) is known as blood clot. This blood clot avoids further loss of blood from the body

   Time require to clot the blood is called clotting time. Norma clotting time is 3 to 6 min.

   The process of forming blood clot is called clotting of blood or coagulation of blood.
2. When there is an injury to a blood vessel, there is a vascular spasm or vasoconstriction and formation of rough surface. The platelets come in contact with this rough surface (near the injury).
3. These platelets release Adenosine Diphosphate (ADP), which attract more platelets to the rough surface and form plug. This is called as 'Platelet plug formation'.
4. After Platelet plug formation, actual clotting mechanism starts. Platelets and injured tissue release thromboplastin. This thromboplastin is also called tissue factor.
4. Blood contains calcium and prothrombin (plasma protein present in liver). In the presence of thromboplastin and calcium, prothrombin is converted into thrombin
5. Thrombin in presence of calcium converted into fibrinogen (another plasma protein formed in liver).

   Fibrinogen is converted into fibrin. This fibrin is insoluble thread.

Threads of fibrin form a net. In this net, blood cells are trapped. This mass then contract to form a blood clot.

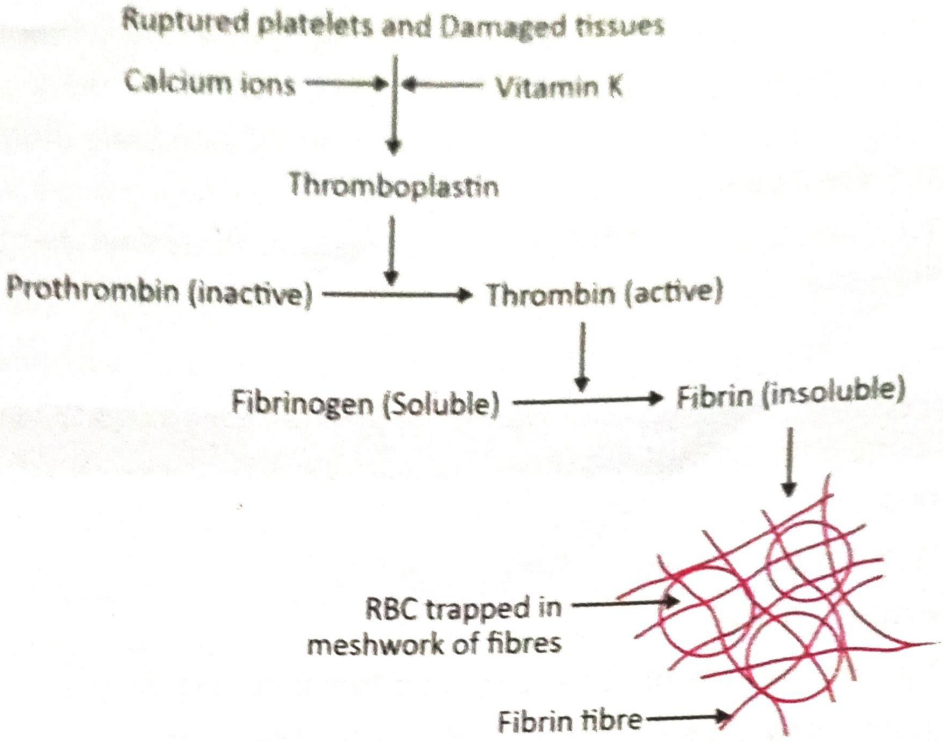

Fig. 5.5: *Clotting Mechanism*

Factors hastens or accelerating clotting are:

1. Injury to the walls of blood vessels.
2. Contact with rough surface-cotton and surgical dressings like substances are kept on wound for clotting the blood and to prevent bleeding.
3. Snake venom
4. Higher temperature
5. Presence of calcium salts
6. Resting condition

Factors retarding clotting are:

1. Contact with smooth surface
2. Calcium deficiency in blood
3. Vitamin K deficiency
4. Lower temperature – it causes contraction of blood vessels
5. In clinical conditions like hemophilia, pneumonia.

PLATELETS DISORDERS

1. **Thrombocytopenia:** It is the condition in which platelet count is below 1.5 la per cubic mm, i.e., very low platelet count that results in a tendency to bleed.

   Causes or reasons for thrombocytopenia:

   (a) Reduced rate of platelet production

   (b) Increased rate of platelet destruction

2. **Haemophilia:** It is characterized by a prolonged bleeding following a cut is occur due to hereditary factors.
3. **Thrombosis (large blood clot):** Large Firm mass of blood clot in the blood vessel is called thrombosis.
4. **Embolism (small piece of blood clot):** A piece of thrombus that travel through the blood vessel is called emobolus or embolism.

IMPORTANT QUESTIONS

1. Define blood (S-00)
2. Describe composition of blood (S-96, 99; W-98)
3. What is serum? (W-99)
4. Give the plasma proteins of blood and their functions. (W-96, 01)
5. Write functions and classification of WBC. (S-97; W-96, 99, 02)
6. Define thrombocytopenia. (W-99)
7. What is pH of blood? How much of blood is present in normal adult person? (W-00)
8. Give the functions of blood. (S-96)
9. Give different disorders of leukocytes. (S-03; W-01)
10. Explain:
    (a) Leukopenia (S-96, 00)
    (b) Leukocytosis (S-02)
    (c) Leukemia (S-97, 98, 02, 03; W-99, 00)
    (d) Haemophilia (W-00)
11. What are erythrocytes or red blood cells? Give their functions.
12. Give the different stages in the development of of erythrocytes or RBCs. (W-01)
13. Explain the role of Haemoglobin in the process of respiration. (S-97, 03; W-97)
14. Describe HDN or erythroblastis foetalis. (S-98)
15. Define cyanosis. (W-02)
16. What is Anemia? Give its types. (S-96, 98, 01, 02; W-02)
17. What is Pernicious Anemia? (S-01)
18. How blood groups are classified? (S-97; W-96, 00, 02)
19. What is Rh factor? (S-99, 01; W-98, 02)
20. Give the importance of Rh factor. (S-99, 01; W-98, 02)

21. Define coagulation or clotting of blood. (S-02; W-02)

    How clot is formed? Write in brief the process of coagulation of blood. (S-97, 98, 03; W-96, 97, 98, 00)

22. Name the factors which hinders and hastens coagulation of blood. (W-98, 01)
23. Decribe the term thrombosis and embolism. (S-00, 02, 03; W-97)
24. Give normal count of:
    (a) Erythrocytes
    (b) Leukocytes
    (c) Thrombocytes
    (d) Haemoglobin (S-03)
25. Define and describe in brief Phagocytosis and embolism. (W-97, 02; S-02)
26. Define Haemolysis. (S-03)

6

CHAPTER

Lymphatic System

INTRODUCTION

Lymphatic system provides immunity to our body and protects us against microorga and foreign material. Lymphatic system is also circulatory system that circulates ly from tissue to blood.

Lymphatic system consists of lymph, lymphatic vessels and structures and org that contain lymphatic tissue (specialized reticular tissue containing many lymphocy

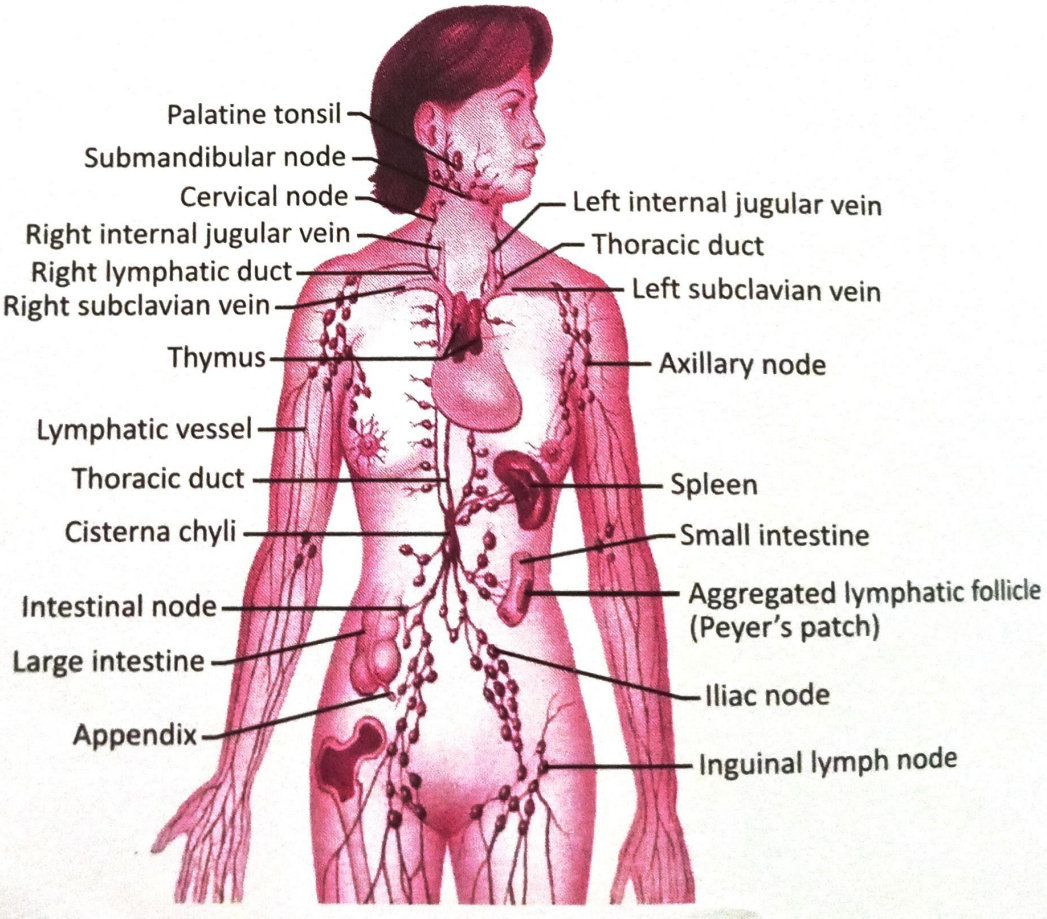

Fig. 6.1: *Lymphatic Syste. 1*

FUNCTIONS OF LYMPHATIC SYSTEM

1. **Tissue Drainage:** Lymphatic system transfer tissue fluid that is lymph to the blood.
2. **Transporting Dietary Lipids:** Lymphatic system transfer lipid and lipid soluble vitamins to the blood.
3. **Protection of the body (provide immunity):** Lymphatic system consists of organs that produce lymphocytes and provide immunity.
   (a) B-lymphocytes produced antibodies against foreign material in our body. Antibodies are proteins which react with foreign material and destroyed it.

B-lymphocytes ⟶ Antibodies — Foreign material

Antibodies destroy foreign material

   (b) T-lymphocytes kills foreign material by producing cell killing substances (cytotoxins)

T-lymphocytes ⟶ Cell killing substances (cytotoxins)

↓

Kill/destroy foreign material in body.

Lymphatic System consists of following organs:

1. The primary lymphatic organs are red bone marrow and the thymus.
2. The secondary lymphatic organs are lymph nodes, spleen.

LYMPH

Lymph is the excess tissue fluid and clear watery solution with white blood cells (Lymphocytes).

Formation of Lymph

As the blood passes through the capillaries in the tissue (group of cells), some water with soluble substances move out and enter into the spaces between the cells of tissue, leaving larger proteins, RBCs, platelets in the blood capillaries. The fluid leaks constantly out of blood stream through the permeable walls of blood capillaries in the tissue spaces is known as tissue fluid or interstitial fluid. This tissue fluid returns to the general circulation (Heart & Blood Vessels) through the Lymphatic system. It is a second circulatory system through which tissue fluid flows. Fluid present in the Lymphatic system is known as Lymph.

Blood	Lymph
It is reddish in Colour	It is pale yellow in colour
It has 2 main components: Plasma and blood cells RBCs, WBCs, Platelets	It is contains WBCs (Lymphocytes) which responsible for the immune response
It flows through the blood vessels.	It flows through the lymph vessels
It transports material from organ to organ.	It transports material from tissue cells to blood and again blood to tissue cells

Composition of Lymph

- Water
- Proteins
- Urea
- Enzymes
- Lymphocytes
- Creatinine
- Chlorides

Functions of Lymph

- Lymph transfer plasma proteins to the blood.
- Lymph remove metabolic waste from tissue, e.g., bacteria, cell debris to lym node and destroyed it.
- Lymph contains T and B lymphocytes which give immunity or defen mechanism.

Formation of Lymph Capillaries

These originate as closed end tubes in the intercellular spaces within most organs. A walls of lymph capillaries are more permeable, interstitial or tissue fluid, prote microorganism, cell debris and absorbed fat (in the intestine) can easily enter into the Fluid present in the Lymph capillares is known as Lymph.

Lymph capillaries unite to form larger vessels which again converted into large du i.e., the thoracic duct (in the left) and right lymphatic duct (in the right). Further the ducts pour (drain) the lymph into the left and right subclavian veins, respectively. Th veins connect with a number of smaller veins and drain into the superior vena c (major vein) which connects to heart.

LYMPH NODES

Lymph nodes are the oval or bean or kidney shaped body located (present) in the vessels.

Lymph node vary in size some are small as pin head and some are large as almo

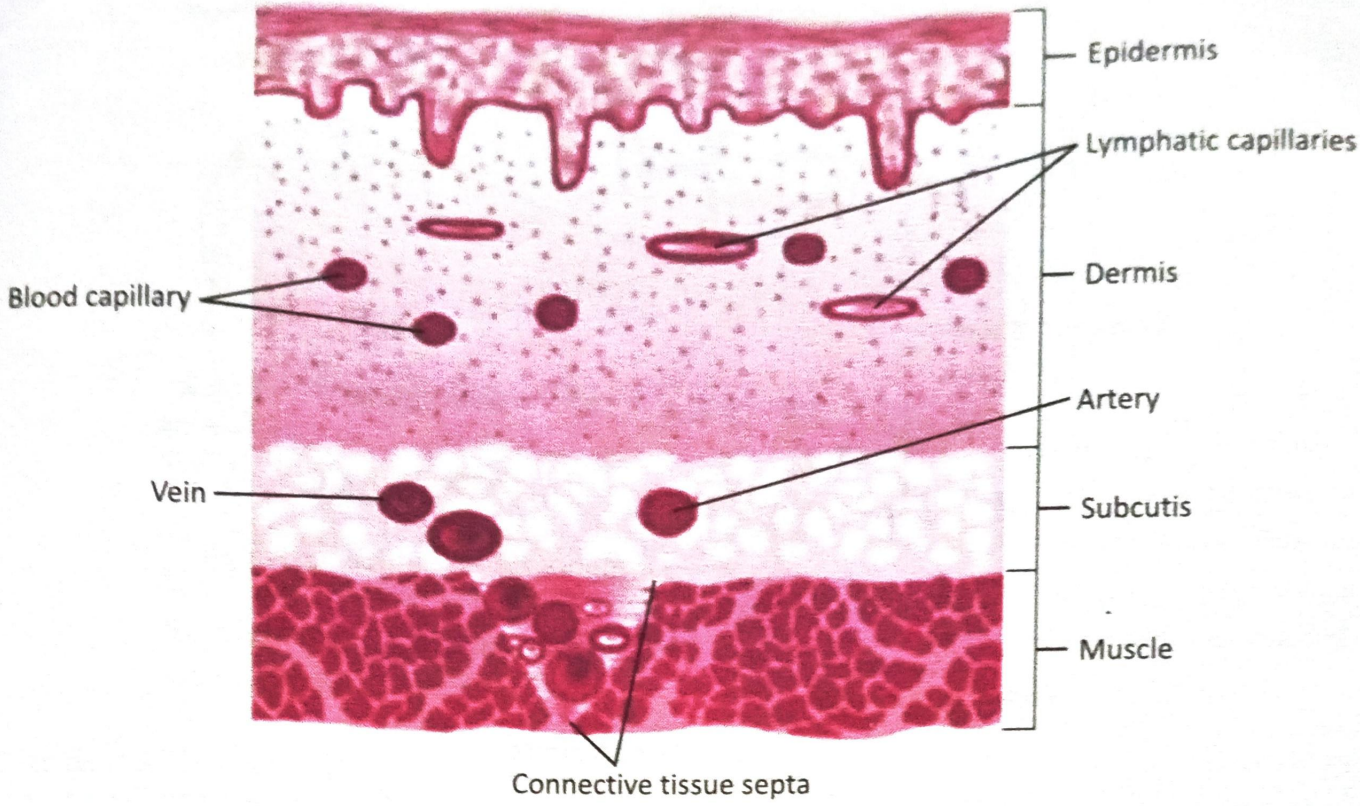

Fig. 6.2: *Lymph Capillaries*

Structures

- Lymph node usually occur in groups.
- Lymph node consist of covering which is called as fibrous capsule.
- Lymph node having partitions called trabeculae.
- Lymph node consists of reticular and lymphoid tissue.
- Lymphatic or lymphoid tissue contains lymphocytes and reticular tissue contains macrophages.
- 3-4 afferent lymph vessels enter into lymph node. While only one efferent lymph vessel goes away from the lymph node.
- Lymph node present in neck, axilla, thorax, abdomen and grow in region.

Functions of Lymph Node

- **Filtering of the lymph:** Afferent lymph vessel pour lymph into node. In the lymph node, lymph is filtered by reticular and lymphoid tissue by trapping microorganism and foreign particle.
- **Phagocytosis (killing of microorganism):** Lymph node is responsible for phagocytosis of microorganisms and foreign body. Reticular tissue contains macrophages which are responsible for phagocytosis.
- **Immunity:** Lymph node produced lymphocytes T and B. which give cell mediated and Antibody mediated immunity.

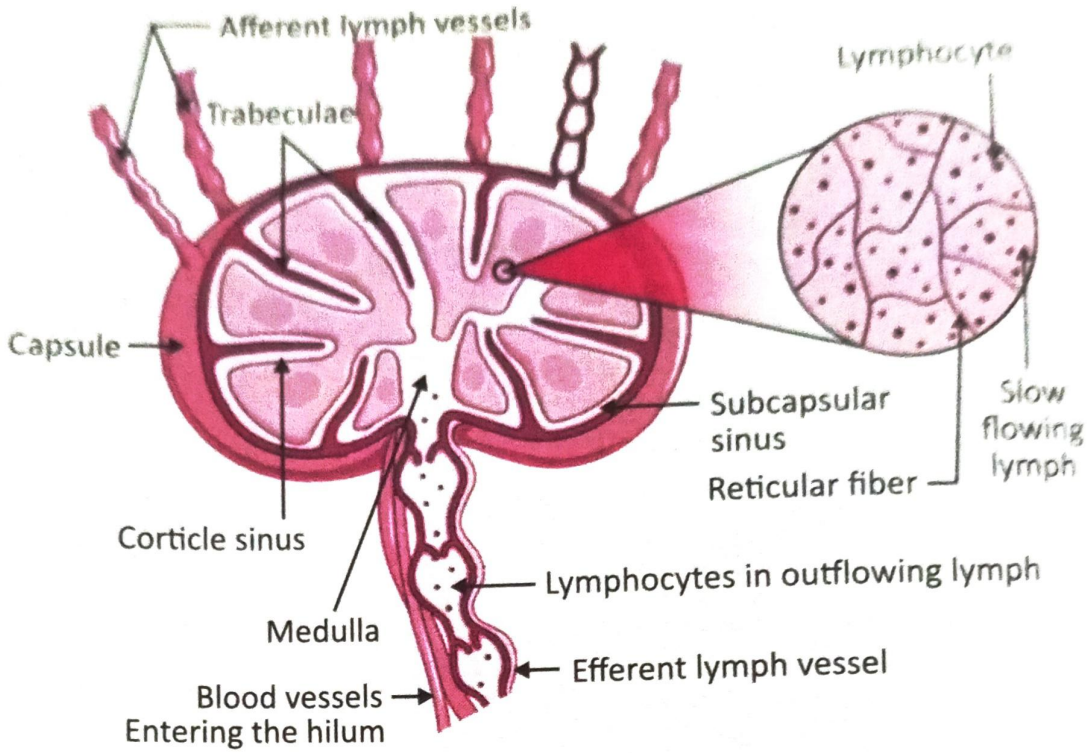

Fig. 6.3: *Lymph Node*

SPLEEN

- Spleen is the largest lymph organ.
- Spleen contain lymphatic tissue.
- The shape of spleen is oval.
- The spleen is located in left hypochondric region between the stomach diaphragm.
- Spleen has the average weight 200 gm. Its length is 12 cm and thickness is 2
- Spleen has concave surface.

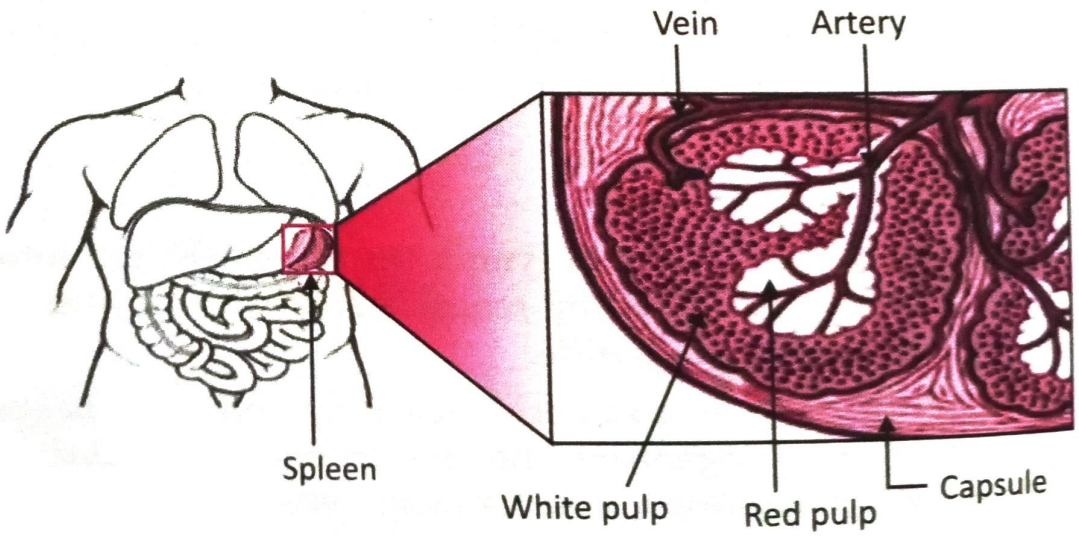

Fig. 6.4: *Spleen*

- **The structure entering and leaving the spleen at hilum are:**
  (a) Splenic artery
  (b) Splenic vein
  (c) Lymph vessel
  (d) Nerves.
- The spleen is covered with fibroblastic tissue (dense connective tissue) called Capsule.
- The fibroelastic tissue deeps down form trabeculae.
- Spleen consists of two different types of tissue that is white pulp and red pulp.
  (a) **White Pulp:** It consists of lymphocytes gives immunity. White pulp causes maturation of B-lymphocytes and produce antibody mediated immunity.
  (b) **Red Pulp:** It consists of red blood cells, Macrophages. Red pulp carries out the main function of spleen that is phagocytosis of bacteria and Destroyed old RBCs and Plateletes.

Functions of Spleen

- **Phagocytosis** (eating) of bacteria, old RBCs, platalets.
- **Antibody mediated immunity:** Spleen (white pulp) contains B-lymphocytes which are activated by the presence of antigen (microbes) and produce antibodies, e.g., in case of infection, the spleen provides defense against infection.
- **Foetal blood cell formation (Haemopoiesis):** During foetal stage, the spleen forms RBCs. Thus spleen act as a haemopoietic organ.
- **Storage of Blood:** Spleen acts as a reservoir of RBCs during stress or anemic condition. Spleen liberate out RBCs.

IMPORTANT QUESTIONS

1. What is Lymph? (W-00)
2. Describe lymph. Give its components or composition. (S-02; W-96)
3. Give the functions of Lymphatic system. (W-97)
4. What are lymph nodes? Give their functions. Draw diagram of Lymph node. (S-98 99, 01; W-96, 97, 98, 00, 01)
5. What is spleen? Describe its structure and function. (S-96, 97, 98, 02, 03; W-00)

7

CHAPTER

Cardiovascular System/ Circulatory System

INTRODUCTION

The system that circulates (move) blood through all parts of the body is called Circulatory System or Cardiovascular system.

The cardiovascular system consisting of:

1. **Heart:** It is a muscular pumping organ it provides driving force for circulation blood.
2. **Blood vessels:** Circulates (transports) blood throughout the body.

   Blood vessels are of five types which includes arteries, arterioles, capillaries, venules and Veins.

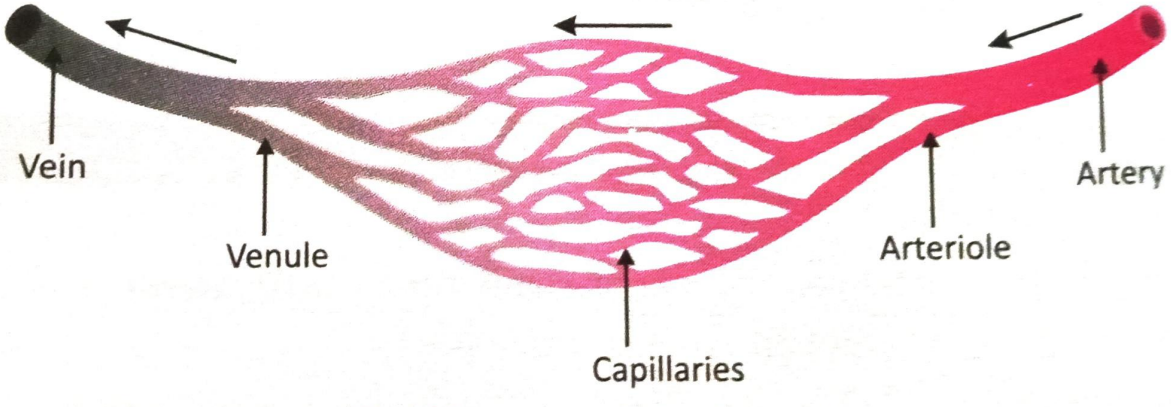

Fig. 7.1: ***Types of Blood Vessels***

The five main blood vessels are:

1. **Arteries:** Carry blood away from the heart.
2. **Arterioles:** Arteries divide into smaller arteries called arterioles.

3. **Capillaries:** As the arterioles enters into tissue, they branched into numerous tiny vessels called capillaries which are semipermeable. So exchange of gases (oxygen and carbon dioxide) takes through capillaries. Thus due to capillaries, impure blood (without oxygen) is converted pure blood (with oxygen). Also pure blood is converted into impure.
4. **Venules:** Groups of capillaries within a tissue reunite (joined) to form small veins called venules.
5. **Veins:** Venules are unite (join) to form Veins that convey blood from tissue back to heart.

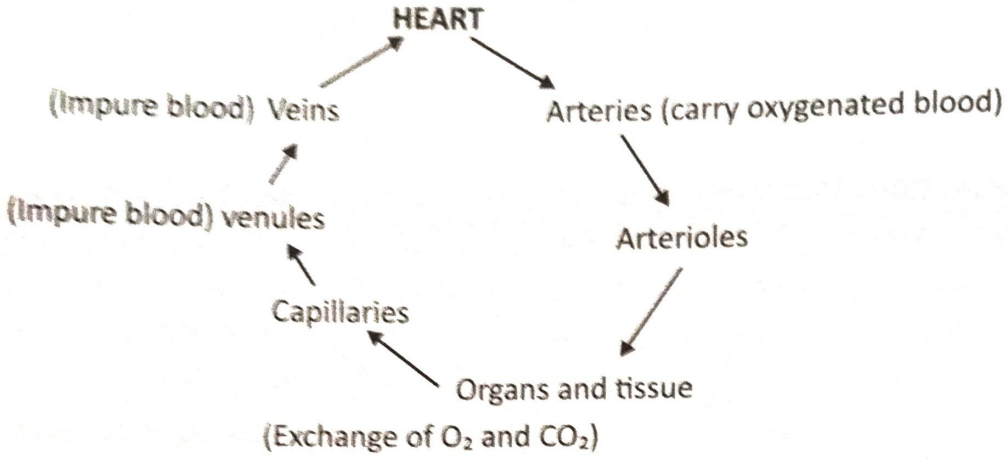

Fig. 7.2: ***Circulation of Blood in the Body***

STRUCTURE OF BLOOD VESSELS

Blood vessels, i.e., arteries and veins consists of 3 layers but capillaries consists of single layer, i.e., called endothelial layer which is responsible for the exchange of gases between the blood and surrounding tissue.

1. **Tunica Externa (Outermost Layer)** is made up of connective tissue providing protection to blood vessesl.
2. **Tunica Media (Middle Layer)** is made up of of muscular tissue, i.e., smooth muscles which changes the diameter of blood vessels to regulate blood flow and blood pressure. Tunica media is thicker in arteries than veins because arteries can withstand to high blood pressure.
3. **Tunic Interna or Intima (Innermost Layer)** is made up of single endothelial layer, i.e., epithelial tissue which are direct contact with blood flow. It releases substances and causes relaxation of blood vessels.

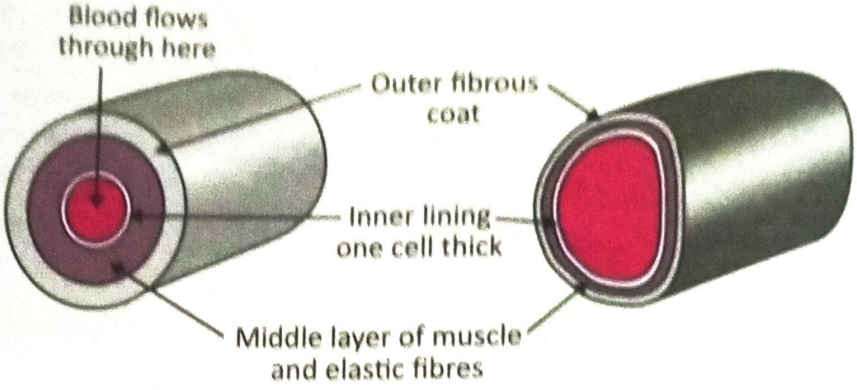

Fig. 7.3: *T.S. of Artery and Vein*

Table 7.1: Distinguish between Arteries and Veins

Arteries	Veins
1. Arteries carry blood away from the heart to different parts of the body, e.g., aorta big artery.	1. Veins carry blood from different parts of the body to the heart, e.g., superior and inferior venae cavae.
2. Arteries carry oxygenated blood from heart to different organs except pulmonary artery (pulmonary artery carries deoxygenated blood).	2. Veins carry deoxygenated blood from different organs to the heart except Pulmonary veins (Pulmonary veins carry oxygenated blood).
3. Arteries are thick walled So arteries are withstand to the high blood pressure.	3. Veins are thin walled. So veins are not withstand to the high blood pressure.
4. Arteries do not have valves.	4. Veins contains valves which prevent backflow of blood.
5. When an artery is cut, blood spurts at high pressure.	5. When an vein is cut, blood do not spurt at high pressure but escapes slowly from vein.
6. Blood pressure in artery is high.	6. Blood pressure in vein is low or slow.
7. Tiny arteries offer resistance to blood flows arteries are called resistance vessels.	7. Veins are called capacitance vessels because they have the capacity to hold large amount of blood.
8. Renal arteries to kidney, hepatic artery to liver, coelic artery to stomach, splenic artery to spleen, superior mesenteric artery to small intestine, inferior mesenteric artery to large intestine, phrenic arteries to diaphragm.	8. Renal vein from kidney, hepatic vein from liver, gastric vein from stomach, superior mesenteric vein from small intestine, inferior mesenteric vein from large intestine, phrenic vein from diaphragm.

INTERNAL STRUCTURE OF THE HEART

Heart is cone shaped; hollow muscular organ. Its size is of the fist of the person. It is about 12 cm long, 9 cm wide and 6 cm thick. Its weight about 250 gm in adult female, 300 gm in adult male.

Human heart is of four chambered organ– right atrium and right ventricle, left atrium and left ventricle. The heart is divided into right side and left side by the vertical septum. Right side is divided into right atrium and right ventricle. Left side is divided into left atrium and left ventricle.

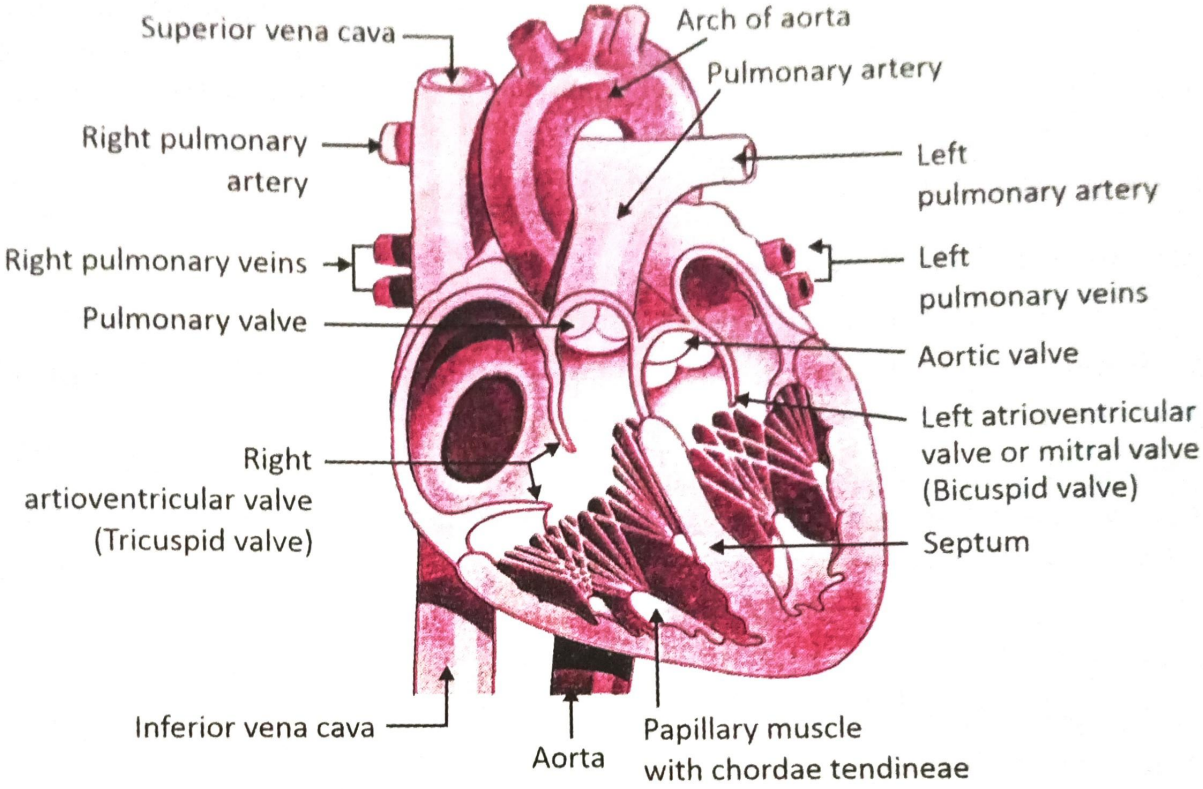

Fig. 7.4: *Heart*

LOCATION OF THE HEART

- The heart is situated in the thoracic cavity in the mediastinum (space) betwe the two lungs.
- It is directed towards the left side of the chest. It is present as base above and apex below

LAYERS OR COVERINGS OF THE HEART

Heart is composed of three layers (covering of the heart):

1. Pericardium Layer (Outermost)
2. Myocardium Layer (Middle)
3. Endocardium Layer (Inner)

Table 7.2: Layers or coverings of the heart

Pericardium Layer	Myocardium Layer	Endocardium Layer
Made up of connective tissue.	Made up of cardiac muscles (muscular tissue)	Made up of endothelial cells (epithelial tissue)
Functions		
• It provides protection to the heart. • It prevents the over stretching of the heart. • It keeps the heart in a fixed position between the lungs.	Cardiac muscles causing pumping of the heart. (pushing blood forward)	Endothelial releases substances causes contraction and relaxation of heart, e.g., nitric oxide

Pericardium consists of two layers:

1. **Fibrous (Parietal) Pericardium (outer layer):** Tough connective tissue.
2. **Serous (Visceral) Pericardium:** Deeper, thinner and delicate (soft) membrane. It is adherent or closed to the heart muscle.

Between fibrous and serous pericardium, there is pericardium fluid which allows smooth movement between the two layers during the heart beat.

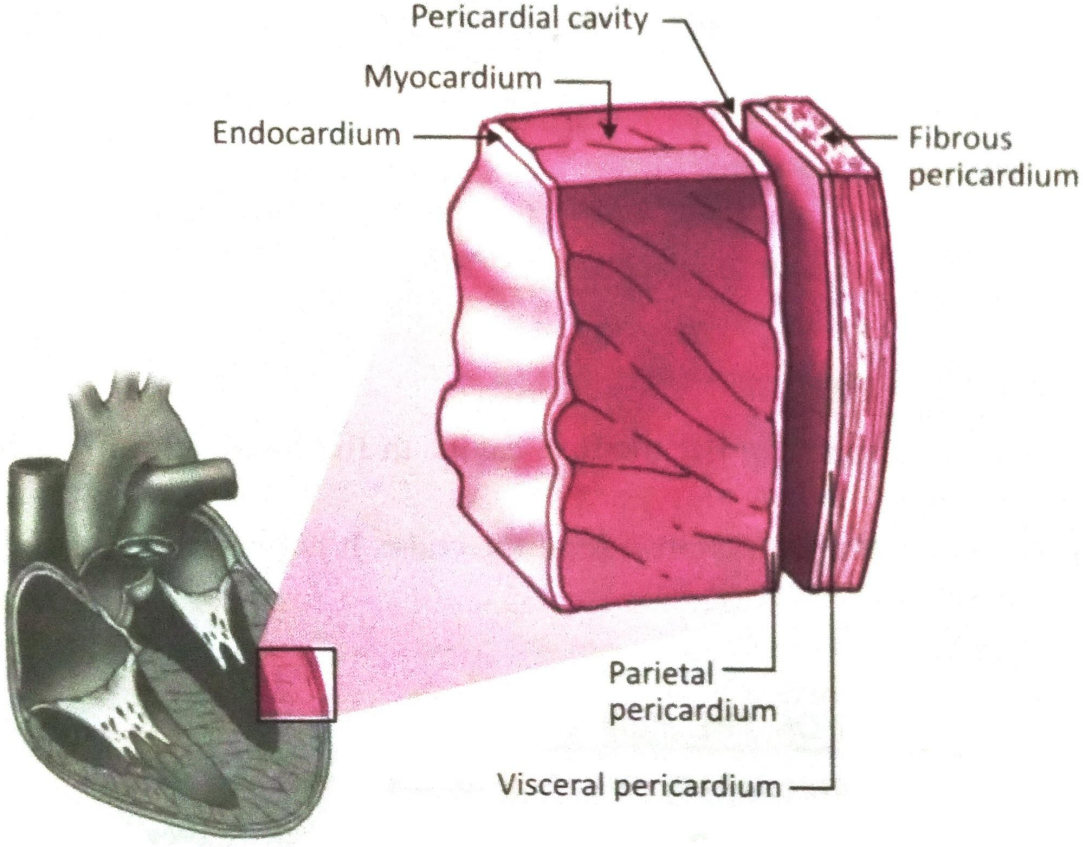

Fig. 7.5: ***Layers of Covering of the Heart***

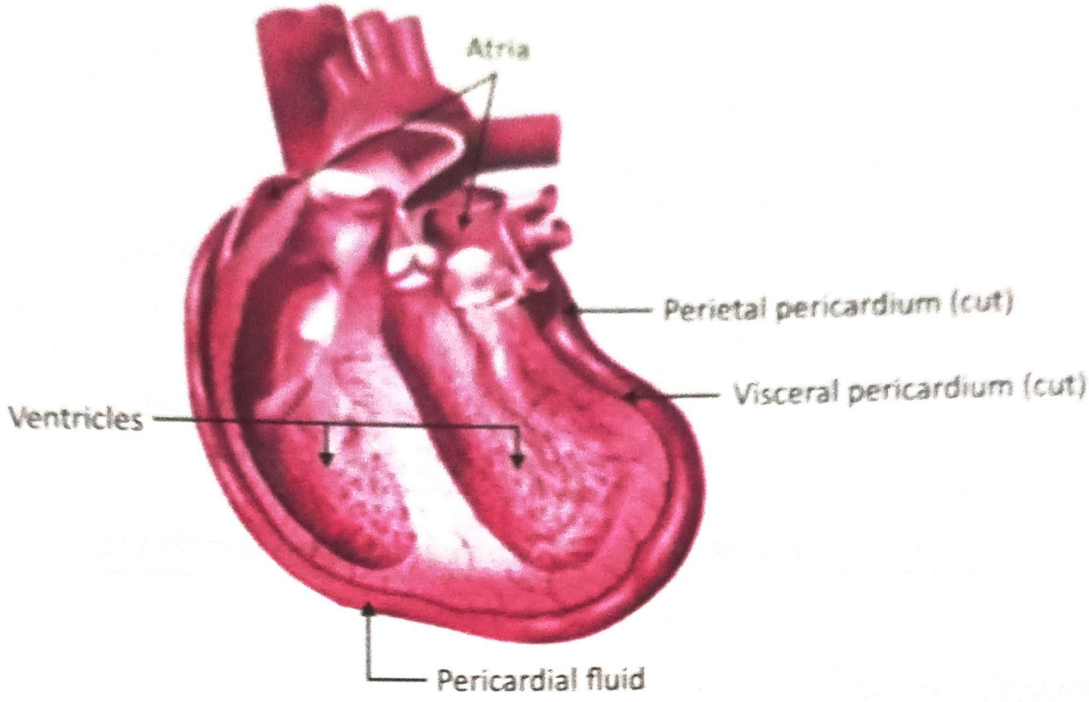

Fig. 7.6: *Layers of Pericardium*

VALVES OF THE HEART

Valves determines the pathway of blood flow. By opening and closing, Valves prevent the backflow of blood in the heart. They composed of dense connective tissue covered by endocardium (epithelial tissue). The four Valves of heart are:

(i) Two Atrioventricular (AV) valves present at right and left side of the heart.

(a) Right atrioventricular valve or Tricuspid valve present between right atrium and right ventricle. It allow blood to flow in right direction. It is made up of 3 leaflets (leaf like structure)

(b) Left atrioventricular valve or Bicuspid valve or mitral valve present between left atrium and left ventricle. It allow blood to flow in left direction. It is made up of 2 leaflets (leaf like structure)

(ii) Semilunar valves (SL valve) – These are half moon like so named semilunar. They are present at pulmonary artery and Aorta

(iii) The ventricular walls have little muscle projections called papillary muscles. On papillary muscles, chordae tendinae are attached.

(iv) Chordae tendinae are little threads of the myocardium into ventricles which closes the tricuspid and bicuspid valve during ventricular contraction.

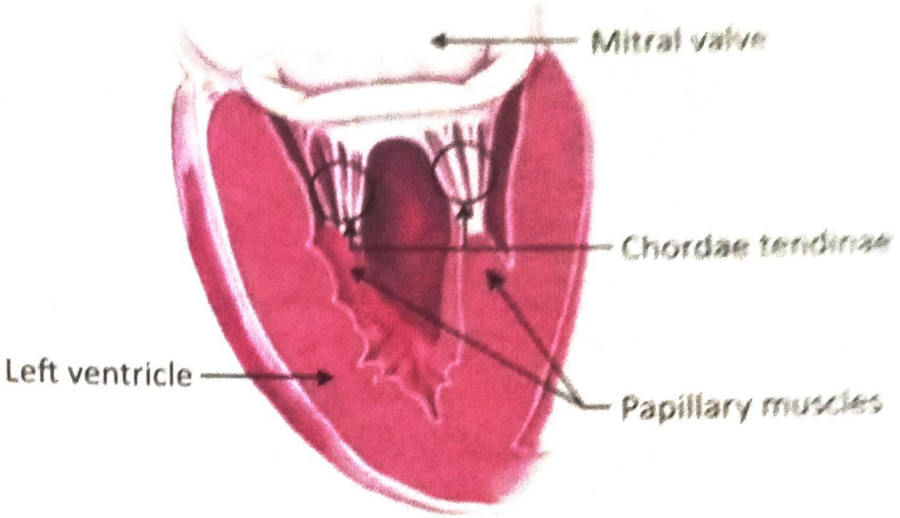

Fig. 7.7: ***Ventricular wall with muscle projections and threads***

BLOOD FLOW THROUGH THE HEART

1. The Superior Vena Cava and Inferior vena are the two largest veins in the. These veins carry impure or deoxygenated blood and pour their impure into right atrium.
2. Then atrioventricular (Tricuspid) valve open and impure blood enters into ventricle. Right side contains impure blood.

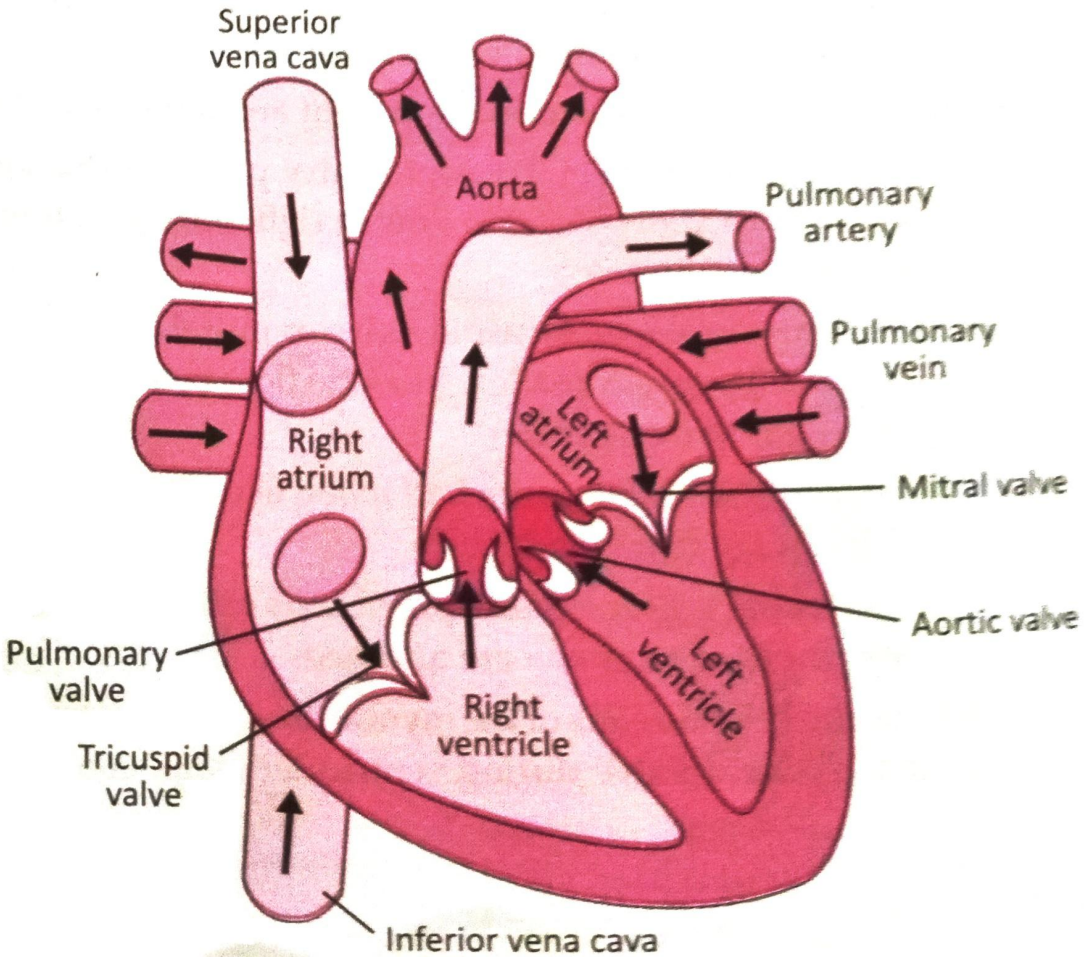

Fig. 7.8: ***Blood flow through the Heart***

3. Impure blood from right ventricle pumped into the pulmonary artery. The opening of the pulmonary artery is controlled by the pulmonary valve. It contains three semilunar cusps. This valve prevent the backflow of blood into right ventricle.
4. The pulmonary artery then divides into left and right pulmonary artery. Left pulmonary artery carry impure blood to the left lung and right pulmonary artery carry impure blood to the right lung. In lungs, impure blood is converted into pure blood (artery to arterioles to capillaries, capillaries surround to alveoli, oxygen from alveoli enters into capillaries blood, capillaries unite to form venules, venules unite to form pulmonary veins).
5. From lungs, two pulmonary veins carry pure or oxygenated blood to the left atrium.
6. From left atrium, pure blood enters into left ventricle through the opening of the left atrioventricular valve (Biscuspid valve). Left side contains pure (oxygenated blood).
7. From left ventricle, pure blood pumps into aorta by opening of aortic valve. Aorta provides pure blood to all parts of the body.

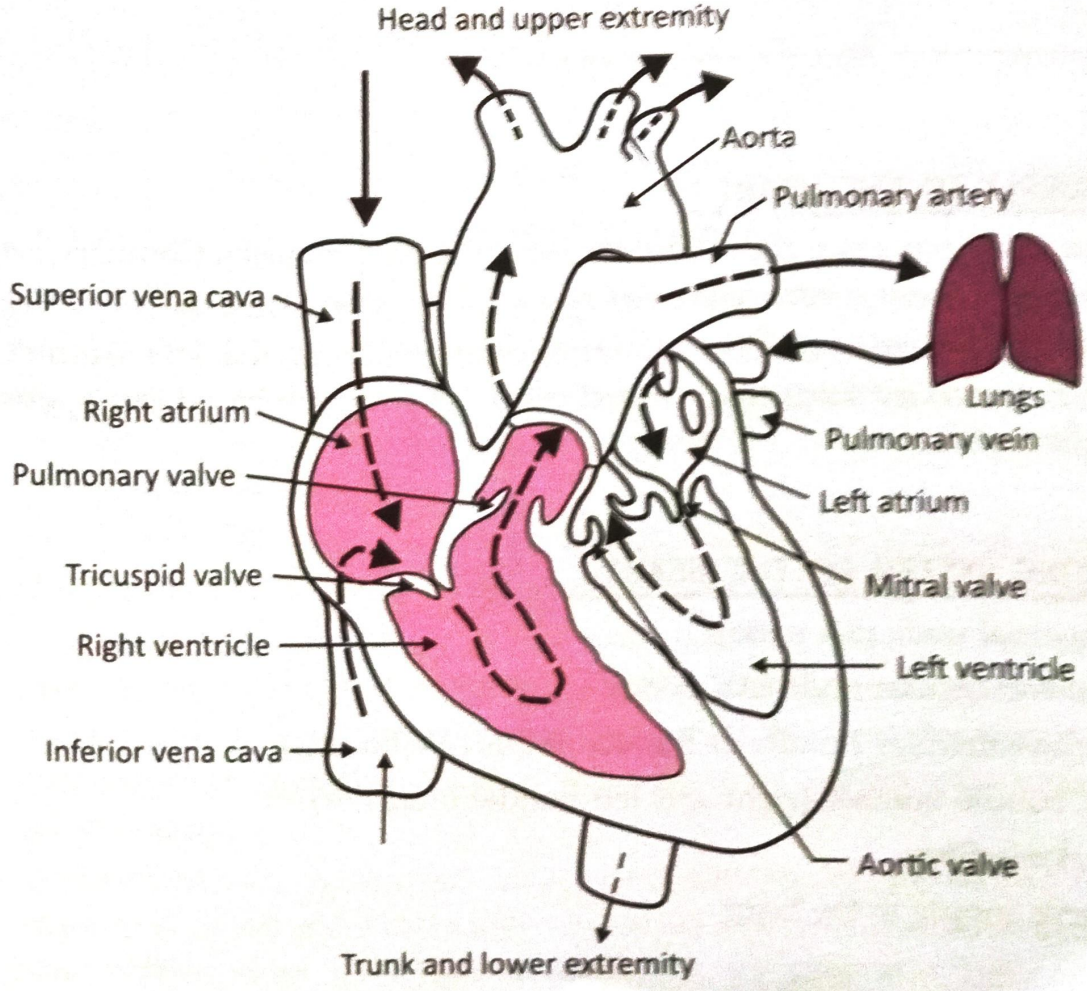

Fig. 7.9: ***Blood Flow from Heart to Lungs and again Lungs to Heart***

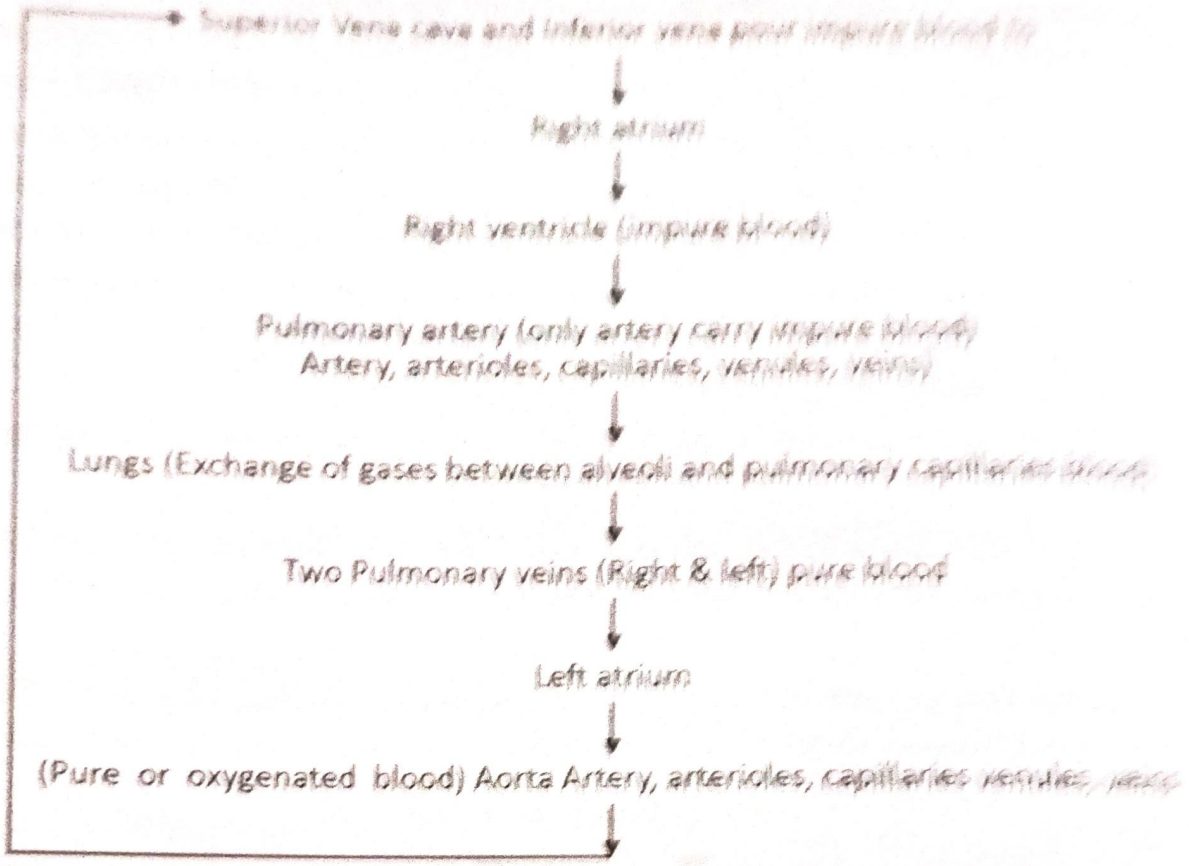

BLOOD SUPPLY TO THE HEART

1. **Arterial Circulation (Pure blood):** From the base of aorta, Coronary arteries emerged. These coronary arteries takes 5% of blood and supplies to the [illegible]
2. **Venous circulation (impure blood):** Several small veins that join to form Coronary sinus. Coronary sinus (thin walled vein) carry impure blood and opens in right atrium.

CONDUCTING SYSTEM OF THE HEART

1. Sinoatrial node (SA node)
2. Atrioventricular node (AV node)
3. Atrioventricular Bundle or Bundle of His (AV bundle)
4. AV bundle braches (right and left bundle branches)
5. Purkinje fibres
6. Nerve supply to the heart

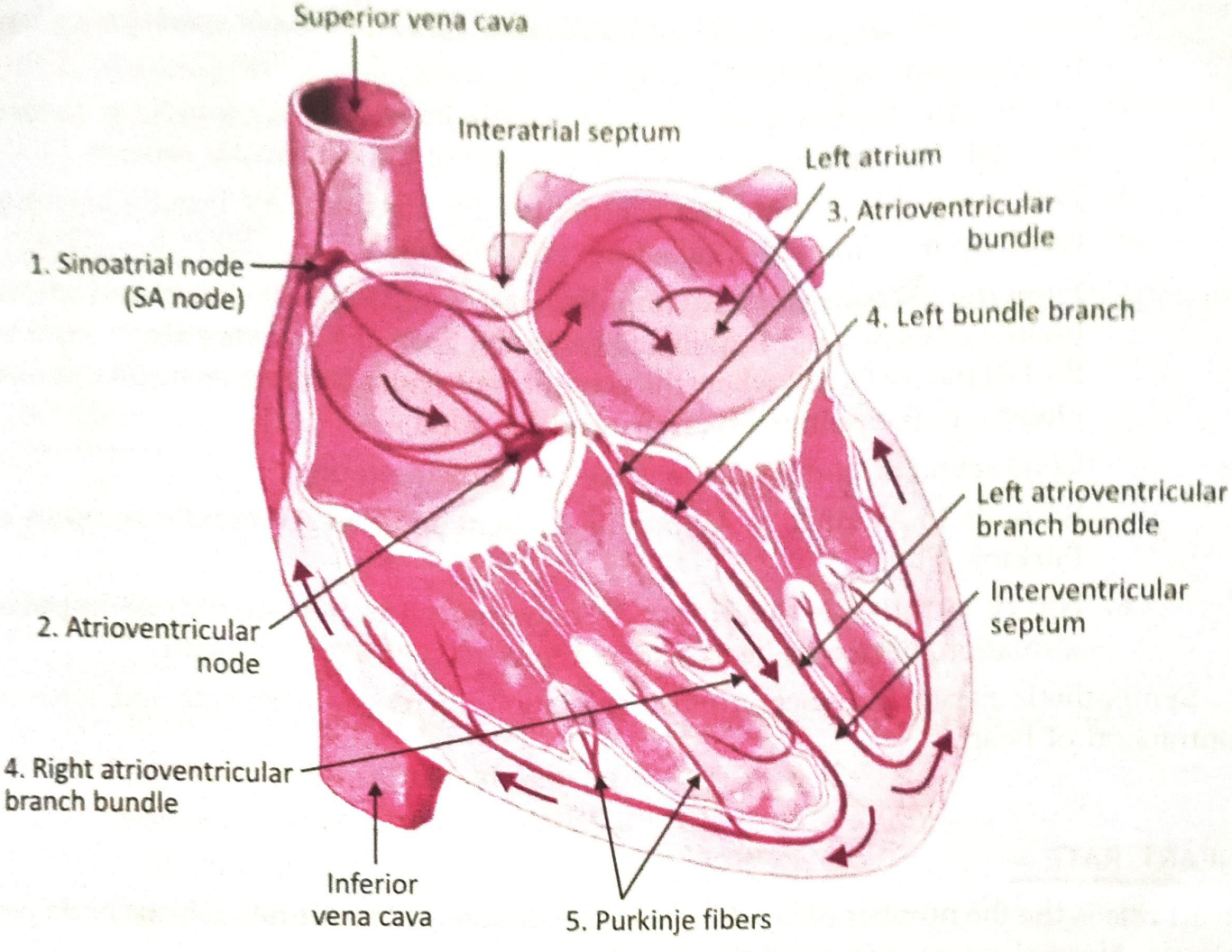

Fig. 7.10: *Conductive System of the Heart*

(a) Heart beats continuously because of cardiac muscles. Thus, heart has an intrinsic system and cardiac muscles automatic contract due to action potential which passes along the cardiac cell membrane. Action potential occur because of movement of charged ions between the inside and outside of the cell through proteins called ion channels.

(b) Cardiac action potential or electric impulse (sudden force) travel through the conductive system in the following sequence:

1. **Sinoatrial Node (SA Node):** It is a small mass of specialized neuromuscular cells situated in the wall of the right atrium near the opening of the superior vena cava. The SA node is the 'pacemaker' of the heart because it produce impulse more rapidly. Firing or Stimulation of the SA node causes atrial contraction.
2. **Atrioventricular Node (AV Node):** It is situated in the wall of the atrial septum near the atrioventricular valves. AV node conducts (carry) impulses that coming from SA node and atria. The AV node also has a secondary pacemaker function that is it produces impulse if there is problem with SA node. AV node having less/slow intrinsic firing rate than SA node.

3. **Atrioventricular Bundle (Bundle of His):** This is a mass of specialized that originate from the AV node.
4. **AV Bundle Braches (right and left bundle branches):** AV bundle is di into right and left branch at the upper end of the ventricular septum
5. **Purkinje Fibres** within the ventricular myocardium, AV bundle branch break up into fine fibres called the Purkinje fibres.

   From the AV node electrical impulses passes to AV bundle, Right and left bundle branches and Purkinje fibres to the apex of the myocardium (upper the last part of Heart) where the wave of ventricular contraction begins, pumping blood into the pulmonary artery and the aorta.

   Conduction of impulse takes place by following route:

   SA node to AV node to AV bundle to Right and Left AV bundle branches Purkinje fibres.
6. **Nerve supply to the Heart:** Parasympathetic nerves reduce impulse formation, decreases heart rate and force of contraction of heart.

Sympathetic nerves enhance impulse formation, increases heart rate and force contraction of heart.

HEART RATE

Heart rate is the the number of heart beats in one minute. OR Heart rate is heart beats p minute. Normal range is 60 to 80 per minute.

Factors determines heart rate:

1. **Age:** In babies and small children heart rate is more and rapid becaused of hig physical activities.
2. **Autonomic Nerve Activity:** Parasympathetic nerves decreases heart rate a sympathetic nerves increases heart rate.
3. **Baroreceptor Reflex:** These are nerve endings sensitive to pressure changes a situated in the aorta. A rise in blood pressure in arteries stimulate baroreceptor Then these baroreceptor stimulate cardiac centre in medulla oblongata (bra and Parasympathetic (vagus) nerves which decreases heart rate.
4. **Circulating Chemicals or Hormones in the Body:** Hormones adrenaline a noradrenaline secreated by the adrenal medulla (above medulla) increases hea rate. Hypoxia (less oxygen) and elevated carbon dioxide in the body stimula heart rate. Electrolytes imbalance (Potassium, calcium, chloride, sodium) slow heart rate.

   Exercise: In exercise, active muscles need more blood so heart rate increases
6. **Emotional states:** During excitement, fear or anxiety the heart rate is increas (due to sympathetic nerves stimulation).

7. **Gender:** Heart rate is faster in women than in men.
8. **Position:** When the person is upright (stand) increases heart rate.
9. **Temperature:** Body temperature increases, heart rate increases.

CARDIAC CYCLE

During each heart beat or cardiac cycle, the heart contracts and relaxes. The period of contraction is called systole and that of relaxation diastole.

Definition

The events which occur in the heart during the circulation of blood are known as Cardiac cycle.

Stages/Events of Cardiac Cycle

Cardiac cycles per minute ranges from 60 to 80.

Taking 74 as an average, each/one cardiac cycle lasts for about 0.8 second.

Each cardiac cycle consists of following events:

1. Atrial systole (contraction of atria): 0.1 sec.
2. Ventricular systole (contraction of ventricles): 0.3 sec.
3. Complete cardiac diastole (relaxation of atria and ventricles): 0.4 sec.

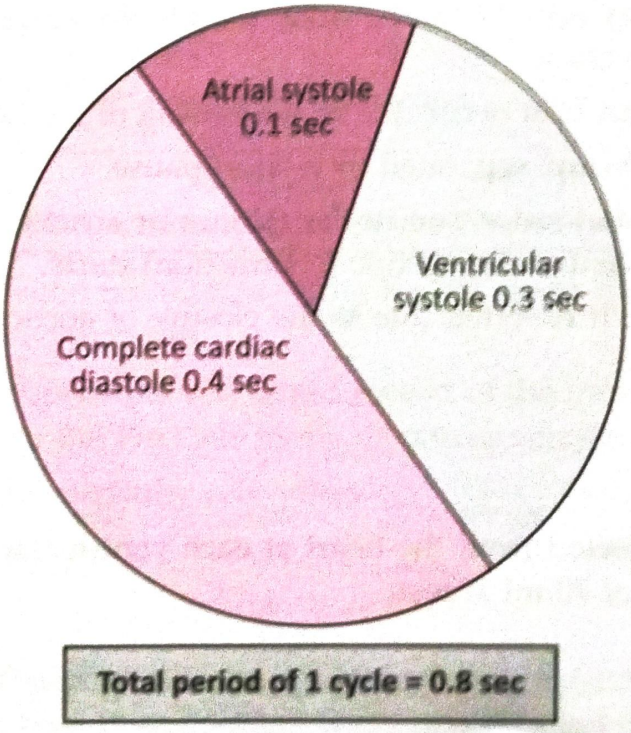

Fig. 7.11: *Total Period & Events of Each Cardiac Cycle*

1. The superior vena cava and the inferior vena cava carry deoxygenated blo the right atrium at the same time as four pulmonary veins bring oxyg blood into the left atrium. Then SA node produce electric impulse and w contraction spreads on the right and left atria. This wave of contraction c atrial contraction called atrial systole (0.1 sec). Due to atrial systole, both pour their blood into ventricles called ventricular filling.
2. Electric impulse from SA node passes to the AV node, AV bundle, right a AV bundle branches and purkinjifibres. So wave of contraction spreads right and left ventricles. This wave of contraction causing ventricular cont called ventricular systole (0.3 sec). Right ventricle pump deoxygenated blo Pulmonary artery and Left ventricle pump oxygenated blood into aorta ventricles pumping blood into pulmonary artery and the aorta. When the ver are contracting the impulse of contraction is absent on atrias hence they get r called atrial diastole. When the atrias are contracting, ventricles are relaxed ventricular diastole. Thus, atrias and ventricles are contract alternately pro cardiac cycle.
3. After contracting, the heart is in resting condition that is there is not mu contraction. This resting stage is called as complete cardiac diastole is of (This alternate sequence of events is called as cardiac cycle.

HEART SOUND

1. Listening of Heart sounds can be done with Stethoscope. It is placed up upper side of the chest.
2. The sound of heart beat occur due to the closing of the heart valves.
3. Two sounds 'Lub-dup' separated by a short pause.

First Sound Lub: It is louder due to the closure of atrioventricular (Tricusp bicuspid) valves. Here, ventricular systole (contraction) starts.

Second Sound Dup: It is softer, due to the closure of aortic and pulmonary Here atrial systole starts.

STROKE VOLUME

It is amount of blood ejected from the heart at each ventricular contraction. In h adult, stroke volume is of 70 ml at rest.

CARDIAC OUTPUT

It is amount of blood ejected from the heart in one minute. Cardiac output expres litres per minute (litre/minute).

Cardiac output = Stroke Volume × Heart rate per minute

5040 ml or 5 litre = 70 ml × 72

In healthy adult at rest, stroke volume is 70 ml and heart rate is 72 per minute so Cardiac output is 5 litres.

In exercise, cardiac output is 25 litres per minute. In athlets cardiac output is 35 litres per minute.

ELECTRIAL CHANGES IN THE HEART OR ELECTROCARDIOGRAM (ECG)

Electrocardiogram is the test to check the heart condition. ECG records the electrical activity of the heart in the form of graph called electrocardiograph.

ECG provides information about the rhythm of the heart beats (steady or irregular) and timing of the electrical impulses as they move through the heart. The change in ECG indicate heart related problems.

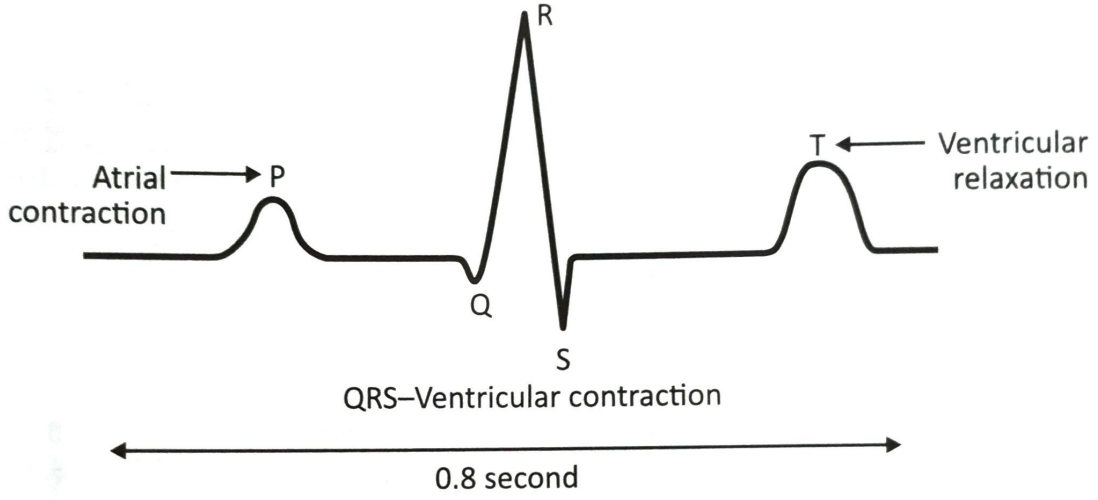

Fig. 7.12: *Electrocardiogram of one Cardiac cycle.*

1. P- 'P' wave arise when the impulse from the SA node spread over the atrias. It occur due to atrial contraction.
2. The QRS complex represents very rapid spread of the impulse from the AV node to AV bundle and to the Purkinje fibres. It causes ventricular contraction.
3. T- wave represents ventricular relaxation.

PULSE

As the heart pushes blood through the arteries, the arteries expand and contract with the flow of the blood, create a travelling pressure wave that is called the Pulse.

The pulse rate is the number of heart beats per minute. The pulse rate can determined by pressing the fingertips at the surface of body where arteries travels common pulse site is wrist (radial artery), elbow (brachial artery), neck (carotid arte

The pulse rate normally 70 to 80 beats per minute at rest.

Tachycardia (tachy-fast) – pulse rate more than 100 beats/minute.

Bradycardia (brady-slow) – pulse rate below 60 beats/minute.

Following information can be obtained from the pulse:

1. Heart rate-rate at which heart is beating (no of heart rate per min).
2. Regularities or variations in the heart rate.
3. Volume or strength of the beat means maximum number of heart beats duri exercise
4. Rthyme- whether heart have repeated pattern of movement that is contracti and relaxation

BLOOD PRESSURE

Definition

Blood Pressure (B.P.) is the force or pressure that the blood gives (exerts) on the walls the blood vessels.

Normal range: 120/80 mmHg; 16/11 KPa

120 mmHg is systolic B.P

80 mmHg is Diastolic B.P.

- When the left ventricle contract and pushes blood into the aorta, the pressu given by blood in arteries is called systolic B.P. It is 120 mm of Hg or 16 KPa
- When complete cardiac diastole occurs and the heart is resting stage, the pressu within the arteries is called diastolic blood pressure. In an adult this is about mm of Hg or 11 Kpa.
- The difference between systolic and diastolic blood pressure is the pulse pressu

Factors Influencing Blood Pressure

1. **Contractile force of heart:** Greater contractile force of the heart, greater will blood pressure.
2. **Cardiac output:** Greater caradiac output, greater will be B.P.
3. **Elasticity of wall of blood vessels:** Greater elasticity of blood vessels, greater w be B.P.
4. **Volume of blood circulated in the circulatory system:** Greater Volume of bl circulated in the circulatory system, greater will be B.P.

5. **Peripheral resistance:** More peripheral resistance, greater will be B.P. (It is the resistance offer by the blood vessels. Resistance is due to the decrease in the lumen size of blood vessels.)
6. **Physiological condition of the body:** During heavy exercise, B.P increases. During resting period, B.P is decreases.
7. **Emotional conditions:** In excitement, fear or anxiety, B.P. increases.
8. **Age:** B.P. is more in infants, babies and small childrens. B.P. is less in adults.
9. **Body weight:** More body weight, more B.P.

Regulation of Blood Pressure

It is done by:

1. Cardiac centre in Medulla (brain)
2. Baroreceptore, i.e., pressure receptors in aortic arch
3. Chemoreceptors, i.e., is nerve endings present in carotid and aortic artery.
4. Autoregulation by kidney.

Table 7.3: Regulation of Blood Pressure

Baroreceptores	Chemoreceptors
These are nerve endings situated in the aortic arch known as pressoreceptors	These are nerve endings situated in the aortic arch and carotid artery (arise from aorta) known as chemosensor
Barorceptors detects (senses) the change in blood pressure and sent this information to the brain (Medulla oblongata) so that blood pressures can be regulated	Chemoreceptors detects (senses) the change in oxygen, Carbondioxide and hydrogen ion concentration in blood and transfer this information to brain (Medulla oblongata) so that to restore constant internal environment that is homeostasis
Barorceptors detects increased blood pressure ↓ Glossparyngeal nerve from barorecetors sent information to brain (Medulla oblongata) ↓ From medulla oblongata, vagus nerve transmit inhibitory signal to Sinoatrial node ↓ Depresses Sinoatrial node and decreases blood pressure with decrease in heart rate	Chemorecptors detects increased in CO_2 and decreased in O_2 Concentration ↓ Glossparyngeal nerve from Chemorecptors sent information to brain (Medulla oblongata) ↓ From medulla oblongata, vagus nerve stimulate respiratory activity (gain oxygen) and symphathetic activity to increase heart rate & increase blood pressure

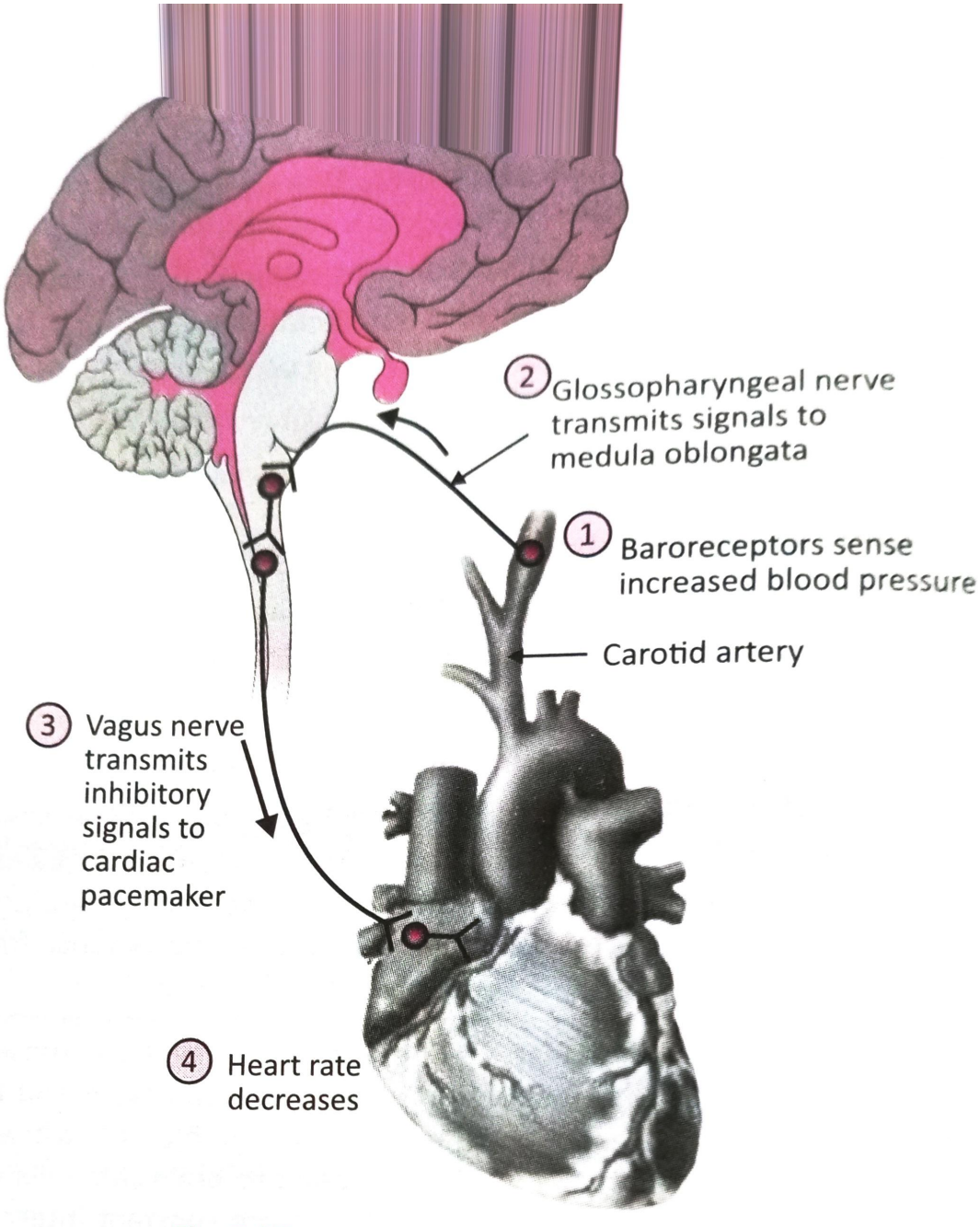

Fig. 7.13: *Regulation of Blood Pressure*

5. Hormonal regulation, e.g., Adrenaline, Noradrenalin, ADH, Angiotensin II

   Adrenaline, Noradrenalin are released by Adrenal gland (endocrine gland above kidney) in the response to strong emotions such as fear or anger which increase blood pressure and heart rate.

   Antidiuretic Hormone (ADH) is released by Posterior Pituitary gland (endocrine gland in the brain) in response to low blood volume or dehydration which causes constriction of blood vessels and increases blood pressure.

6. Autoregulation, i.e., automatic adjustment by kidney for the maintaining blood flow and blood pressure. The kidneys provide a hormonal mechanism the Renin angiotensin aldosteron system for the regulation of blood pressure.

Measurement of Blood Pressure (B.P.)

B.P can be recorded by following method:

1. Palpitary method
2. Oscillatory method
3. Auscultatory method

Auscultatory method is the mostly used for measurement of blood pressure.

Auscultatory Method

Ausculation means listening of heart sound (lub-dup).

Here, we hear heart sounds using stethoscope. So it is known as Ausculatory method.

1. The blood pressure is measured by the instrument is known as Sphygmomanometer.

   It consists of:

   (a) Rubber bag – wrapped around arm

   (b) Presure pump – to give pressure up to 200 mmHg

   (c) Mercury manometer

   (d) Rubber tube or things

2. The patient of whose blood pressure is to be record must be at rest.
3. Rubber bag is then wrapped around the upper arm.
4. Then with the help of pressure pump, the air is pushed into the rubber bag till the pressure of 200 mmHg is reached.
5. Then chest piece of a stethoscope is placed below the rubber bag on the brachial artery and heart sound are observed.
6. Now the air in the bag is slowly released.
7. The stage at which first heart sound (pulse) is heard, the reading on manometer is systolic B.P.
8. The air from the rubber bag is further released and the stage at which the heart sounds stops, this reading on manometer is diastolic B.P.

Fig. 7.14: *Sphygmomanometer*

CIRCULATION OF BLOOD

1. Coronary circulation
2. Pulmonary circulations
3. Systemic circulation
4. Portal circulation

Coronary Circulation

Coronary circulation refers to the blood circulation to the heart itself for its nourishment. Coronary arteries and Coronary veins supplies blood to the heart.

From the base of the aorta, right and left coronary arteries arises and supplies pure blood to the heart where it delivers oxygen and nutrients to heart muscle and collects carbon dioxide and waste and moves into coronary veins. This deoxygenated blood from myocardium of heart is collected by coronary sinus (small veins joined to form coronary sinus), it drain directly into the right atrium.

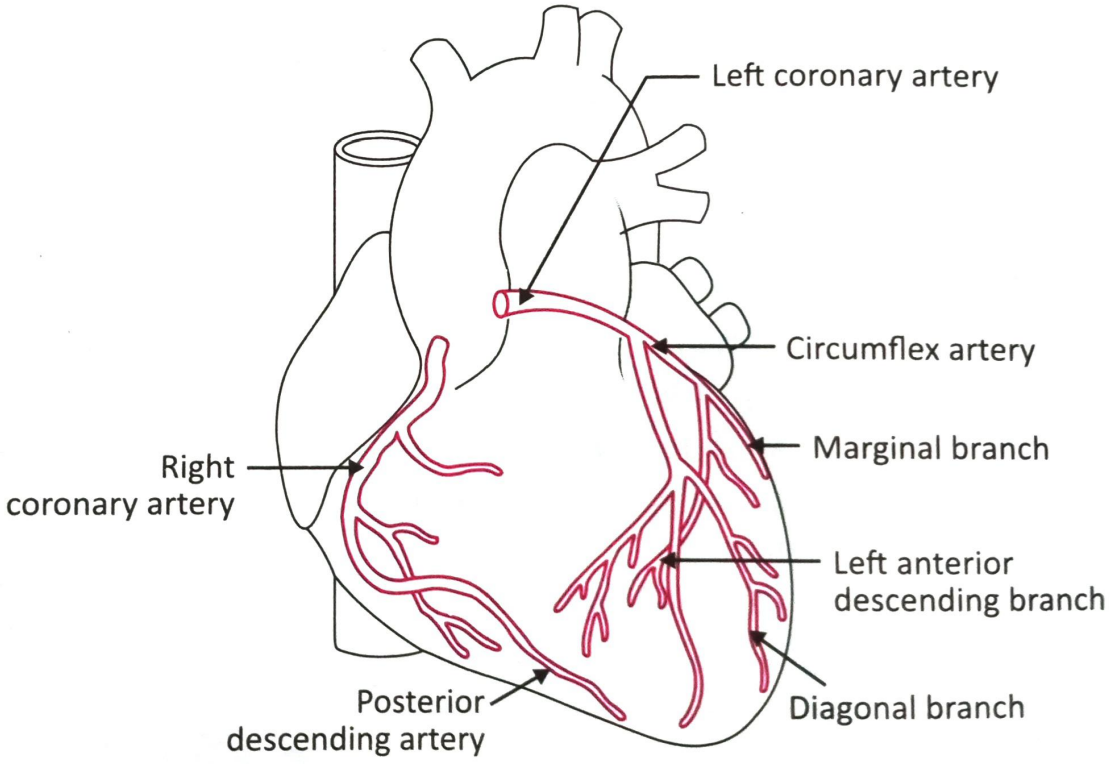

Fig. 7.15: *Coronary Circulation*

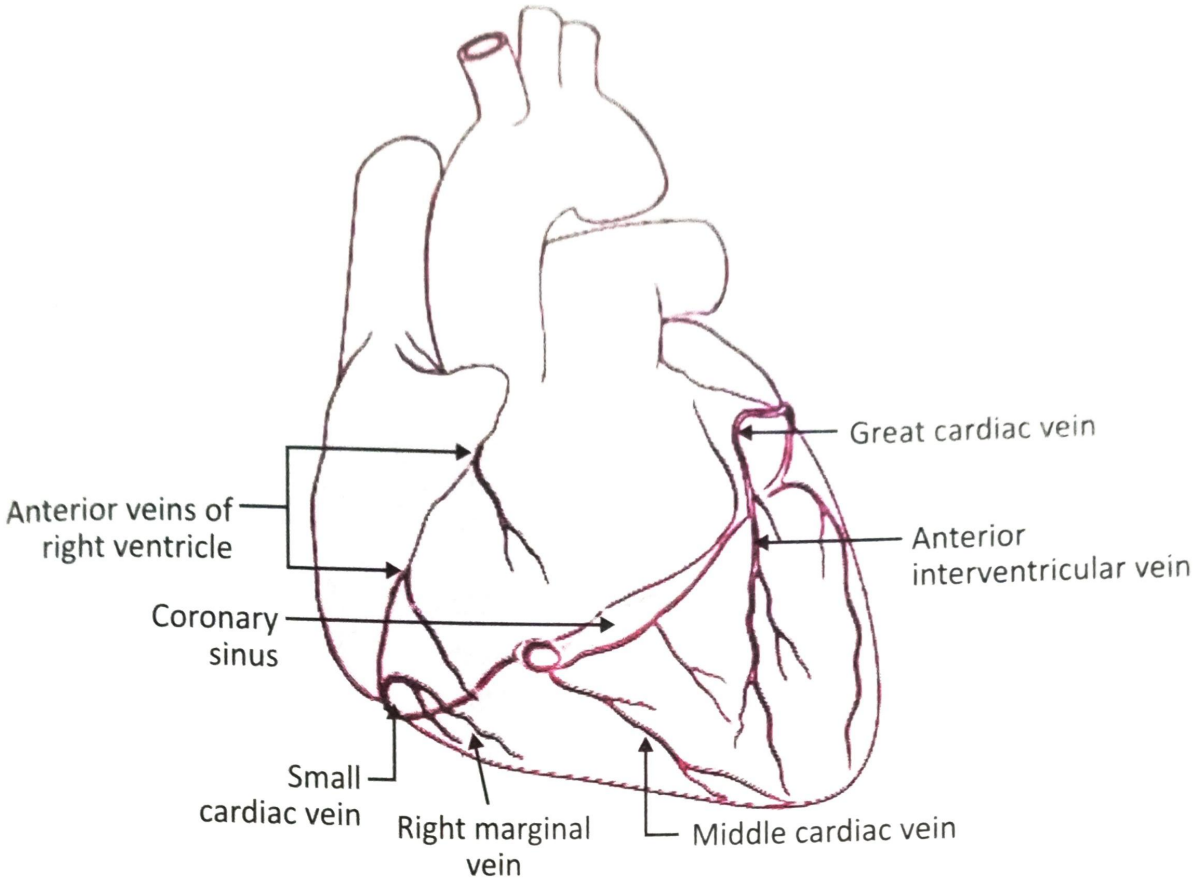

Fig. 7.16: ***Coronary Circulation***

Pulmonary Circulation or Lesser Circulation

(Heart to lungs and again back to heart)

1. The circulation of blood between heart and lungs is known as Pulmonary circulation. From the right ventricle of heart deoxygenated blood goes to lungs and back to the left atrium. In lungs CO_2 is excreated and O_2 is absorbed in blood

Right ventricle (impure or deoxygenated blood)

↓

Right and left Pulmonary artery (impure blood)
(Artery to Arterioles to Pulmonary capillaries)

↓

Lungs
(Exchanges of gases between Pulmonary capillaries and alveoli which contain oxygen)

↓

Pulmonary capillaries unite to form venules, venules join to form Pulmonary veins

↓

Right and left Pulmonary veins (pure or oxygenated blood)

↓

Left atrium (Heart)

2. The deoxygenated blood from the right ventricle is forced into pulmonary arteries. The left pulmonary artery carrying deoxygenated blood to left lung, the pulmonary artery carrying deoxygenated blood to right lungs.
3. In the lungs, Pulmonary arteries divided and subdivided into smaller arteries, arterioles and Pulmonary capillaries. (Arteries into small arteries, small arteries into arterioles, arterioles into capillaries.) Pulmonary capillaries are semipermeable.
4. These Pulmonary capillaries surrounds the alveoli of the lungs which contain oxygen.
5. Exchange of gases takes place between Pulmonary capillaries and the alveoli of the lungs. Thus oxygen from alveoli enters into pulmonary capillaries and deoxygenated blood becomes oxygenated.
6. The pulmonary capillaries unite to form venules, venules unite to form Pulmonary veins which opens into left atrium. Then this passes to left ventricle which contracts and pumps blood into the aorta to begin systemic circulation.
7. It is called lesser circulation because pulmonary arterial pressure is low.

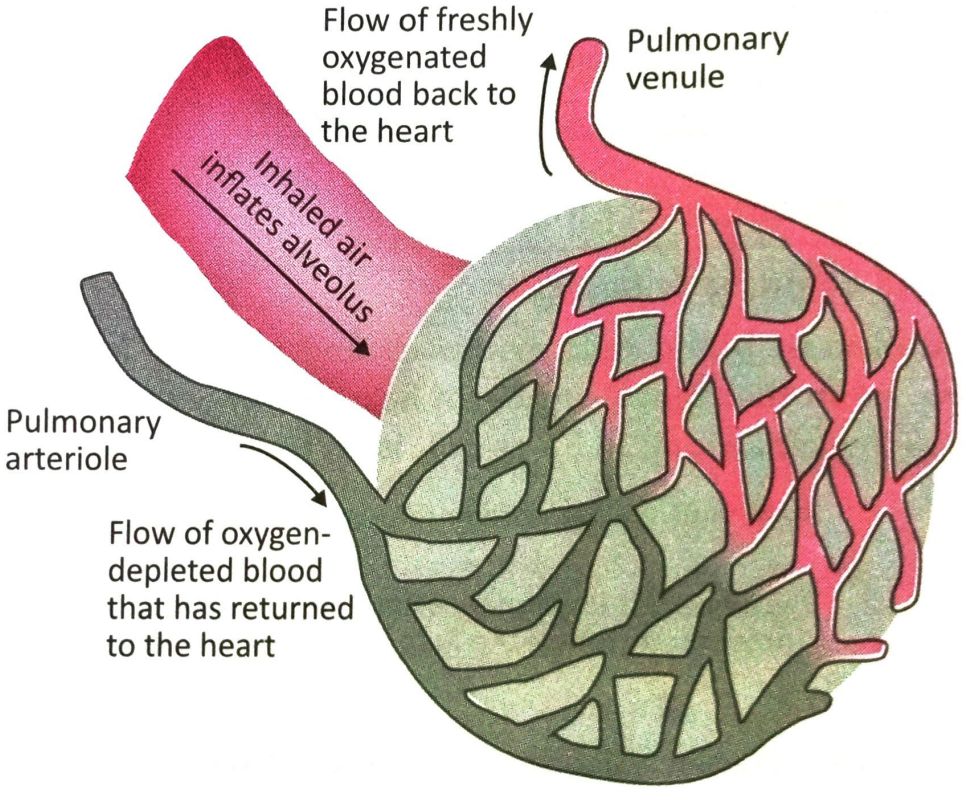

A capillary network covers the surface of the alveolus to facilitate oxygen and carbon dioxide exchange

Fig. 7.17: *Alveoli with Pulmonary Capillaries*

Systemic Circulation or Double or Greater Circulation

(Heart/Aorta to body tissues and again to heart)

1. The circulation of oxygenated blood from heart to the all parts of the body and deoxygenated blood from all parts of the body to the heart is known as systemic circulation.
2. The oxygenated blood from the left ventricle of the heart is forced into aorta. The aorta divides and redivides into arteries, arterioles and finally (aortic) capillaries which carry pureor oxygenated blood to different tissues of the body.
3. The aortic capillaries are semipermeable (thin walled) so oxygen from the capillaries is passes to the tissue fluid and collect the waste material from them.
4. These capillaries unites to form venules. Different venules unite to form veins.
5. These veins unite to form big veins called superior and inferior vena cavae. Superior vena cava carries impure blood (deoxygenated blood) from upper parts of the body whereas Inferior vena cava carries impure blood (deoxygenated blood) from lower parts of the body. Both these veins pour impure blood into right atrium of the heart.
5. It is also called double circulation as blood has to pass two times through heart.
6. Thus in systemic circulation, oxygen and nutrients are carried to tissue and cells. It is also called greater circulation because heart provides maximum amount of blood to the all organs of the body so systemic arterial pressure is more.

Left ventricle → Aorta → Arteries, arterioles, capillaries → Tissue
↓
Right atrium ← Superior & Inferior Venae cava ← Veins ← Venules ← Capillaries ← Body cells

Portal Circulation

(Digestive organs to Liver to Heart)

1. The circulation of nutrients rich blood from digestive organs to the liver and then to the heart is known as Portal Circulation.
2. The portal vein collects blood and nutrients from the digestive organs such as stomach, small intestine, large intestine, spleen, gallbladder. The portal vein is formed by joining the veins together such as:
   (a) Gastric vein from stomach
   (b) Superior mesenteric vein from the small intestine
   (c) Inferior mesenteric vein from large intestine (rectum and colon)

(d) Splenic vein from spleen

(e) Cystic vein from gall bladder

3. Portal vein carries all its blood and nutrients to the liver first
4. Liver is supplied with hepatic artery which carries oxygenated blood to liver. Hepatic artery and Portal vein mix their contents in liver
5. From Liver, hepatic vein arise and pour its contents that is deoxygenated blood with nutrients into the inferior vena cava to right atrium of the heart

Significance of Portal Circulation

1. In Portal circulation, nutrients rich blood enters into the Liver then goes to the heart.
2. Liver stores some of the nutrients and modifies (changes) some nutrients as per the need of body. For example, Liver converts (modify) glucose into glycogen for storage.
3. Liver detoxify harmful substances that have been absorbed from G.I.T. and remove toxins from the blood
4. Thus portal circulation maintains and regulates nutrient materials and then pass to the all parts of the body through the heart.

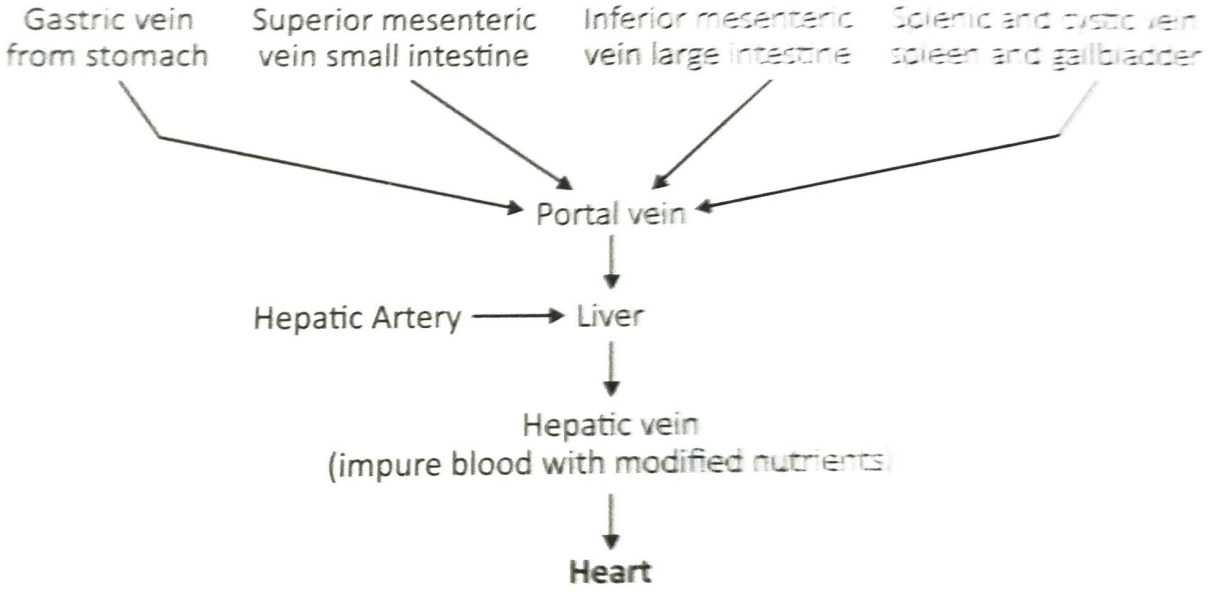

Fig. 7.18: ***Portal Circulation Outline***

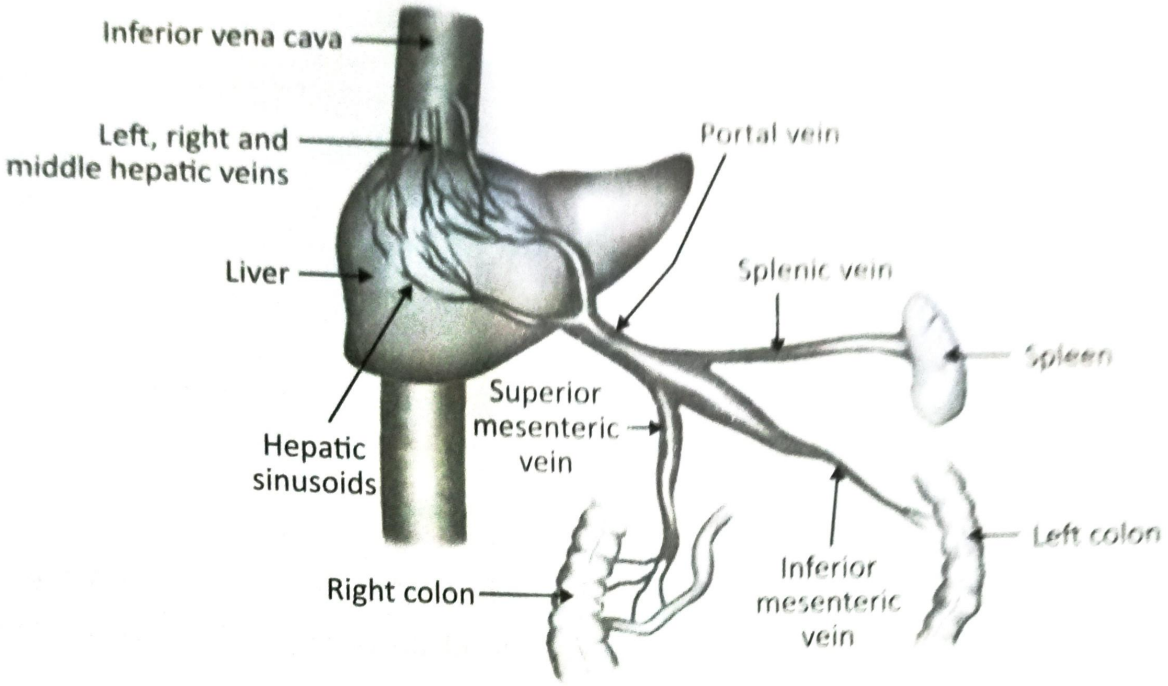

Fig. 7.19: *Portal Circulation*

Table 7.4: Blood Circulations of the Body

Pulmonary circulation	Systemic/General circulation	Portal circulation
Right ventricle (deoxy. blood) ↓ Pulmonary artery ↓ Lungs ↓ Arteries, arterioles, capillaries between capillaries and alveoli, exchange of gases O_2 and CO_2 takes place. Blood becomes oxygenated ↓ Capillaries unite to form veules then veules unite to form Pulmonary veins (oxy blood) ↓ Left atrium	Left atrium ↓ Left ventricle (oxy blood) ↓ Aorta → arteries ↓ capillaries ← arterioles ↓ Betwen capillaries & tissues exchange of gases O_2 and CO_2 takes place. Blood becomes deoxygenated ↓ oxy blood goes to the tissues and from tissue CO_2 come into blood ↓ deoxy blood into veins ↓ Superior and inferior venae cavae ↓ Right atrium	1. Gastric vein (stomach) 2. Superior mesenteric vein (small intestine) 3. Inferior mescentric vein (rectum.colon) 4. Cystic vein (gall bladder) 5. Splenic vein (spleen) ↓ Portal vein (deoxy blood and Nutrients) ↓ Liver ← Hepatic artery (oxy blood) ↓ Modification of nutrients & Hepatic vein (Nutrient rich blood) ↓ Inferior vena cava Heart

DISORDERS OF THE BLOOD VESSELS

1. **Arteriosclerosis:** There may be a patchy, fatty degeneration inside the arte
2. **Arteritis:** Inflammation of arteries (redness, swelling, pain)
3. **Aneurysms:** Dilatation of arteries
4. **Varicose vein:** In this, veins are so dilated that valves do not close to pre backward flow of blood. Such veins lose their elasticity and become elonga
5. **Haemorrhoids:** Sustained pressure on the veins at the junction of rectum anus. So valves do not works and bleeding during stools called piles.

DISORDERS OF THE HEART

1. **Angina Pectoris:** Chest pain or pain in the heart due lack (less) of oxygen supp
2. **Ischaemic Heart Disease (IHD):** Less blood and oxygen supply to the he tissue. It occurs due to atheroscleriosis.
3. **Myocardial Infarction (MI):** Dead tissue in myocardium due to lack of blo and oxygen supply. (Infarct-dead tissue)
4. **Hypertension:** Increase in Blood Pressure above normal range

   Primary hypertension: Cause is not known

   Secondary hypertension: Kidney disease, increases adrenaline & aldostero level.
5. **Cardiac Arrhythmias:** It is the irregularities in heart beat due to abnorm impulse generation in heart.
6. **Congestive Cardiac Failure (CCF):** It is the inability of the heart to pum sufficient blood
7. **Stenosis:** Hardening and narrowing of valves of heart.
8. **Incompetence:** Functional defect of valves do not close completely.
9. **Congenital Heart Disease:** Abnormalities occurs in the heart at birth due error in the development of the intrauterine growth.
10. **Shock:** Shock is a failure of the cardiovascular system to deliver enough oxyg and nutrients to meet cellular metabolic needs. Shock can be of 4 types

    (i) **Hypovolemic Shock:** Occur due to decreased blood volume.

    (ii) **Cardiogenic Shock:** Occur due to poor heart function.

    (iii) **Vascular Shock:** Due to inappropriate vasodilatation.

    (iv) **Obstructive Shock:** Due to obstruction of blood flow.

    (v) **Septic Shock:** Due to microbial infection.

    (vi) **Anaphylatic Shock:** Due to allergic rea illin

IMPORTANT QUESTIONS

1. Describe internal structure of Heart. (S-96, 00, 01, 02; W-01)
2. How circulation of blood takes place through heart? (S-97; W-96)
3. Describe valves of the heart and their function. (S-98)
4. Draw and label the various parts of Heart. (S-99)
5. Describe in brief the Cardiac cycle. (S-97, 01, 02, 03; W-96, 99, 00, 01)
6. Discuss Pulmonary circulation. (S-00, 03; W-00)
7. Describe in short systemic circulation. (W-01)
8. What is Portal circulation? Give its importance. (S-96; W-02)
9. Name the arteries supplying blood to liver, kidney and heart. (S-00)
10. Name the different arteries arising out of abdominal aorta. (S-99)
11. What is blood pressure? How is it recorded? Define blood pressure mention how is it recorded? (S-02, 03; W-96, 97, 98, 00)
12. What are the structural differences between artery and veins. (S-96, 99, 00, 02; W-98, 99)
13. What is blood pressure? Name factors influencing it. (S-97, 99, 03)
14. Give in brief the three disorders of Heart. (W-96, 97)
15. Discuss angina pectoris. (S-00, 02, 03; W-00)
16. Write a note on coronary thrombosis. (S-00, 01)
17. Define Myocardial Infarction. (S-03)
18. What is stenosis? (W-97)
19. Describe the terms haemorrhoides and arterio sclerosis. (S-97)
20. Define Hypertension (S-03)

CHAPTER 8

Respiratory System

INTRODUCTION

The respiratory and circulatory systems work together to supply O_2 and remove CO_2.

The respiratory system provides gas exchange that is intake of O_2 and excretion CO_2 where as cardiovascular system transports blood containing gases (O_2 and CO_2

DEFINITION

Respiration is the process that involes exchange of gases (O_2 and CO_2) between atmosphere lungs, blood and tissues.

FUNCTIONS OF RESPIRATORY SYSTEM

1. Respiration means gas exchange – intake of O_2 and excreation of CO_2
2. Sensation of smell
3. Filteration of inspired air
4. production of sound
5. Regulation of blood pH

STAGES OF RESPIRATION

Respiration involes two stages:

1. **External Respiration:** Exchange of gases between atmosphere and lun lungs takes O_2 from atmosphere and gives out CO_2

2. **Internal Respiration:** Exchange of gases between blood and tissues that is tissues takes O_2 from blood and gives out CO_2.

ORGANS OF RESPIRATORY SYSTEM

1. Nose
2. Pharynx (throat)
3. Larynx (voice box)
4. Trachea (wind pipe)
5. Two Bronchi
6. Bronchioles
7. Alveoli
8. Two lungs
9. Muscles of respiration – intercostals muscles and diaphragm.

1. Respiratory passage (conducting organs) passes air to the lungs and respiratory organs are responsible for respiration means gas exchange.

   Nose → Pharynx → Larynx → Trachea → bronchi → Bronchioles → Alveoli → Lungs
   (Thorat) (Voice box) (Wind pipe)

2. Respiratory organs are alveoli, lungs exchange of gases takes place.

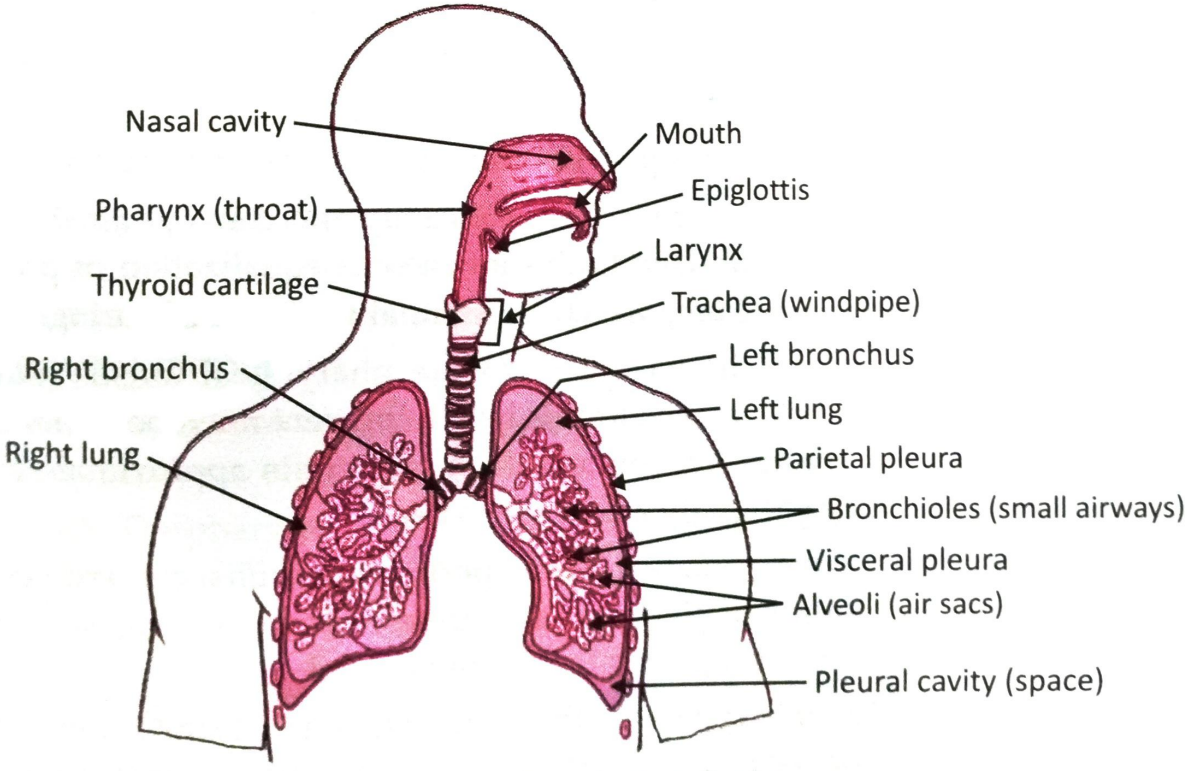

Fig. 8.1: *Respiratory System*

1. NOSE

The nose is the first respiratory passage through which incoming air passes. It consists of a large irregular cavity divided into 2 equal chambers by a septum. These nasal chambers consist of ciliated columnar epithelium cells. It contains goblet cells that secreate mucus (sticky substance) and moisture.

Functions of Nose

1. Mucus of nasal chambers makes the surface sticky for trapping dust particles and causes filtration of inspired air.
2. Moisture of nasal chamber causes humidification of air (wet air).
3. Nose warms the air means nose brings temperature of the incoming air upto body temperature.
4. Nose is a organ of sense of smell.

2. PHARYNX (THROAT)

The pharynx or throat is a funnel shaped tube about 13 cm long. It lies behind the nose, mouth, larynx.

Pharynx is divided into three anatomical regions:

1. Nasopharynx
2. Oropharynx
3. Laryngopharynx/hypopharynx

1. **Nasopharynx:** It is a superior (upper) portion and lies behind the nasal cavity.

   The nasopharynx receives air from the nasal cavity and conveys air through the auditory tubes to middle ear. Due to this air there is equalization of pressure at tympanic membrane (ear drum) which is essential for proper hearing.

   On the posterior wall of the nasopharynx are pharyngeal tonsils (adenoids) consisting of lymphoid tissue. The tonsils help to prevent microbes from entering into the body. They are most prominent in children upto approximately 7 years of age. Thereafter they gradually atrophy or lossed.
2. **Oropharynx:** It is the intermediate (middle) portion of the Pharynx and lies behind the oral cavity, this portion of pharynx has both respiratory and digestive function because it is a common passageway for air, food, drink.
3. **Laryngopharynx/Hypopharynx:** It is the inferior (lower) portion of the pharynx. It opens into the esophagus (food tube). Laryngopharynx is both a respiratory and digestive pathway.

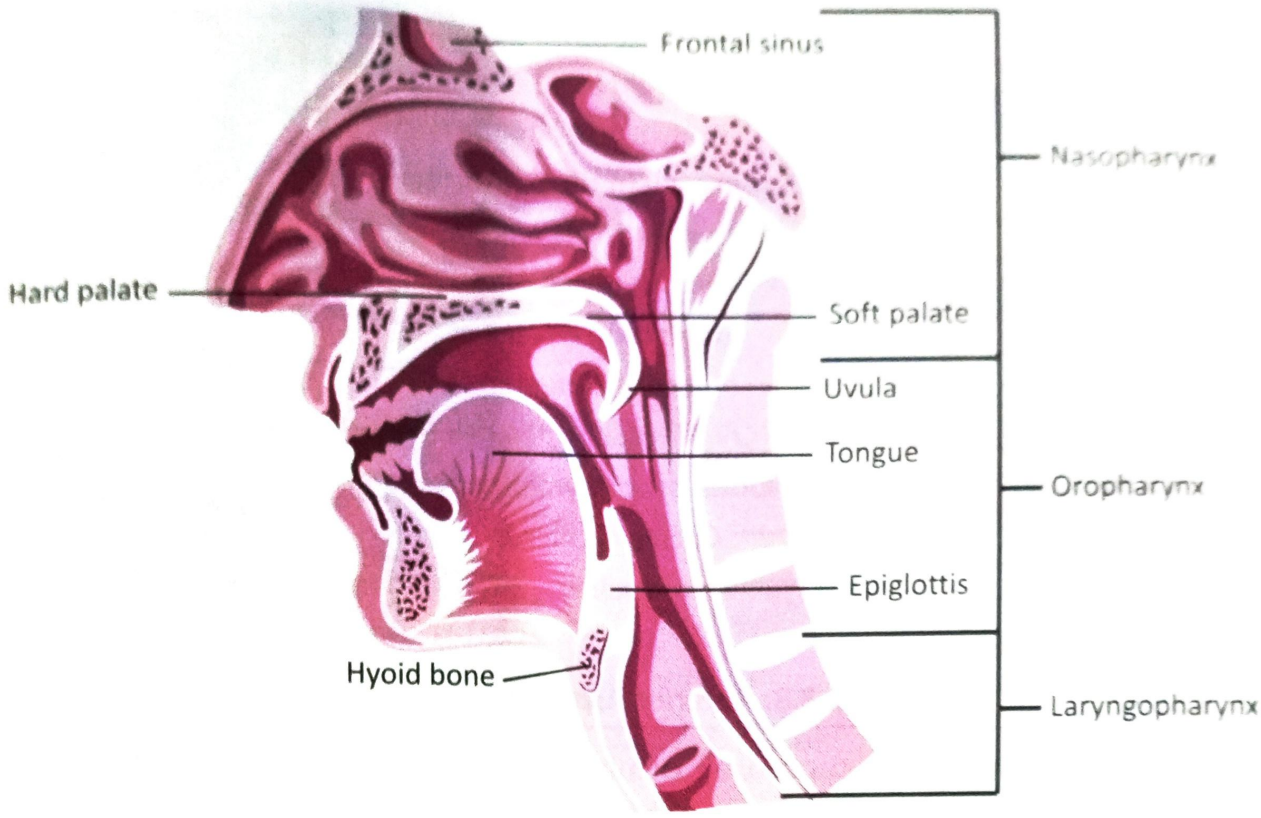

Fig. 8.2: *Pharynx*

Functions of Pharynx

1. **Respiratory and digestive function:** Pharynx passes food and air into the body.
2. Warming and humidifying the air.
3. **Taste:** oropharynx responsible for taste as it contains sensory nerve ending for taste.
4. **Hearing:** Nasopharynx conveys air through the auditory tubes to middle ear. This air maintains the pressure at the tympanic membrane. Satisfactory hearing depends upon the presence of air at atmosphereic pressure on each side of the tympanic membrane.
5. **Protection against microbes:** Lymphatic tissue of the pharyngeal and laryngeal tonsils produces antibodies in response to antigens or microbes.
6. **Speech:** The pharynx works for speech functions in speech by acting as a resonating chamber for sound.

3. LARYNX (VOICE BOX)

Larynx (voice box) is a passageway that lies below pharynx and connects the pharynx with the trachea. It is present in the midline of the neck.

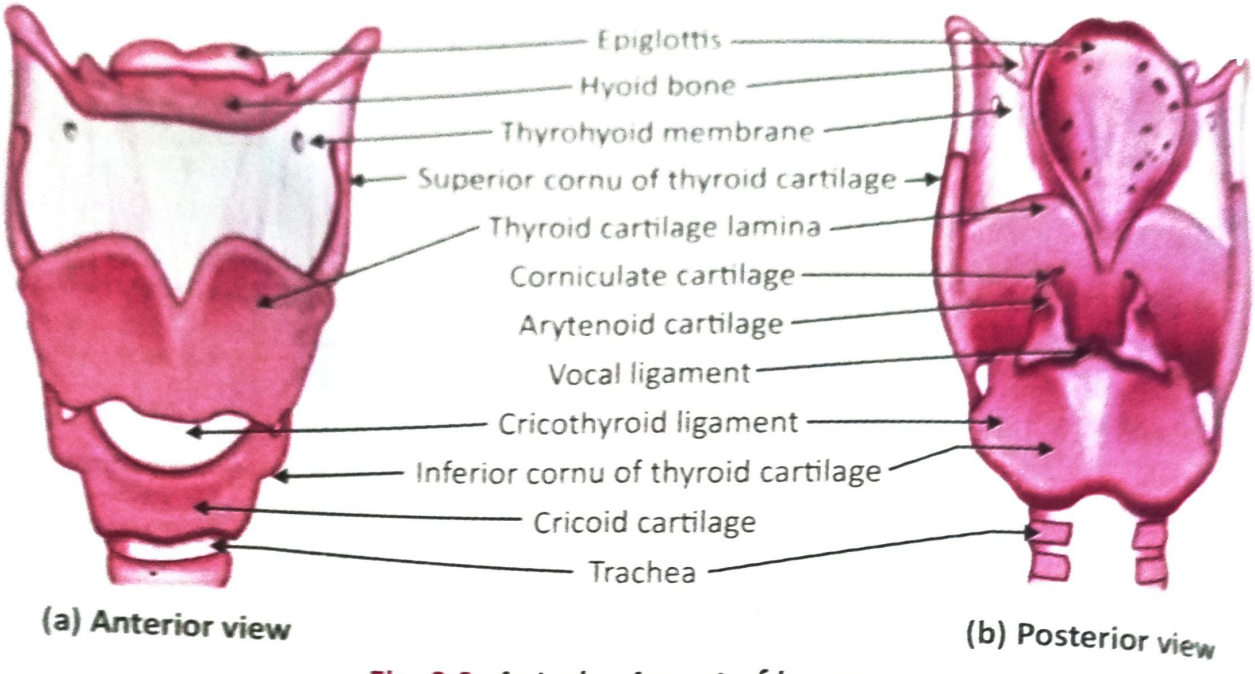

Fig. 8.3: ***Anterior Aspect of Larynx***

The wall of the larynx is composed of nine pieces of cartilages (connective tiss three occurs in singly and three occurs in pairs.

1. 1 Thyroid cartilage
2. 1 cricoid cartilage
3. 1 epiglottis cartilage

Occurs in singly

4. 2 arytenoid cartilages
5. 2 corniculate cartilages
6. 2 cuneiform cartilages

Occur in pairs

1. **Thyroid Cartilage** (Adam's apple) consists of two fused plates of hyaline cartil which is usually larger in males than in females due to the male sex hormo during puberty. It forms a v shaped notch known as thyroid notch.
2. **The Cricoid Cartilage:** This lies below the thyroid cartilage and is also compos of hyaline cartilage. Its shape is like a signet ring, completely encircling the larn
3. **Epiglottis Cartilage:** It is a single leaf shaped cartilage which present on the of larynx.

   If larynx is to be a box then the epiglottis acts as a lid, it closes off the larn during swallowing and food, liquid enters into the esophagus. Thus epiglo causes entry of food into esophagus not in trachea.
4. **Arytenoid Cartilages:** These are triangular shaped pieces of mostly hyali cartilages located at the posterior (back) side of larynx. They attach to the vo cords and pharyngeal muscles.
5. **Corniculate Cartilages** which are horn shaped pieces of elastic cartilages located at the apex of each arytenoids cartilage.

6. **Cuneiform Cartilages** are rod shaped elastic cartilages that connect epiglottis to arytenoids cartilages.

The vocal cords lie inside the larynx which causes sound production.

When air is forced through the larynx, it causes vibration of vocal cords and sound is produced. The pitch of sound is determined by the tension on the vocal cords—greater the tension, higher the pitch.

Functions of Larynx

1. **Production of Sound:** Vocal cords produce sound of varying loudness and pitch
2. **Speech:** Vocal cords produce sound and are manipulated by tongue, cheeks and lips.
3. **Protection of lower respiratory tract:** During swallowing, larynx moves upwards closes the opening into it from the larynx. This ensures that food enters into the esophagus (digestive system) and not into the lower respiratory passages.
4. **Passageway for air:** It provides a passage for air between the pharynx and the trachea.
5. **Humidifying, filtering and warming air:** During the passage, the air is further moistened, filtered and warmed.

4. TRACHEA (WIND PIPE)

Trachea or wind pipe is continuation of the larynx. It divides (bifurcates) at the crania into right and left primary bronchi (bronchus-singular). Trachea is about 12 cm long and 2.5 cm in diameter. It lies in front of the esophagus (Digestive organ).

Structures

1. **Trachea** is composed of 16-20 incomplete 'C' shaped rings of hyaline cartilage lying one above the other.
2. **Trachea consists of three layers of tissues or covering:**
   (a) Outer covering is fibrous and elastic tissues (connective tissue).
   (b) Middle layer consists of areolar connective tissues with cartilage.
   (c) Inner layer consists of ciliated columnar epithelial cells containing mucus secreting goblet cells.

Functions of Trachea

1. **Free Passage of Air:** Trachea remains open permanently allowing free passage of air from atmosphere to alveoli of lungs.

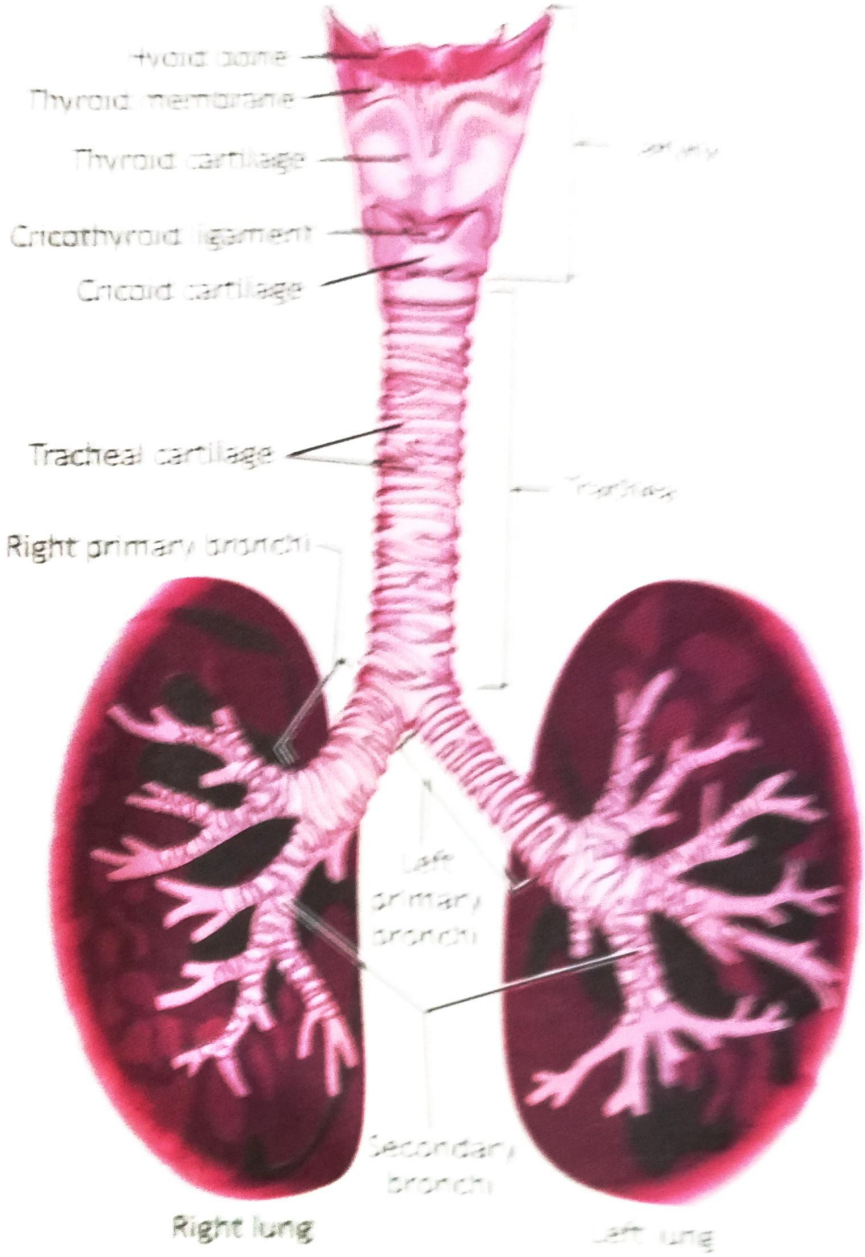

Fig. 8.4: *Anterior view of Larynx, Trachea and Bronchi*

2. **Mucociliary function:** Inner layer of trachea consists of ciliated and epithelial cells containing mucus secreting goblet cells. This mucus is sticky to trap dust and bacteria. The cilia (hair like projections of ciliated columnar epithelial cells) pushes/wafts the trapped particles towards the larynx where it is swallowed or coughed up.
3. Trachea is also responsible for **cough reflex.** Vagus nerves conduct nerve impulse when there is a irritation to the trachea. These nerve impulse passes respiratory centre in brain stem.So respiratory muscles contract and suddenly release with mucus or with foreign material from mouth.
4. **Warming, humidifying and filtering of air.**

Trachea divides at fifth thoracic vertebra into a right primary bronchus which goes to the right lung and left primary bronchus which goes to the left lung.

also contain incomplete rings of hyaline cartilage. These are lined by Pseudo stratified ciliated columnar epithelium.

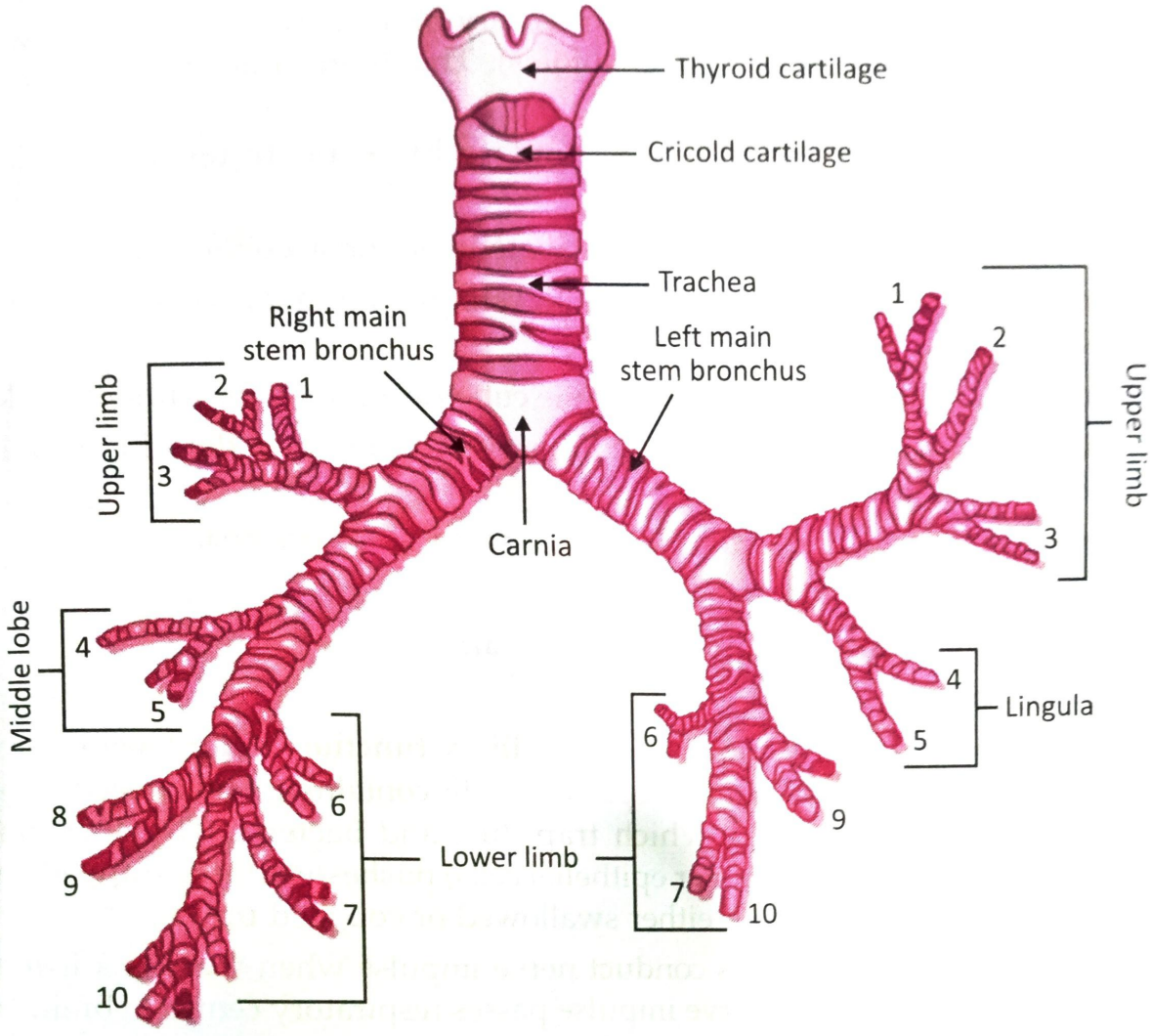

Fig. 8.5: ***Bronchopulmonary Tree***

Right Primary Bronchus	Left Primary Bronchus
1. It is wider, shorter and more vertical than left bronchus as a result an aspirated object is more likely to enter and lodge in the right bronchus.	1. It is narrower than the right bronchus
2. It is 2.5 cm in length	2. It is about 5 cm long
3. Right bronchus immediately after entering in the right lung divides into 3 branches. Each branch then divides into smaller branches.	3. Left bronchus after entering into left lung divides into 2 branches. Each branch then subdivides into many branches.

6. BRONCHIOLES

On entering the lungs, the primary bronchi divide into branches called secondary bro The secondary bronchi further divide into tertiary bronchi andtertiary bronchi d into terminal bronchioles (smaller bronchioles). This branching pattern is know bronchial tree.

Branches to primary bronchus to Secondary bronchus to tertiary bronchi terminal bronchioles:

1. **Primary bronchi:** Pseudo stratified ciliated columnar epithelium.
2. **Secondary and tertiary bronchi:** Ciliated simple columnar epithelium with goblet cells.
3. **Terminal (smaller) bronchioles:** Simple cuboidal epithelium without goblet

Bronchial tree consists of the trachea, primary bronchi, secondary bronchi, ter bronchi and terminal bronchioles.

Functions of bronchi and bronchioles are same as of trachea:

1. **Control of air entry**
2. **Warming, humidifying and filtering of air**
3. **Support and patency**
4. **Removal of particulate matter or Mucociliary function:** Inner layer of bronc tree consists of ciliated columnar epithelial cells containing mucus secreting go cells. This mucus is sticky which trap dust and bacteria. The cilia (hair projections of ciliated columnar epithelial cells) pushes/wafts the trapped part towards the larynx where it either swallowed or coughed up.
5. **Cough reflex:** Vagus nerves conduct nerve impulse when there is a irritation the bronchial tree. These nerve impulse passes respiratory centre in brain stem respiratory muscles contract and suddenly releases air with mucus or with for material from mouth.

7. ALVEOLI

1. Terminal bronchioles divides into microscopic branches called respira bronchioles.
2. Respiratory bronchioles in turn divides into several (2-11) alveolar duct, i.e. tube like structure which lead to expanded passages called alveoli (plural-alveo
3. The membrane of the alveoli is very thin, semipermeable and richly supplied blood vessels, i.e., is alveoli surrounded with blood capillaries so exchange of g takes place easily.

Functions of Alveoli

Alveoli causes exchange of gases means alveoli gives oxygen to blood capillaries and to carbon dioxide from blood capillaries for exhalation. Thus, alveoli are the main sites wh actual diffusion of gases O_2 and CO_2 takes place between blood and atmospheric air.

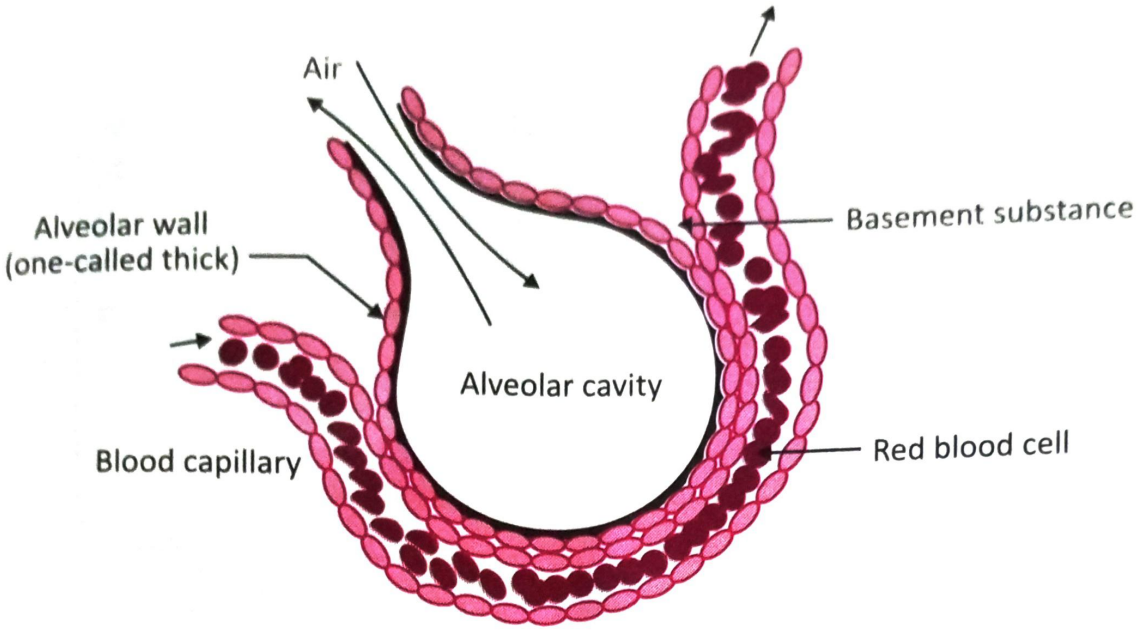

Fig. 8.6: ***Section of an Alveollus with Pulmonary Capillary***

LUNGS

1. **Lungs** (light weight, because they float) are paired or two in number. They are cone shaped organs that lie in the thoracic cavity.
2. **Membranes/covering of the lungs:** Each lung covered with 2 membranes (covering) known as pleura or pleural membrane. The pleura is divided into 2 layers:
   - **(a) Parietal pleura:** (Outer covering) is in close contact with thoracic cavity.
   - **(b) Visceral pleura:** (Inner covering) is in close contact with lung.

   In between Parietal and Viscera these two pleural membranes, a narrow space is present known as pleural cavity which contains a small amount of lubricating fluid secreated by epithelial cells of the membrane. This pleural fluide reduces friction of two pleurae allowing them to slide easily over one another during breathing.
3. **Internal structure of the lungs:** Lung consists of 4 regions:
   - **(a) The apex:** Narrow upper (superior) portion of lung
   - **(b) The base:** Broad lower (inferior) portion of the lung.
   - **(c) Coastal surface:** Pheripheral surface of lung lying against the rib.
   - **(d) Medial surface:** This middle surface is concave and has roughly triangular area. Medial (mediastinal) surface of each lung contains a region called hilum through which bronchi, pulmonary blood vessels, Lymphatic vessels and nerves enter and exit.

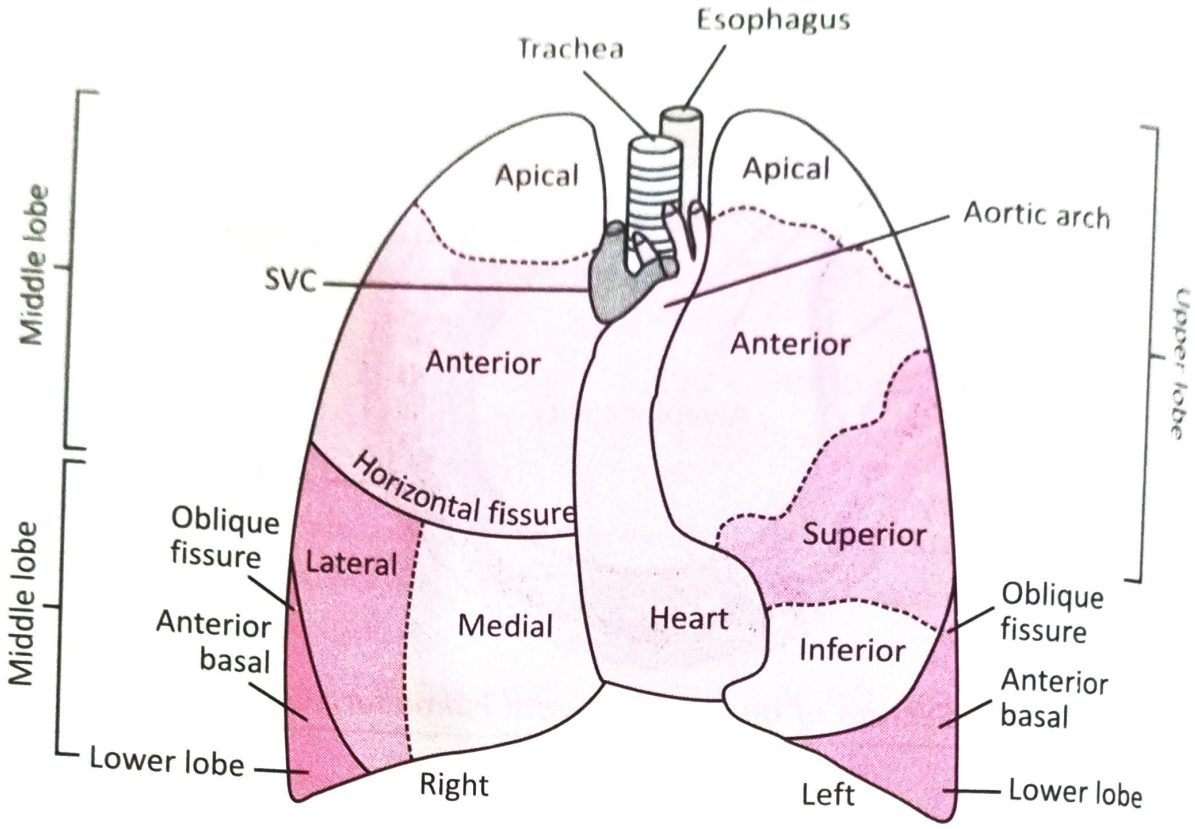

Fig. 8.7: *Lungs*

The surface between of the two lungs is called mediastinum which is occupied heart. Due to space occupied by heart, the left lung is about 10% smaller than right lung.

Right lung is divided into 3 lobes and left lung is divided into 2 lobes.

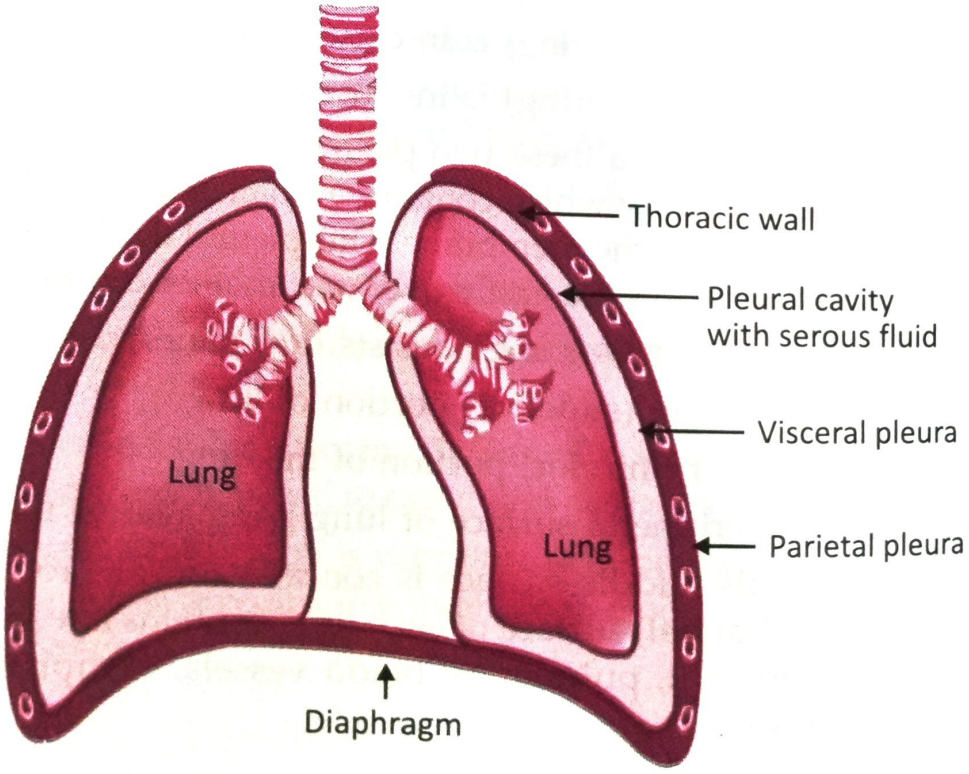

Fig. 8.8: *Membranes of Lungs*

Role of Thoracic Cage in Respiration

Lungs lie in an air tight chamber known as thoracic cavity or thoracic cage or chest cavity. It is formed posteriorly by the vertebral column, ventrally by sternum, laterally by ribs. It is closed below by the diaphragm which a dome is shaped structure made up of muscles. It separates thoracic and abdominal cavity. It consists of Central Tendon from which muscles arises and attached to lower ribs and sternum. Between the ribs 11 pairs if inter-costal muscles are present.

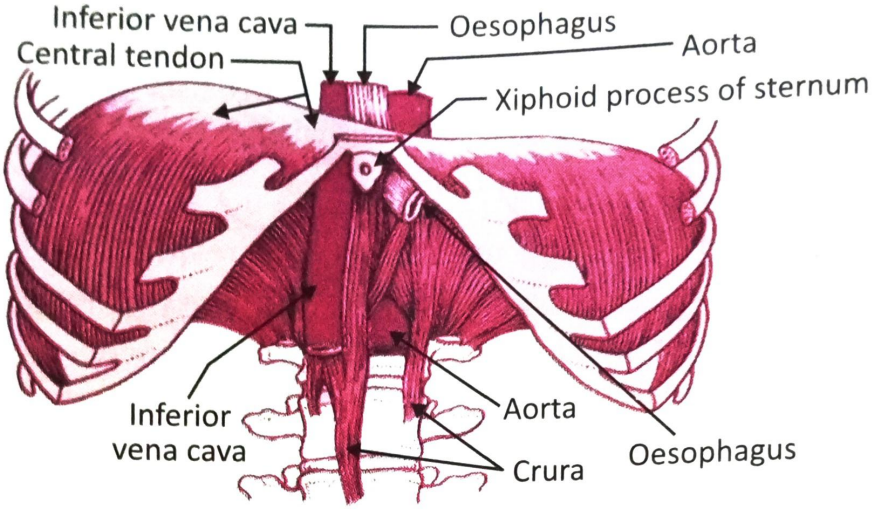

Fig. 8.9: ***Central Tendon***

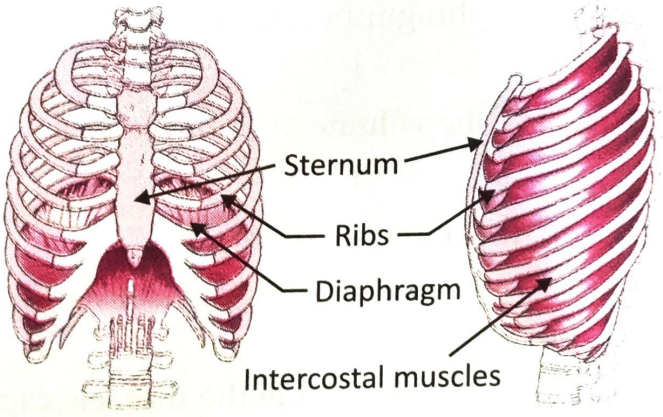

Fig. 8.10: ***Intercoastal Muscles***

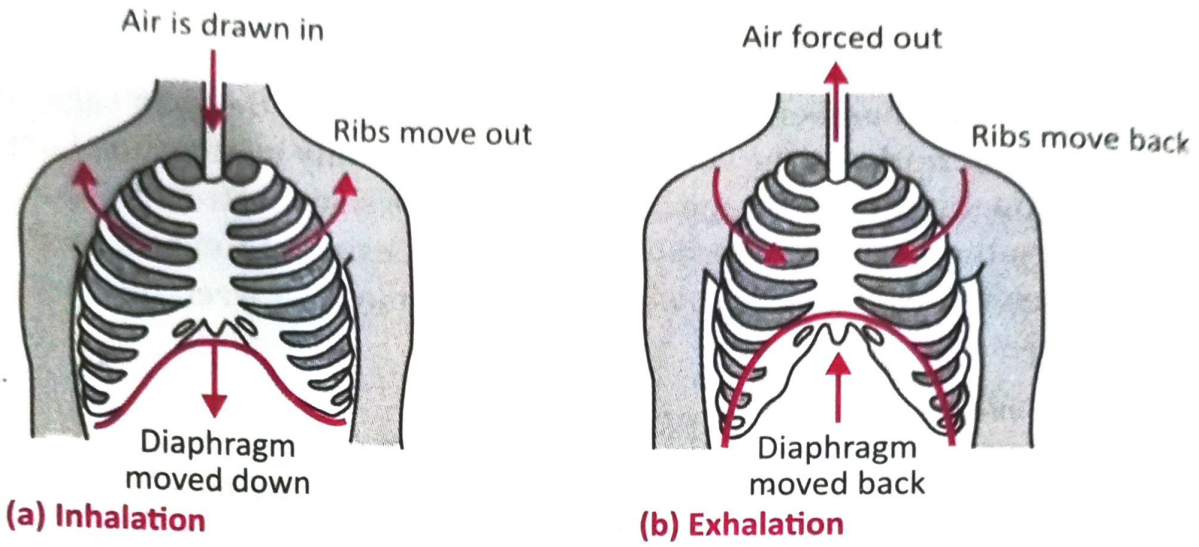

Fig. 8.11: *Thoracic Cage*

Thoracic cage works in following manner during respiration:

1. During insiration, the inter coastal muscles of ribs and diaphragm contract. The diaphragm become flat and lowered down there by increasing the volume of thoracic cage and decreases pressure inside it. It helps in expandation of lungs, air from atmosphere enters into lung.

Inter coastal muscles of ribs and diaphragm of thoracic cage contracts

↓

Diaphragm become flat

↓

Increasing the volume of thoracic cage

↓

Expandation of lungs

↓

↓

Decreases the pressure inside the thoracic cage

↓

Air from atmosphere enters into lung

↓

Inspiration takes place

2. During expiration, the inter coastal muscles of ribs and diaphragm relax. The diaphragm become dome shaped means come to normal position thereby decreasing the volume of thoracic cage. Elastic recoil of lungs. So exhalation of air from lungs to atmosphere.

Inter coastal muscles of ribs and diaphragm of thoracic cage relax

↓

Diaphragm become dome shaped means come to normal position

↓

Decreasing the volume of thoracic cage

↓

Elastic recoil of lungs

↓

Increases the pressure inside the thoracic cage

↓

Air from lungs enters into atmosphere

↓

Expiration takes place

MECHANISM OF RESPIRATION OR PHYSIOLOGY OF RESPIRATION

The term respiration means the exchange of gases that means supply of oxygen to the cells and removal of carbon dioxide from the the body.

It occurs in three basic steps:

1. Breathing or pulmonary ventilation
2. External respiration
3. Internal respiration

Breathing or Pulmonary Ventilation

1. Breathing is the movement of air into (inhalation) lungs and out of lungs (exhalation).

   The average breathing rate is 12 to 15 breathes per minute

   Each breath consists of three phases:

   (a) Inspiration or inhalation

   (b) Expiration or exhalation

   (c) Pause

Inspiration or Inhalation	Expiration or Exhalation
Inhalation occurs when alveolar pressure less than atmospheric pressure.	Exhalation occurs when alveolar pressure higher than atmospheric pressure.
Inspiration starts due to contraction of the diaphragm and intercoastal muscles	Expiration starts due to relaxationof the diaphragm and external intercoastal muscles
Increases the size of the thoracic cavity, results in increase in lung volume (space)	Decreases the size of the thoracic cavity, results in decrease in lung volume (space)
This increase in lung volume (space) causing rushing (passing) of atmospheric air into the lungs and finally to alveoli.	This decrease in lung volume (space) causes passing of inside air to out of the lungs
The process of inspiration is active as it needs energy for muscle contraction. Inspiration lasts for about 2 seconds	This process is passive as it does not require the expenditure of energy. At rest, expiration lasts for about 3 second

Pause: After expiration there is a pause before the next cycle begins.

External Respiration

1. External respiration involves exchange of gases between alveoli and pulmonary capillaries of lungs. In this process, oxygen of alveoli goes to blood of pulmonary capillaries. In this process, pulmonary capillaries gains O_2 and blood becomes oxygenated.

   Air of Alveoli of Lungs $\longrightarrow$ O_2 blood of Pulmonary capillaries in Lungs

   CO_2 $\longleftarrow$

2. Air which is inhaled finally reach to alveoli and come incontact with Pulmonary capillaries.
   (a) The partial pressure of oxygen that is PO_2 of alveolar air is 105 mmHg
   (b) The partial pressure that is PO_2 of deoxygenated blood passing through pulmonary capillaries is about 40 mmHg.
3. Due to this pressure difference, there is net diffusion or transfer of O_2 from alveoli into deoxygenated blood in capillaries until equilibrium is reached.

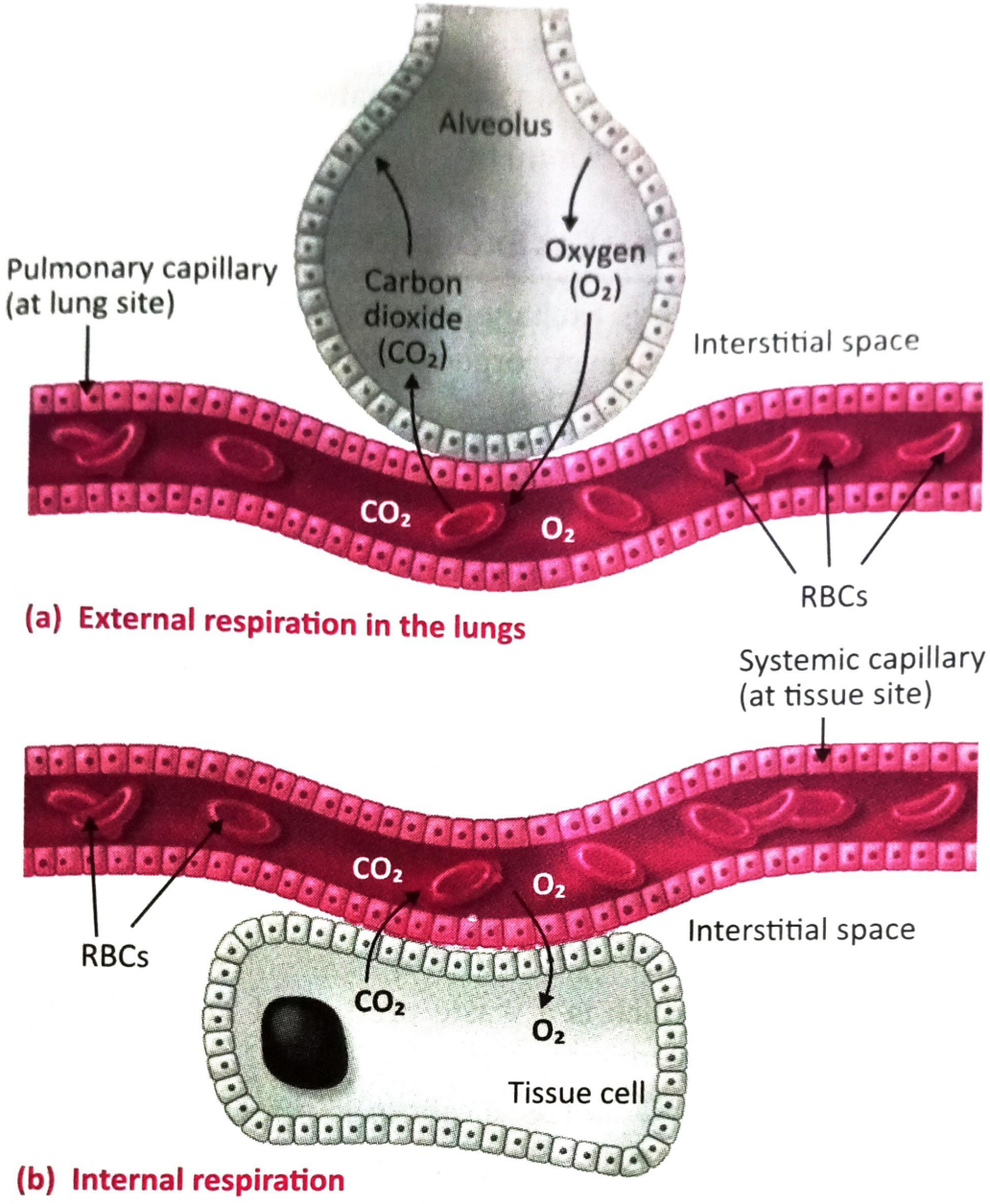

Fig. 8.12: *Respiration*

Alveoli	$\xrightarrow{O_2}$	Pulmonary capillaries
PO_2 of air		PO_2 of Deoxygenated blood
105 mmHg		is 40 mmHg

Now deoxygenated blood is converted into oxygenated blood. It is then carried to the heart and is pumped for circulation to all parts of the body.

4. Simultaneously CO_2 which is a waste product of metabolism passes or diffuse from blood of pulmonary capillaries to the alveoli.
   (a) Partial pressure of CO_2 in deoxygenated blood in pulmonary capillaries is 45 mmHg
   (b) Partial pressure of CO_2 in air in alveoli is 40 mmHg. Because of this difference in pressure, CO_2 diffuses from pulmonary capillaries to the alveoli

(c) Alveoli $\xleftarrow{CO_2}$ Pulmonary capillaries

PCO_2 of air 40 mmHg — PCO_2 of Deoxygenated blood is 45 mmHg

Internal Respiration or Systemic Gas Exchange

1. Internal respiration involves exchange of gases between blood of systemic (A capillaries and tissue cells of every organ of body. In this process, oxygen of sys capillaries goes to cells.

Systemic (aortic) capillaries $\underset{CO_2}{\overset{O_2}{\rightleftarrows}}$ tissue and Cells of every organ

2. After external respiration, oxygenated blood reaches to heart and pumped from left ventricle to aorta and finally to tissue cells through systemic capill
   (a) Oxygenated blood entering in the systemic capillaries (which arise from a having partial pressure of oxygen is 100 mmHg.
   (b) Where as tissue cells have an average 40 mmHg Due to this differenc pressures, O_2 diffuses from oxygenated blood to the tissue cells

Oxygenated blood in Systemic capillaries $\xrightarrow{O_2}$ Tissue cells

PO_2 100 mmHg — PO_2 40 mmHg

4. Simultaneously CO_2 which is a waste product of metabolism passes or diff from tissue cells to Systemic capillaries
   (a) Partial pressure of CO_2 in tissue cells is 45 mmHg
   (b) Partial pressure of CO_2 in Systemic capillaries is 40 mmHg. Because of t difference in pressure, CO_2 diffuses from tissue cells to the systemic capillar

Systemic (aortic) capillaries $\xleftarrow{CO_2}$ tissue or cells of every organ

PCO_2 40 mmHg — PCO_2 45 mmHg

LUNG VOLUMES AND CAPACITIES

In normal quite breathing there are about 15 complete respiratory cycles per minute

Lungs and air passages are never empty and as the exchange of gases takes place on across the walls of the alveolar ducts and alveoli the remaining capacity of respirator passages is called the anatomical dead sapce (about 150 ml).

- **Tidal Volume:** This is the volume of air in one breath is about 500 ml at rest. It is amount of air passing into and out of the lungs during each cycle of breathing

- **Inspiratory Reserve Volume (IRV):** This is the extra volume of air that can be inhaled into lungs during maximal inspiration (that is over and above normal tidal volume.)

  It is about 3100 ml

- **Inspiratory Capacity (IC):** This is the amount of air that can be inspired with maximum effort.

  IC = Tidal volume + Inspiratory reserve volume

  IC = 500 ml + 3100 ml

  IC = 3600 ml

- **Expiratory Reserve Volume:** This is the largest volume of air which can be expelled from the lungs during maximal expiration.

  It is about 1400 ml or 1200 ml.

- **Residual Volume:** It is the volume of air remaining in the lungs after forced expiration. This cannot be measured directly but about 1200 ml to 1500 ml.

- **Vital Capacity (VC):** This is the maximum volume of air which can be moved into and out of the lungs.

  VC= Tidal volume + IRV + ERV

  VC= 500 ml + 3100 ml + 1400 ml

  VC= 5000 ml

REGULATION (RATE AND DEPTH) OF RESPIRATION

Regulation (rate and Depth) of Respiration is depends upon two factors:

1. Neural or Nervous control- includes various centres present in the brain
2. Chemical Control-includes chemosensitive areas present in aorta and carotid artery.

Neural or Nervous Control

Neural or Nervous control includes various centres present in the brain which regulates rate and depth of respiration.

1. **Respiratory Centre:** It is situated in the medulla oblongata of brain.
2. **Pneumotaxix Centre:** It is situaited in the Pons of the brain.

Chemical Control

Chemical Control includes chemosensitive areas or chemoreceptors which are sensitive to Partial pressure of CO_2 and H^+ ions (pH) in blood. These chemoreceptors are activated due to increase in CO_2 and H^+ ions concentration which in turn activate the respiratory

centre in medulla for regulation of respiration. For example, increase of CO_2 concentration increases the rate and depth of respiration.

Following are the Chemoreceptors:

1. **Aortic bodie:** Present in aortic arch.
2. **Carotid bodies:** Present in carotid arteries which supply blood to brain.

DISORDERS OF RESPIRATORY SYSTEM

1. **Tuberculosis (TB):** The bacterium mycobacterium tuberculosis produces infection to lungs.

   Symptoms: Fatigue, weight loss, lethargy, anorexia, low grade fever, night sweats, cough, dyspnea, chest pain, hemoptysis (spitting blood).

2. **Pneumonia:** The bacterium streptococcus Pneumoniae produces infection in alveoli.

   Symptoms: fever, chills, Productive or dry cough, malaise, chest pain and sometimes dyspnea (difficulty in breathing) and hemoptysis (spitting blood).

3. **Emphysema (Full of Air)** is a disorder characterized by destruction of the walls ofthe alveoli, abnormally large air spaces that remain filled with air during exhalation. It is due to cigarrate smoking.

4. **Coryza or Common Cold:** Rhinovirus causes common cold in adults.

   Symptoms: Runny nose, sneezing, excessive secreations, dry cough or sore throat and congestion.

5. **Influenza (Flu)** is also caused by a virus influenza and produces more severe symptoms than cold that is very high temperature and muscle pains.

   Symtoms: Chills, fever, headach and bodyache.

6. **Sinusitis:** An inflammation of the nasal membrane due to allergic reaction or infection.

7. **Tonsillitis:** Inflammation of palatine tonsils due to viruses and streptococcus pyogenes.

8. **Asthma:** It is a disorder in which there is difficulty in breathing due to constriction of bronchi (bronchospasm) and there is excessive secretion of thick sticky mucus which further narrows the airway. It occurs due to hypersensitivity to a variety of stimuli.

9. **Diphtheria:** This is a infection of the pharynx due to Corynebacterium diptheriae.

10. **Hay Fever (Allergic Rhinitis):** In this condition, hypersensitivity develop to poller grains (foreign proteins), motes in pillow feathers, animal dung etc.

Symtoms: Acute inflammation of nasal mucosa, rhinorrhea, redness of the eyes, excessive secreation of tears.

11. **Chyne Stoke's Breathing:** It is often seen in children during sleep are often just before death. In this there is a repeated cycle irregular breathening that begins with rapid and deep breathing (Hyperpnoea) is followed by no breathening (apnoea).
12. **Dyspnea:** Diffculty in breathing due to weakness of intercoastal muscles, damage of ribs, stiffness of lungs.

IMPORTANT QUESTIONS

1. Name the different organs of Respiratory system. (S-98)
2. Define respiratory system or respiration. (W-96, 98, 00)
3. Draw well labeled diagram of Respiratory system. (S-97, 00, 02; W-00, 01)
4. Discuss the respiratory function of nasal cavity or nose. (W-01)
5. Describe in brief the Larynx. (W-97)
6. Name the cartilage which form larynx. Mention the function of larynx. (S-03; W-01)
7. Explain, thoracic cage helps the process of breathing. (S-98; W-98)
8. Describe Trachea. (S-96)
9. Give the functions of Respiratory system. (S-96, 99)
10. Give the functions of Trachea, Bronchi, Bronchioles. (S-96)
11. Describe the structure of Lung. (W-97)
12. Describe alveoli of lungs in short. (W-99)
13. Describe the mechanism of respiration or Physiology of respiration. (S-96, 98, 00, 01, 02, 03; W-96, 00)
14. Describe structure, attachment and function of diaphragm. (W-98)
15. Define the following terms and give their normal value:
    (a) Vital capacity
    (b) Tidal volume
    (c) Residential volume (S-98, 99, 03; W-98, 00, 01)
16. Define Dyspnea. (S-03)
17. Name the factors regulating the respiration. (S-00, 02)
18. Define respiration and mention at least five disorders of respiratory system. (W-98)
19. Write about Chyne stoke's breathing. (W-99)
20. Name the factors regulating the respirations. (S-00,02)
21. Mention at least five disorders of respiratory system. (W-98)

9

CHAPTER

Digestive System

DEFINITION

Digestion is the conversion of complex food into simple form so that easily absorbed in the blood.

OR

Digestion is the process of breaking down of larger food particles into small molecules to enter into body cells.

In short breakdown of food is known as digestion.

The organs involved in the breakdown of food is known as digestive system.

ORGANS OF DIGESTIVE SYSTEM

G.I.T. (Gastrointestinal Tract)

Alimentary Canal or Tract

1. Mouth
2. Pharynx
3. Esophagus
4. Stomach
5. **Small Intestine:** Duodenum, Jejunum, Ileum
6. **Large Intestine:** Cecum, Colon (Ascending Colon, Transverse Colon, Descending Colon, Sigmoid Colon) Rectum, Anus.

Accessory Organs

1. Teeth, Tongue, 3 Pairs of Salivary Glands
2. Liver
3. Pancreas
4. Gallbladder

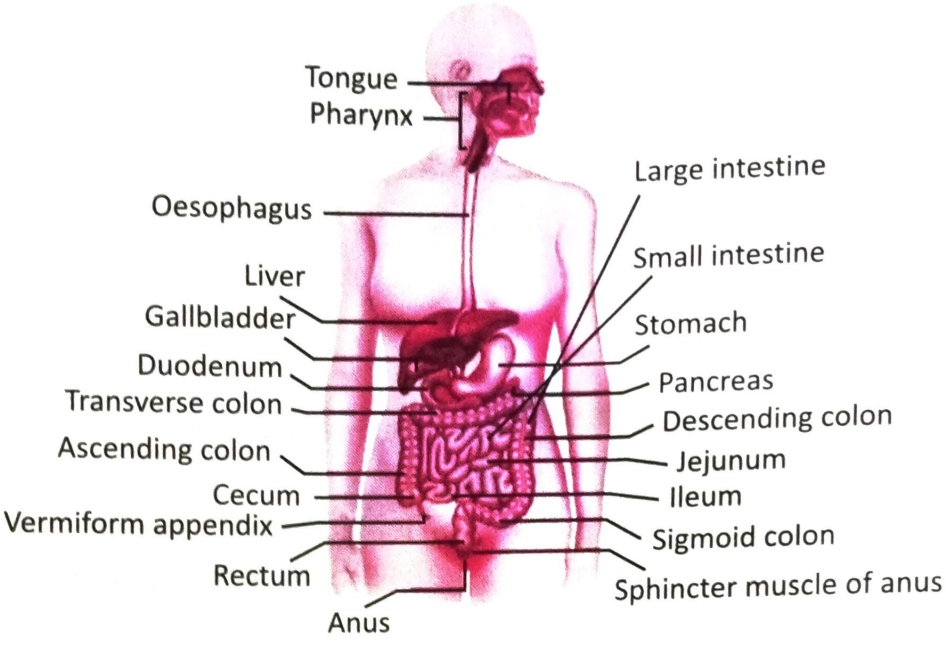

Fig. 9.1: *Digestive System*

FUNCTIONS OF DIGESTIVE SYSTEM

Functions or activities of digestive system are:

1. **Ingestion:** Process of taking food and drink, e.g., eating and drinking.
2. **Mixing:** In mouth food or liquid mixes with saliva.
3. **Propulsion:** Food moves forward in alimentary tract (Gastrointestinal tract).
4. **Digestion:** Breakdown of food.
   (a) **Mechanical digestion/breakdown:** Physically breaking of food into small pieces with the help of teeth in mouth.
   (b) **Chemical digestion:** Breaking of food into simpler nutrients with the help of enzymes and secreations. It begins in mouth, stomach and intestine. Here, carbohydrates converted into glucose, proteins into amino acids, lipids into fatty acids.
5. **Absorption:** Smaller molecules like glucose, amino acids and fatty acids pass through alimentary canal and enter into the blood.

Digestiv

DEFINITION

Digestion is the conversion of comple
the blood.

Digestion is the process of breaking
enter into body cells.

In short breakdown of food is

The organs involved in the bre

ORGANS OF DIGESTIVE SYSTE

G.I.T. (Gastrointestinal Tract)

Alimentary Canal or Tract

1. Mouth
2. Pharynx
3. Esophagus
4. Stomach
5. **Small Intestine:** Du
6. **Large Intestine:** Ce
   Colon, Sigmoid Col

6. **Elimination or defecation:** Undigested and unabsorbed food materials are removed (excreted) from alimentary canal as faeces. This process is called defecation.

GIT (GASTROINTESTINAL TRACT) OR ALIMENTARY TRACT

HISTOLOGY OR COATS OF ALIMENTARY CANAL (GIT)

Alimentary tract or GIT contains four layers:

1. Serosa
2. Mucularis
3. Submucosa
4. Mucosa.

The structure of these layers varies, in different regions of the GIT, depending on their function.

1. **Serosa:** Outer most protective layer of GIT made up of areolar connective tissue and simple squamous epithelium. Serosa is absent in upper part of esophagus
2. **Muscularis:** It consists of muscles arranged into an inner circular and outer longitudinal layer. An oblique muscle layer also present in stomach. The coordinated contractions of these layers is called peristalsis, which propels the food through the GI tract. Esophagus contain skeletal muscle that produces voluntary swallowing.
3. **Submucosa:** The submucosa is a thick layer of loose connective tissue that surrounds the mucosa. This layer also contains blood vessels, lymphatic vessels and nerves. It allows the mucosa to move flexibly during peristalsis.

   (i) Mucosa: It is innermost layer of alimentary canal. It consists of

   (a) Layer of epithelium direct contact of the GI tract. Function is absorption and secretion.

   (b) Layer of connective tissue called lamina propria. It also serves as an important physical barrier which stops unwanted materials and organisms from entering into the body.

   (c) Thin layer of smooth muscle (muscularis mucosae) function is not known. This layer forms irregular folds called rugae in the stomach and small finger like folding called villi in the small intestine.

MOUTH

1. The mouth cavity is the first organ of digestive system and alimentary tract where digestion starts due to salivation. The parts of the mouth include the lips, gums orgingiva (these are slight elevations of the overlying oral mucous membrane), vestibule (the part of mouth outside the gums and teeth), mouth cavity, teeth, hard palate (the bony front portion of the roof of the mouth), soft palate (the muscular back portion of the roof of the mouth), tongue and salivary glands. The mouth is also known as the oral cavity or the buccal cavity.
2. Oral cavity is lined with mucous membrane which is made up of stratified squamous epithelium containing small mucous secreting glands.
3. Main function of mouth cavity is in the process of Mastication (chewing).

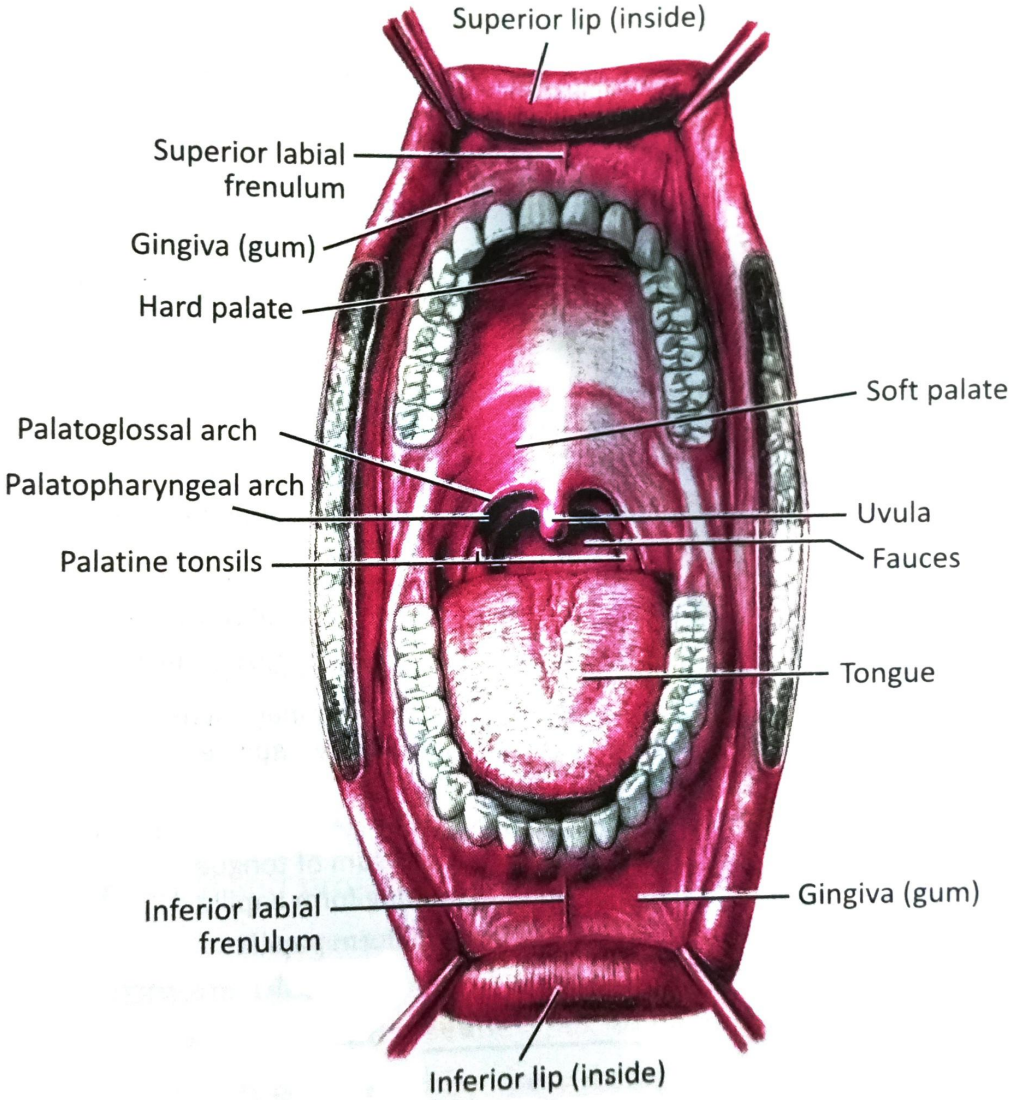

Fig. 9.2: Mouth

TOUNGE

(i) Tongue is voluntary (Skeletal) muscular structure that occupies the floor of the mouth.

(ii) The superior surface of the tongue is consists of stratified squamous epithelium

(iii) The tongue contains elevations or little projection on the surface called papillae. These are of 3 types and contains taste buds (sensory receptors) which are responsible for taste except Filiform papillae.

There are three types of papillae:

1. **Fungiform Papillae:** Numerous reddish dots at the tip responsible for taste perception.
2. **Filiform Papillae:** Smallest whitish dots on the surface of the anterior two thirds of the tongue. Responsible for rough texture.
3. **Circumvallate Papillae:** These are arranged in an inverted 'V' towards the base of the tongue, responsible for taste perception

Functions of the tongue are as follows:

1. Mastication (Chewing)
2. Deglutition (Swallowing): Movement of food from the mouth into stomach.
3. Speech
4. Taste

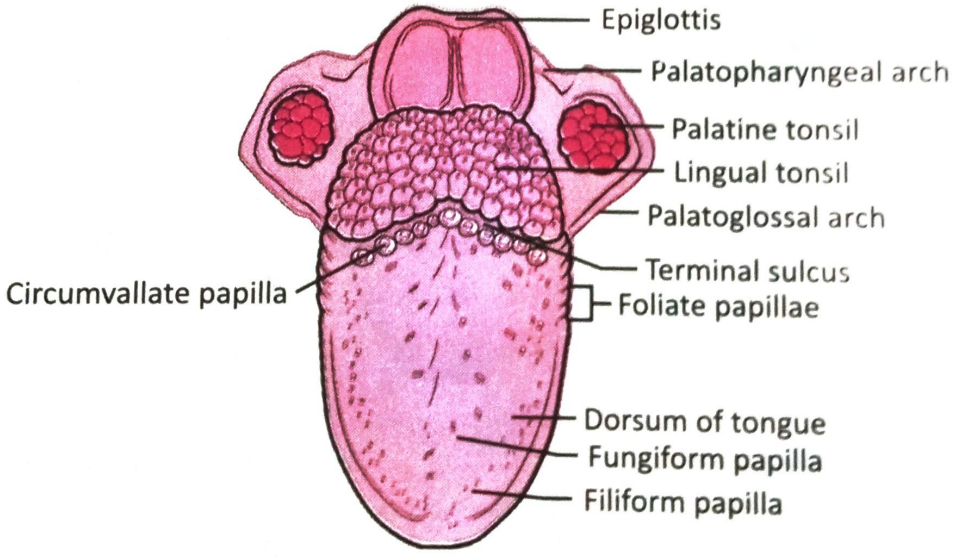

Fig. 9.3: Tongue

TEETH

Anatomy or Structure of Tooth

(i) Teeth are accessory digestive organs embedded in the sockets of the mandible (upper bone) and maxilla (lower bone).

(ii) **A typical tooth has three major regions:**

1. **Crown:** It is visible portion above the gum (upper part)
2. **Root:** Embedded in the bone (lower part)
3. **Neck** is the constricted (narrowed) region separates the crown and root.

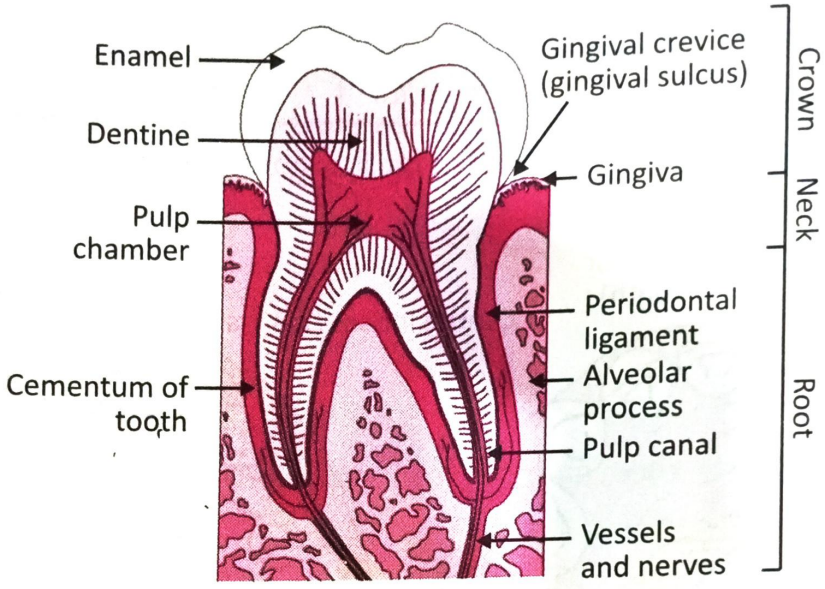

Fig. 9.4: *Structure of tooth*

Longitudinal section of the tooth shows three layers: Enamel, Dentine, Pulp

1. The enamel is the outer layer of the tooth and it is extremely hard made up of calcium phosphate minerals. It serves surface for chewing of food and protect the tooth against harmful bacteria as-well-as acids.
2. Dentine is the middle layer. It is less mineralized and less hard than enamel.

   It supports enamel and protect pulp. It gives the tooth its basic shape and rigidity.
3. Pulp is the innermost or center layer of tooth and provides nutrition to tooth. This pulp cavity contains blood vessels, lymph vessels and nerves which passes to the tooth through a small foramen at the apex of each root.
4. The root of the tooth is covered by the substance called cement, which fixes the tooth in the socket.

Blood vessels and the nerves Blood supply – maxillary arteries provides blood to teeth.

Nerve supply: Maxillary nerves and mandible nerves.

Classification of Teeth

Each individual has two sets of teeth:

1. **Temporary or Deciduous or Milk Teeth:** (20 in number, 10 in each jaw). They begin to erupt at the age of 6 months. They lossed between 6 to 12 years and are replaced by permanent teeth.

Upper Jaw – Total 10

← Centrally →

2 molars	1 canine	4 incisors	1 canine	2 molars

Lower jaw – Total 10

2 molars	1 canine	4 incisors	1 canine	2 molars

Total teeth of 2 jaws – 20 teeth (Molar 8, Canines 4, Incisors 8)

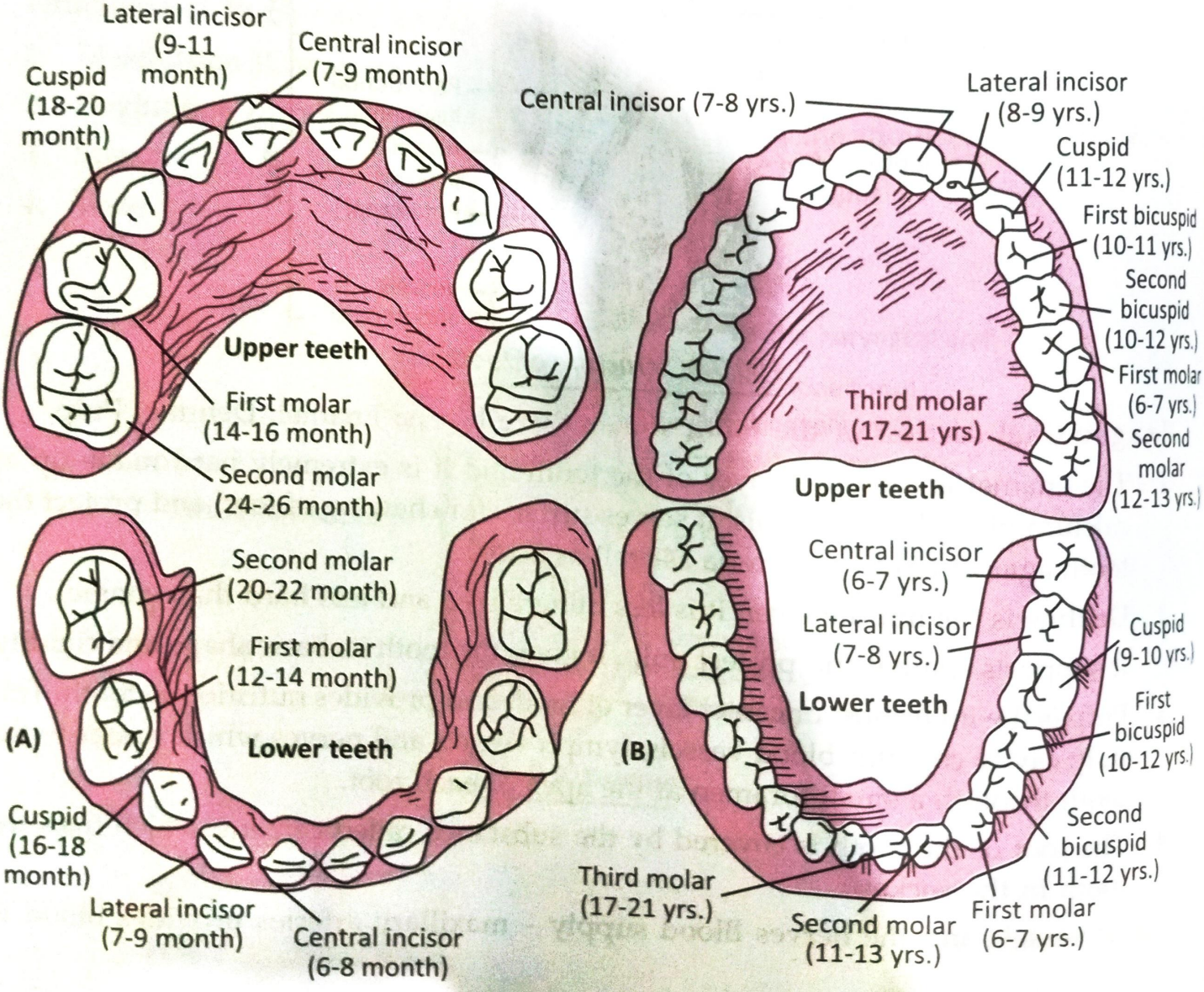

Fig. 9.5: ***Type of teeth in children and adult***

2. **Permanent Teeth:** Between the age of 6 to 24 years, the permanent teeth develop completely. They are 32 in number fixed in upper and lower jaw.

Upper jaw – Total 16

3 molars	2 Premolars	1 canine	Centrally 4 incisors	1 canine	2 Premolars	3 molars

Lower jaw – Total 16

3 molars	2 Premolars	1 canine	Centrally 4 incisors	1 canine	2 Premolars	3 molars

Total teeth of 2 jaws – 32 teeth (premolars 12, molar 8, canines 4, incisors 8)

Functions of teeth or on the basis of their function teeth are classified as:

1. **Cutting teeth:** Incisors and cannines – they are used for biting off pieces of food.
2. **Chewing teeth:** Premolars and molars – with flat surface are used for grinding or chewing food.

Shapes of Teeth

1. **Incisors** are chisel shaped
2. **Cannines** are cone shaped
3. **Premolars and Molars:** They have broad crown with rounded cusps

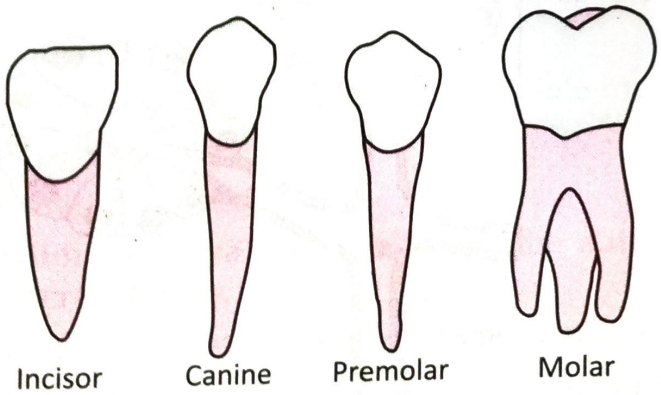

Fig. 9.6: *Shapes of teeth*

SALIVARY GLANDS

Salivary gland releases a secretion called saliva into the oral cavity.

There are 3 pairs of Salivary glands:

1. **Two Parotid Glands (par-near, to-ear):** These are largest. They lie in front of each ear. These secretes saliva into the mouth via a parotid duct.

2. **Two Submandibular Glands:** Lie in the floor of the mouth or below jaw. These secretes saliva into the mouth via submandibular duct.
3. **Two Sublingual Glands:** Lie below the tongue on each side. These secrete saliva into the mouth via smaller ducts.

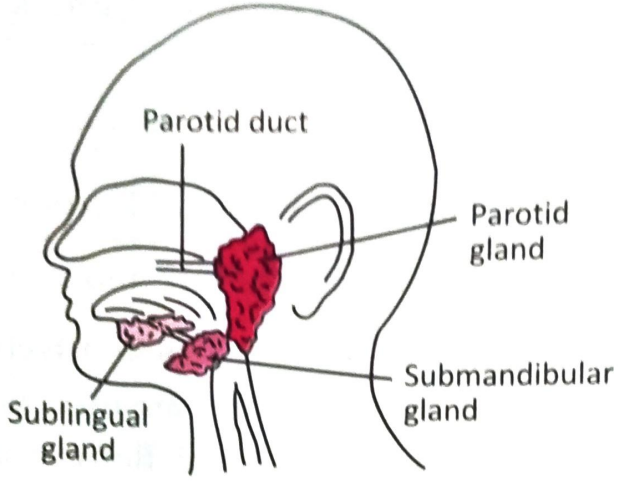

Fig. 9.7: ***Location of salivary gland***

Structure of Salivary Glands

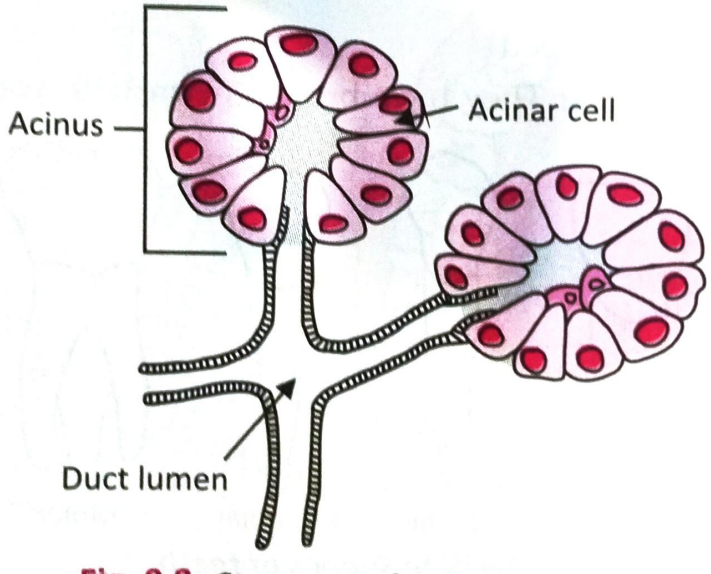

Fig. 9.8: ***Structure of salivary Gland***

1. Salivary glands are all surrounded by a fibrous capsule.
2. They have number of lobules.
3. These lobules made up of small acini (secreting portion).
4. These acini consist of secretory cells. These secretary cells pour their secretions into ductules which join up to form larger ducts passes into the mouth.

Composition and Functions of Saliva

Saliva is watery, slightly alkaline secretion (1-1.5 litre) of salivary glands.

Chemically, saliva is 99.5% water provides medium for dissolving foods and 0.5% solutes constitutes:

1. Ions-sodium, potassium, chloride, bicarbonate, phosphate.
2. Some dissolved gases.
3. Various organic substances including urea, uric acid.
4. Mucus: Moistens & lubricates the food so it can easily be moved about in the mouth, formed into a bolus and swallowed.
5. Immunoglobulin A (Proteins called antibodies) – prevents growth of microbes
6. Lysozyme, a bacteriolytic enzyme – kills the microbes.
7. Carbohydrate digestive enzyme – Salivary amylase (Ptyline) – digestion of carbohydrates (complex sugar) to simple sugars in mouth, i.e., breaking of starch (polysaccharides) into maltose, i.e., disaccharides.

Functions of Salivary Glands

1. Salivary glands secretes saliva to keep mouth and pharynx moist.
2. Cleans the mouth and teeth.
3. Lubricate the mouth and prevent damage of mouth due to rough food.
4. Chemical digestion of carbohydrates – salivary amylase converts carbohydrates (complex sugar) to simple sugars, i.e., breaking of starch (polysaccharrides) into maltose (disaccharides).
5. Taste: Taste buds are stimulated by saliva responsible for the sense of taste.
6. Moistens the food and mouth.
7. It makes swallowing and speech easier.

Salivation or secreation of saliva is controlled by the autonomic nervous system. About 1-1.5 litre saliva secreted daily.

Parasymphathetic nerves stimulate (increases) secreation of saliva.

Symphathetic nerves decreases secretion of saliva during stress resulting in dryness of the mouth.

ESOPHAGUS

The esophagus (eating gullet) is a collapsible muscular tube about 25 cm long and 2 cm in diameter that connects throat with stomach. It lies behind trachea and heart. It begins at end of the laryngopharynx and passes through mediastinum of the thorax. Then it pierces (crosses) the diaphragm and ends in the stomach.

Functions of Esophagus

1. Esophagus transports food into the stomach.
2. It secretes mucus which lubricate the food.

STOMACH

Location

The stomach is a typically 'J' shaped dilated portion of the GI tract situated in the left abdominal cavity below the diaphragm.

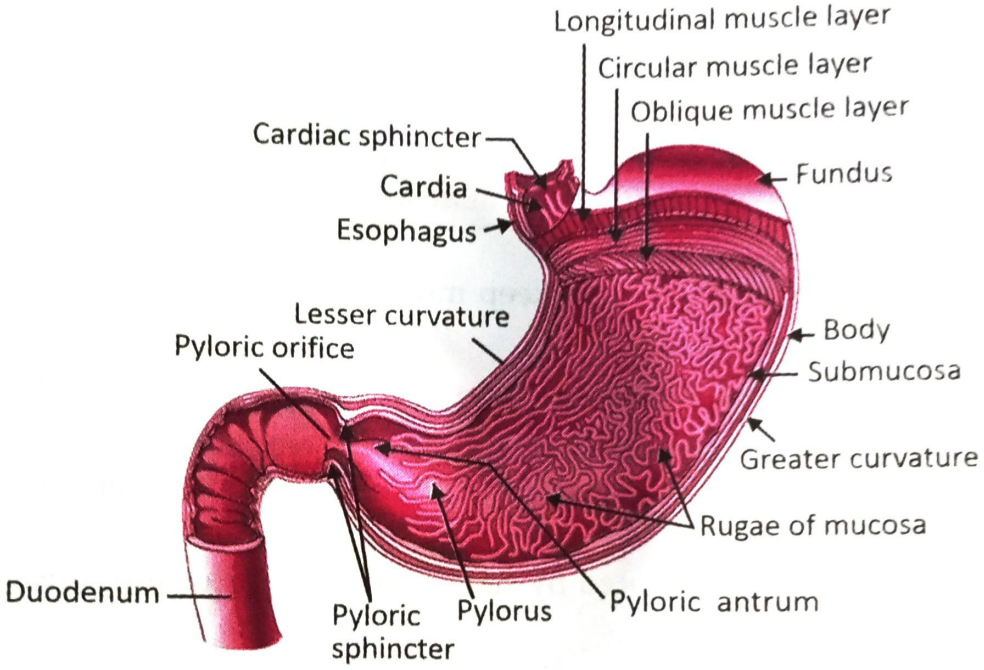

Fig. 9.9: ***Longitudinal section of Stomach***

Anatomy of Stomach

The stomach has four main regions:

1. **Cardia:** It is the superior (upper) opening of the stomach.
2. **Funds:** It is a rounded portion situated front and left side of the cardia.
3. **Body:** It is large central portion of the stomach below funds.
4. **Pyloric antrum:** It connects stomach to the duodenum (first part of small intestine) via pyloric sphincter (circular smooth muscles.)

The concave medial border of stomach is called lesser curvature.

The convex lateral border is called greater curvature.

When the stomach is empty, the mucosa lies in the large folds, called rugae.

Functions or Physiology of Stomach

1. Stomach acts as a temporarily reservoir (storage) of food
2. Stomach secretes gastric juice
3. Stomach mixes gastric juice & food to form chyme (liquid mass)
4. Chemical digestion of proteins – breakdown of proteins into peptides
5. Chemical digestion of lipids – breakdown of lipids (triglycerides-blood fat) into fatty acids.
6. Stomach cause absorption of Vitamin B_{12} due to intrinsic factor.
7. Stomach kills bacteria which is present in food due to hydrochloric acid.
8. Stomach secrete a hormone Gastrin into blood which stimulate enzyme secretion.

Regulation of Gastric Juice

Mucosa (innermost) layer of stomach contains gastric glands.

Gastric glands consists of four types of cells:

1. Mucous cells – Secretes mucus (sticky watery secretion)
2. Parietal cells – Secretes HCl and intrinsic factor (glycoprotein)
3. Chief cells – Secretes pepsinogen (digestive enzyme) and gastric lipase (digestive enzyme)
4. G or Endocrine cells – Secretes the hormone gastrin

The secretions of the mucous, parietal and chief cells form gastric juice which totals 2 to 3 litres per day.

Composition of Gastric Juice

2 to 3 litres per day

Gastric Juice Composition	Function
1. Water	Liquify or moisten the food
2. Hydrochloric acids	1. HCL kills microbes 2. HCL converts pepsinogen into pepsin which causes digestion of proteins (break down of proteins into peptides)
3. Protein digestive enzyme – pepsinogen	Due to HCl, pepsinogen converts into pepsin which causes digestion of proteins (break down of proteins into peptides)
4. Lipid digestive enzyme – Gastric lipase	Digestion of lipids- break down of lipids (triglycerides-blood fat) into triglycerides into fatty acids and monoglycerides.

Gastric Juice Composition	Function
5. Intrinsic factor	For absorption of Vitamin B_{12}
6. Mucus	Prevent mechanical and chemical injury to stomach wall by lubricating the food (Protection of stomach Wall)
7. Hormone Gastrin	1. Stimulate parietal cells to secrete HCl 2. Stimulate chief cells to secrete pepsinogen.

Phases of Gastric Juice Secretion

There is always a small quantity of gastric juice present in the stomach, even when stomach contains no food. This is known as fasting juice.

There are three phases of Gastric juice secretion:

1. Cephalic phase
2. Gastric phase
3. Intestinal phase

Cephalic Phase	Gastric Phase	Intestinal Phase
This phase occurs due to sight, smell or taste of food which stimulate sensory receptors in cerebral cortex and appetite centre in hypothalamus. So cerebral cortex and hypothalamus (brain) send nerve impulse to the medulla oblongata. The medulla transmits impulses to vagus nerve	This phase occurs when food reaches the stomach, the enteroendocrine cells of stomach secrete a hormone 'gastrin' into blood	This phase occurs when partially digested contents of stomach reaches to the intestine (duodenum) then endocrine cells of intestine produces two hormones secretin and cholecystokinin.
Then vagus nerves stimulate parasymphathetic nerves which causes stimulation of gastric glands to secrete gastric juice. About 20% of total acid secretion occurs before food enters the stomach.	Gastrin hormone stimulate gastric glands to produce more gastric juice about 50-60% of total gastric acid secretion occurs during this phase.	These two hormones slow down the secretion of gastric juice and reduces gastric motility. 5-10% of gastric secretion occurs during this phase

SMALL INTESTINE

The major events of digestion and absorption of nutrients occur in long tube called the small intestine. The small intestine begins at the pyloric sphincter of the stomach and opens into a large intestine. It is about 5 metres in length and 2.5 cm in diameter. The small intestine is so called because its lumen diameter is smaller than that of the large intestine, although it is longer in length than the large intestine.

Anatomy of Small Intestine

The small intestine is divided into three regions:

1. **Duodenum (c-shaped):** It is shortest region about 25 cm in length and starts at the pyloric sphincter of the stomach.
2. **Jejunum (long & coiled middle portion):** It is about 2 meters middle part.
3. **Ileum (highly coiled, longest portion):** It is final and longest part of small intestine about 5 meters. It joins the large intestine at the ileocaecal valve and opens into the caecum of large intestine.

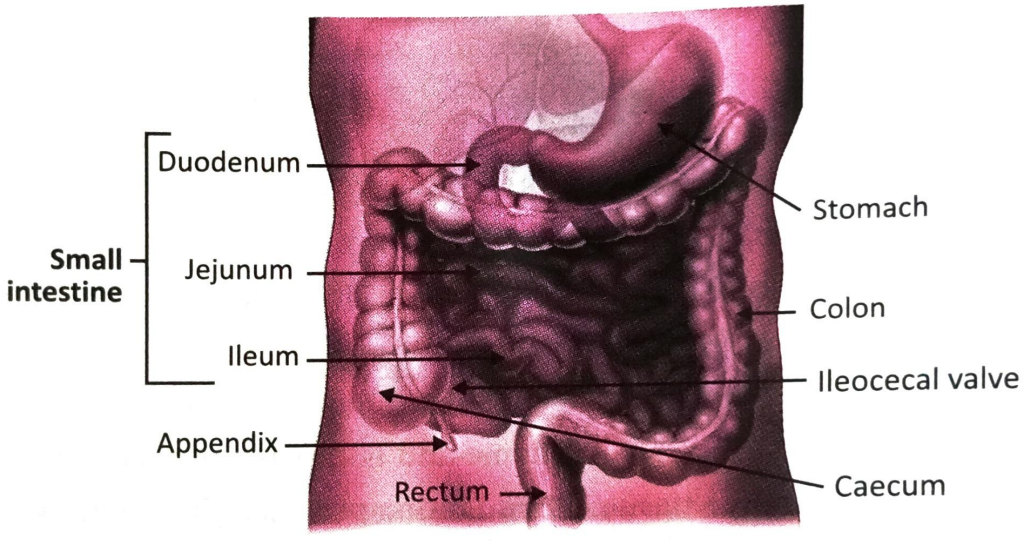

Fig. 9.10: ***Parts of Small Intestine***

Functions of Small Intestine

1. Functionally, the small intestine is mainly involved in the digestion and absorption of nutrients. It receives pancreatic juice and bile which aids absorption of nutrients.
2. The small intestine promotes mixing of chyme (liquid bolus) with digestive juices and bring into contact with the mucosa for absorption.
3. Its peristalsis causes onward movement of chyme.

4. Chemical digestion of carbohydrates (carbohydrates are broken down in monosaccharides).
5. Chemical digestion of proteins (proteins are broken down into amino acids).
6. Chemical digestion of lipids (lipids are broken down into fatty acids and glycerol).
7. Chemical digestion of nucleic acids. (DNA and RNA into nucleotides).
8. Small intestine causes absorption of about 90% of nutrients and water.
9. Small intestine Secrets hormones secretin, cholecystokinin (CCK).
10. Small intestine (Solitary and aggregated lymphatic follicles) kills microbes.

Histology of Small Intestine

It consists of four layers of tissue:

1. **Serosa:** Outer most layer of areolar connective tissue and simple squamous epithelium.
2. **Muscularis:** Present inside to serosa layer. It is formed by smooth muscle arranged into an inner circular and outer longitudinal layer.
3. **Submucosa:** Present below or inside the muscularis layer. It consists of loose connective tissue containing nerves, blood and lymph vessels.
4. **Mucosa:** It is innermost layer of alimentary canal. Mucosa layer small intestine finger forms like folding called villi which consists of following layers:
   (a) **Layer of columnar epithelium:** It consists of four types of cells:
      (i) **Absorptive cells:** Digests and absorb nutrients.
      (ii) **Goblet cells:** Secretes mucus.
      (iii) **Enteroendocrine cells:** Secretes hormone secretin, cholecystokinin.
      (iv) **Paneth cells:** Secretes lysozyme and is capable of phagocytosis.
   (b) **Layer of connective tissue called lamina propria:** This contains an arteriole a venule a blood capillary network and a lacteal (lymphatic capillary, absorb fat gives a milky appearance to the lymph).

   Numerous lymph nodes are also found in the mucosa. The smaller ones are known as solitary lymphatic follicles and larger nodes are situated towards the distal end of the ileum are called aggregated lymphatic follicles (Peyer's patches). Their function is to neutralize ingested antigens (foreign matter).
   (c) Thin layer of longitudinal and circular smooth muscle (muscularis mucosae)

   Besides villi (finger like projections), small intestine also has hair like projections called microvilli form fuzzy line, called brush border.

   Both mucosa and submucosa forms folds or ridges called Circular folds. Its enhances absorption by increasing surface area

Thus circular folds, villi, microvilli which increases the surface area for digestion and absorption.

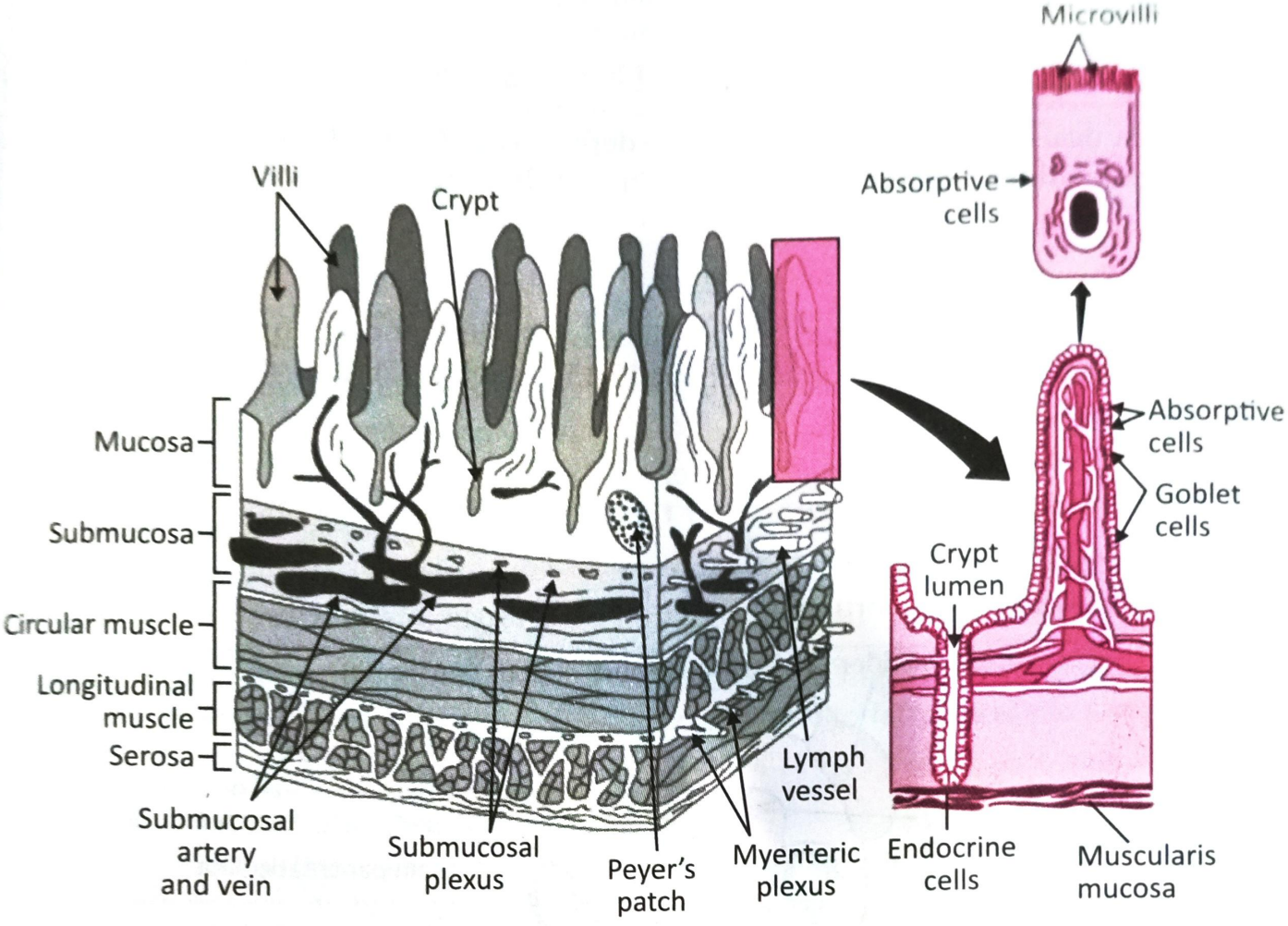

Fig. 9.11: ***Structure and layers of Small Intestine***

Intestinal Juice

Only small intestine produces digestive juice. Large intestine does not produce digestive juice. Intestinal juice along with pancreatic juice provides a liquid medium that aids absorption of nutrients.

(i) Intestinal juice is clear yellow fluid secreted by small intestine about 1 to 2 litres per day and having slightly alkaline pH (7.6).

(ii) It consists of Water, mucus and mineral salts.

(iii) The intestinal juice contains several digestive enzymes includes

(a) Carbohydrate Digestive Enzyme:

1. Amylase-converts starch (Polysaccharides) to maltose (Diasaccharides)
2. Lactase-converts lactose (Disaccharides) to glucose (Monosaccharide)
3. Sucrase-converts sucrose (Disaccharides) to glucose (Monosaccharide)
4. Maltase-converts maltose (Disaccharides) to glucose (Monosaccharide)

(b) **Protein Digestive Enzyme:** Peptidases-converts Proteins or peptides to amino acids.

(c) **Lipids Digestive Enzyme:** Lipase-converts fats to fatty acid and glycerol.

Accessory Digestive Organs – Pancreas, Liver and Gallbladder

Because chemical digestion of small intestine depends upon the activities of the pancreas, liver and gallbladder, we first consider activities of these accessory organs.

Pancreas

1. The pancreas is an organ of the digestive system and endocrine system. The Pancreas is a pale grey gland about 12-15 cm long, 120 gm situated behind the stomach.
2. **It consists of three portions:**
   (i) **Head:** Expanded portion near the curve of the duodenum.
   (ii) **Body:** It is central portion
   (iii) **Tail:** Tapering portion

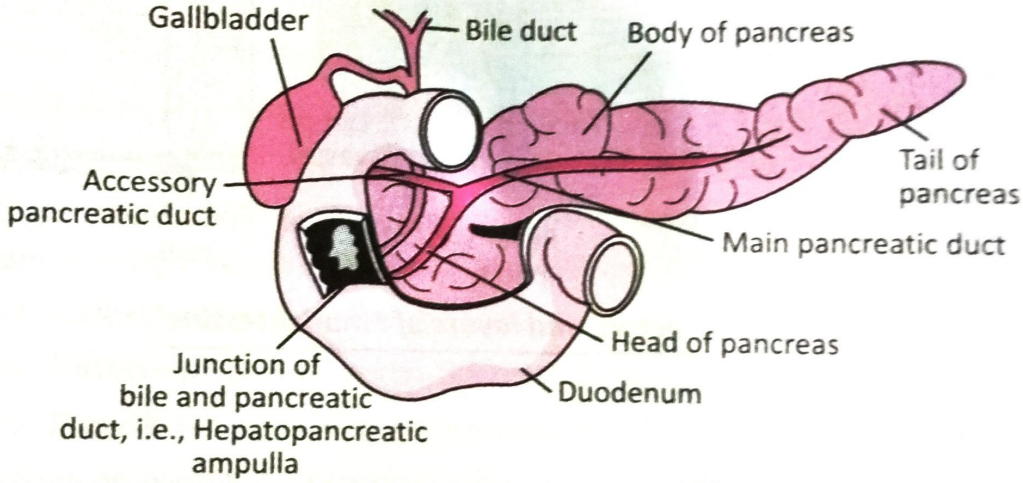

Fig. 9.12: *Longitudinal section* of Pancreas

3. **Pancreas coinsists of two types of epithelial cells so functionally divided into two parts:**
   (i) Pancreatic acini or Exocrine Pancreas – about 99% of epithelium cells (exocrine cells) secrete pancreatic juice (digestive enzymes) in pancreatic duct (tube).
   (ii) Pancreatic islets or Endocrine Pancreas – about 1% bunch of epithelium cells (endocrine cells) secrete the hormones insulin and glucagaon which maintains blood sugar level. Insulin lowers blood sugar level and glucagaon increases the blood sugar level.
4. **Pancreatic duct** joins the common bile duct from liver and gallbladder and enter the duodenum as a common duct called **Hepatopancreatic ampulla.**

Composition and Function of Pancreatic Juice

Each day the pancreas produces 1.2-1.5 litres of pancreatic juice.

Pancreatic juice is alkaline and consists of:

1.	Water	Provides liquid medium
2.	Some salts, sodium bicarbonate	Sodium bicarbonate gives slightly alkaline pH (7.1-8.2), creates the the proper pH for the action of digestive enzymes in small intestine.
3.	**Enzymes like:** **(a) Carbohydrate digestive enzyme:** Pancreatic amylase	Digestion of carbohydrates–converts starch (Polysaccharides) to maltose (Diasaccharides) to glucose (monosaccharide).
	(b) Protein digestive enzyme: Trypsin, chymotrypsin, carboxypeptidase, elastase	Digestion of Proteins (polypeptides into tripeptides, dipeptides, amino acids)
	(c) Lipid digestive enzyme pancreatic lipase	Digestion of Triglycerides (blood fat) – converted into fatty acids and glycerol (monoglycerides).
	(d) RNA and DNA digestive enzyme: Ribonucleas deoxyribonuclease	Digestion of nucleic acid, i.e., RNA & DNA

Liver

(i) Liver is the heaviest gland of the body, weighing about 1.4 kg in an average adult.

(ii) Liver is located in the upper part of the abdominal cavity.

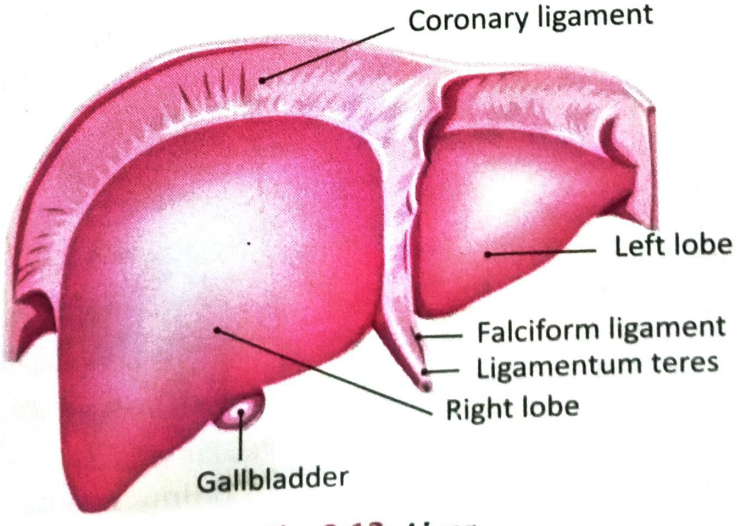

Fig. 9.13: *Liver*

(iii) It is divided into right lobe and left lobe by falciform ligament. Right lobe divided into Caudate and Quadrate lobe. Thus, liver has 4 lobes right, left, caudate, quadrate.

(iv) The lobes of the liver are made up of thousands of structural & functional units called Hepatic lobules.

(v) A hepatic lobule is typically a six sided structure (hexagaon) that consists of specialized epithelial cells called hepatocytes (hepat-liver, cytes-cells). These hepatocytes are arranged radially around a central vein

(vii) Hepatatocytes secrets bile which enter into bile canaliculi. These are narrow inter cellular canals run between the columns of hepatocytes. These bile canaliculi pour bile into bile ducts at the periphery of the lobule.

(viii) All interlobular bile ducts unite to form the larger right hepatic duct (from right lobe) and left hepatic duct (from left lobe). These right and left hepatic ducts unite and come out from liver as a common hepatic duct.

(ix) Liver has larger spaces contains capillaries called sinusoids through which blood passes. These sinusoids contains immune cells called kupffer cells which protect liver against bacterial infection through phagocytosis. Due to bile canaliculi and sinusoids, blood and bile does not mix.

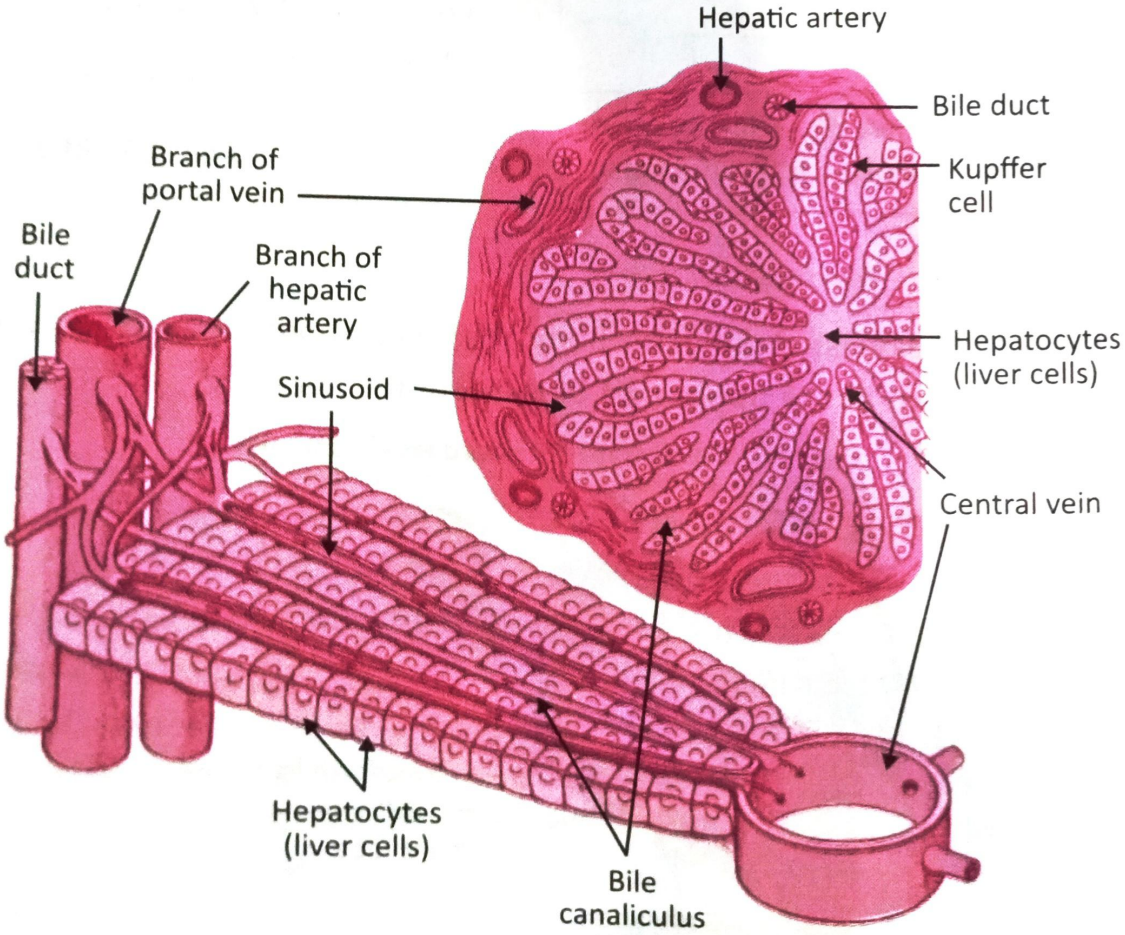

Fig. 9.14: ***Microscopic Structure of Liver***

(x) **Blood supply of the Liver: Liver takes blood from 2 sources:**

1. From hepatic artery it gets oxygenated blood
2. From portal vein it gets deoxygenated blood containing nutrients, drugs, microbes, toxins from G.I.T.

(xi) Both hepatic artery and portal vein carry blood into liver sinusoids to central vein to hepatic vein to inferior vena cava.

The branches of hepatic artery, portal vein and bile duct are enclosed in a tissue covering called are Glisons capsule.

Physiology or Functions of Liver

1. Carbohydrate metabolism or Glycogenic metabolism.
2. Protein metabolism or formation of urea.
3. Lipid metabolism or desaturation of fat.
4. **Processing of Drugs and Hormones:**
   (i) Detoxification of drugs and excretion of toxic substances.
   (ii) Excretion of thyroid and steroid hormones such as estrogen, aldesterone.
5. **Functions related to blood:**
   (i) Formation of RBCs in foetal life.
   (ii) Destruction of RBCs forming iron and bile pigment that is bilirubin.
   (iii) Formation of plasma proteins, e.g., albumin and globulin.
   (iv) Formation of anticoagulant that is heparin.
6. Synthesis of bile salts.
7. Storage of glycogen, fat soluble vitamins and minerals.
8. Phagocytosis-Kuffer cells of liver phagocytize RBCs, WBCs and some bacteria.
9. Production of heat or maintenance of body temperature.
10. Activation of Vitamin D.

1. **Carbohydrate Metabolism:** Liver is important in maintaining normal blood glucose.
   (i) When blood glucose level low, liver can break down glycogen to glucose, i.e., glycogenolysis.
   (ii) When blood glucose high, liver convert glucose to glycogen and store it.
2. **Protein Metabolism:** Liver causes deamination (remove amino group NH_2) of amino acids. Thus amino acids without amino group are used to convert to glucose or fats. Liver convert amino group into ammonia and then to which is excreted by kidney. Also liver synthesis albumin and globulin plasma proteins.

3. **Lipid Metabolism:** Liver cells stores lipids in the form of Triglycerides.

Triglycerides breakdown into

Fatty acids — For ATP production (energy)

Glycerol converted into glucose

Liver synthesize lipoproteins and cholesterol. Lipoproteins transport fatty acids, triglycerides, cholesterol. This cholesterol use to make bile salts.

4. **Processing of Drugs and Hormones:** Liver can detoxify substances such as alcohol or excrete drugs such as penicillin, erythromycin and sulfonamides.

   It can also chemically alter or excrete thyroid hormones and steroid hormones such as estrogens and aldosterone.

5. **Functions Related to Blood:**
   (i) Formation of RBCs in foetal life.
   (ii) Destruction of RBCs forming bile pigments and iron.
   Bile pigment bilirubin absorbed by liver and excreted into the bile.
   (iii) Formation of prothrombin and fibrinogen responsible for blood clotting.
   (iv) Formation of heparin, a natural anticoagulant in the blood.

6. **Synthesis of Bile Salts:** Bile salts are used in the small intestine for the emulsification and absorption of lipids, cholesterol, phospholipids and lipoproteins.

7. **Storage:** Liver stores glycogen, fat soluble Vitamins (A, D, E, K) and minerals (iron and copper), some water soluble Vitamins B_{12}.

8. **Phagocytosis:** Reticuloendothelial cells (kuffer cells) of the liver phagocytize old RBCs, WBCs and some bacteria.

9. **Production of Heat or maintenance of Body Temperature:** As a number of chemical reactions occur in the liver, heat is generated which is helpful in maintaining body temp.

10. **Activation of Vitamin D:** Skin, liver and kidney participate in synthesizing the active form of Vitamin D.

Composition and Functions of Bile

Each day, Liver (hepatocytes) secrete 0.8 to 1 liter of bile. Bile is a yellow, brownish or olive-green liquid and pH of 7.6-8.6.

Bile is partially an excretory product and partially a digestive secretion.

The composition of bile is:

1. Water
2. Mucus
3. Bile salts: These are sodium taurocholate, sodium glycocholate
4. Bile pigment: Bilirubin
5. Cholesterol
6. Phospholipids called lecithin
7. Several ions

Functions of Bile

1. **Digestion and absorption of fat:** Bile salts causes digestion and absorption of fat in small intestine.
2. **Excretion of waste, i.e., bile pigment bilirubin:** It is a waste product of RBCs and secreted in bile and breakdown in the intestine. One of the breakdown products is stercobilin gives faeces brown colour. (Large intestine).
3. **Absorption of fat soluble vitamins:** Bile helps in absorption of fat soluble vitamins in small intestine.

Gallbladder (Gall-bile)

(i) Gallbladder is a pear shaped sac attached to the posterior surface of the liver by connective tissue.

(ii) It is 7-10 cm long.

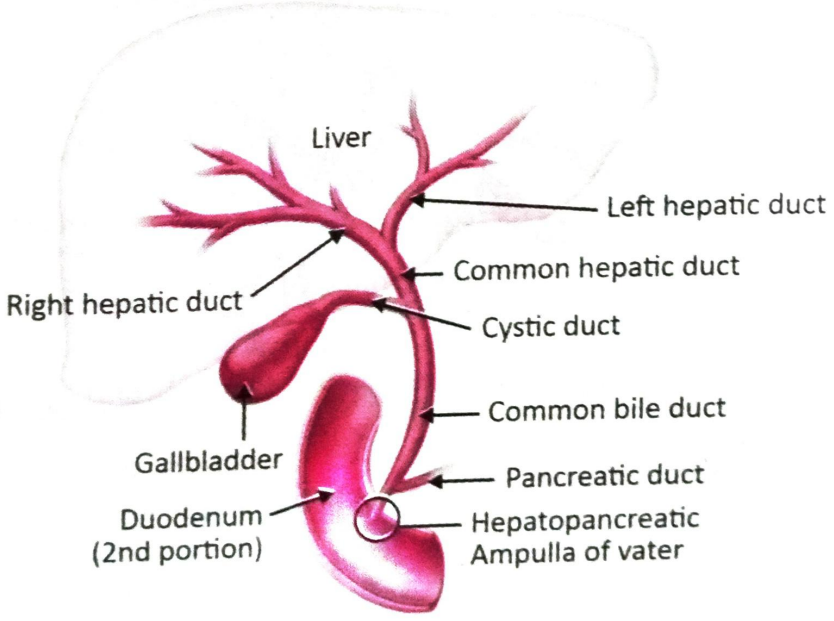

Fig. 9.15: *Gallbladder*

(iii) **The parts of gallbladder are:**

(a) The broad fundus, which is expanded end

(b) Body, the central portion

(c) Neck, the tapered portion is continuous with the cystic duct.

(iv) The cystic duct of gallbladder connect to the common hepatic duct of liver. Thus cystic duct and common hepatic duct form a common bile duct which open into duodenum.

Functions of Gallbladder

Liver secretes bile collected by hepatic duct and through cystic duct, bile enters into the gallbladder. Thus, gallbladder acts as reservoir bile. When required, gallbladder contract and releases bile into the duodenum.

LARGE INTESTINE

Large intestine is the terminal portion of gastrointestinal tract. It is about 1.5 metre long and 6.5 cm in diameter extends from the ileum to the anus.

It forms arch around the coiled small intestine. Its lumen is large than small intestine called large intestine) and length is smaller than the small intestine.

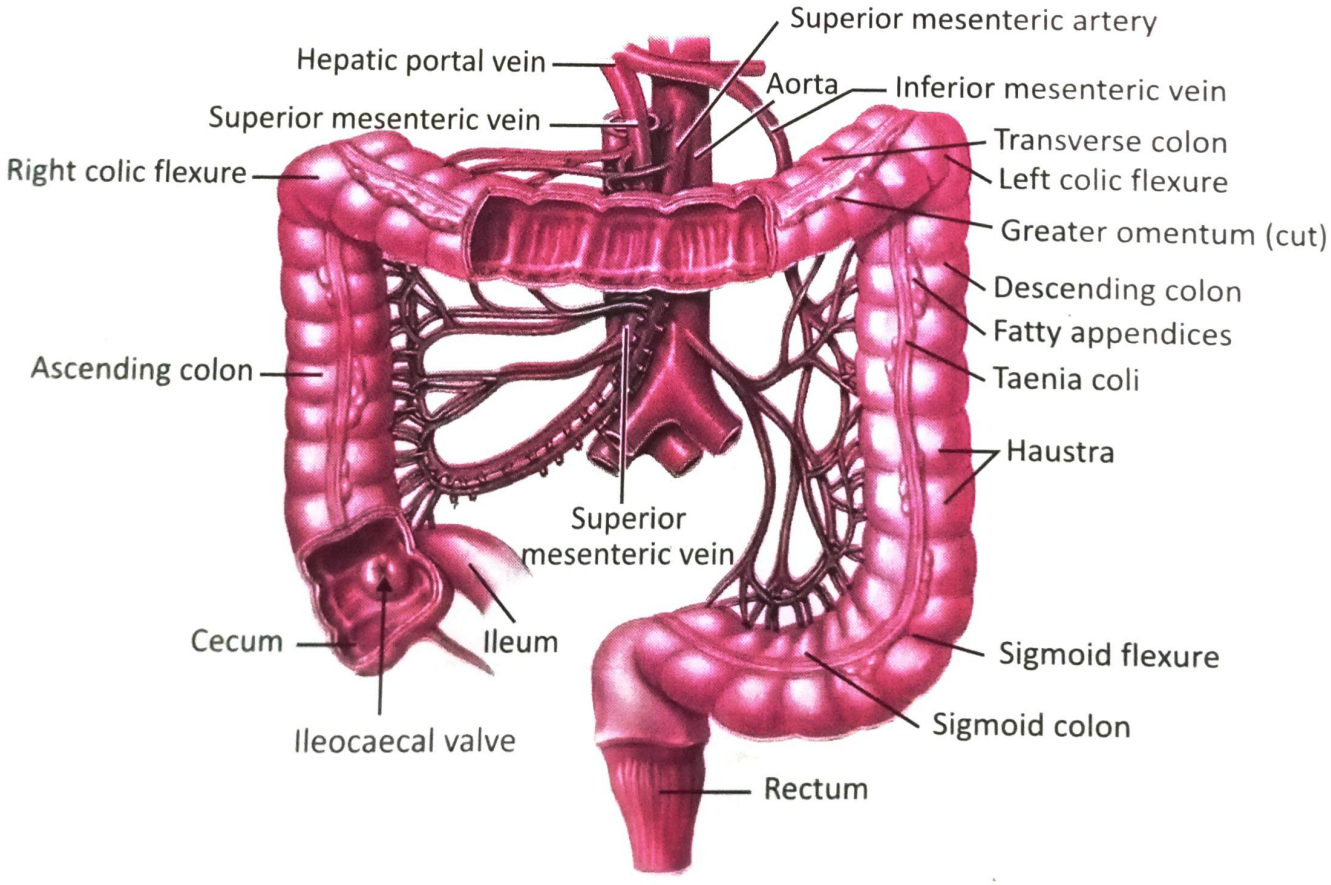

Fig. 9.16: *Longitudinal section of Large intestine*

(iii) **The parts of gallbladder are:**

(a) The broad fundus, which is expanded end

(b) Body, the central portion

(c) Neck, the tapered portion is continuous with the cystic duct.

(iv) The cystic duct of gallbladder connect to the common hepatic duct of liver. The cystic duct and common hepatic duct form a common bile duct which open into duodenum.

Functions of Gallbladder

Liver secretes bile collected by hepatic duct and through cystic duct, bile enters into the gallbladder. Thus, gallbladder acts as reservoir bile. When required, gallbladder contract and releases bile into the duodenum.

LARGE INTESTINE

Large intestine is the terminal portion of gastrointestinal tract. It is about 1.5 metre long and 6.5 cm in diameter extends from the ileum to the anus.

It forms arch around the coiled small intestine. Its lumen is large than small intestine (called large intestine) and length is smaller than the small intestine.

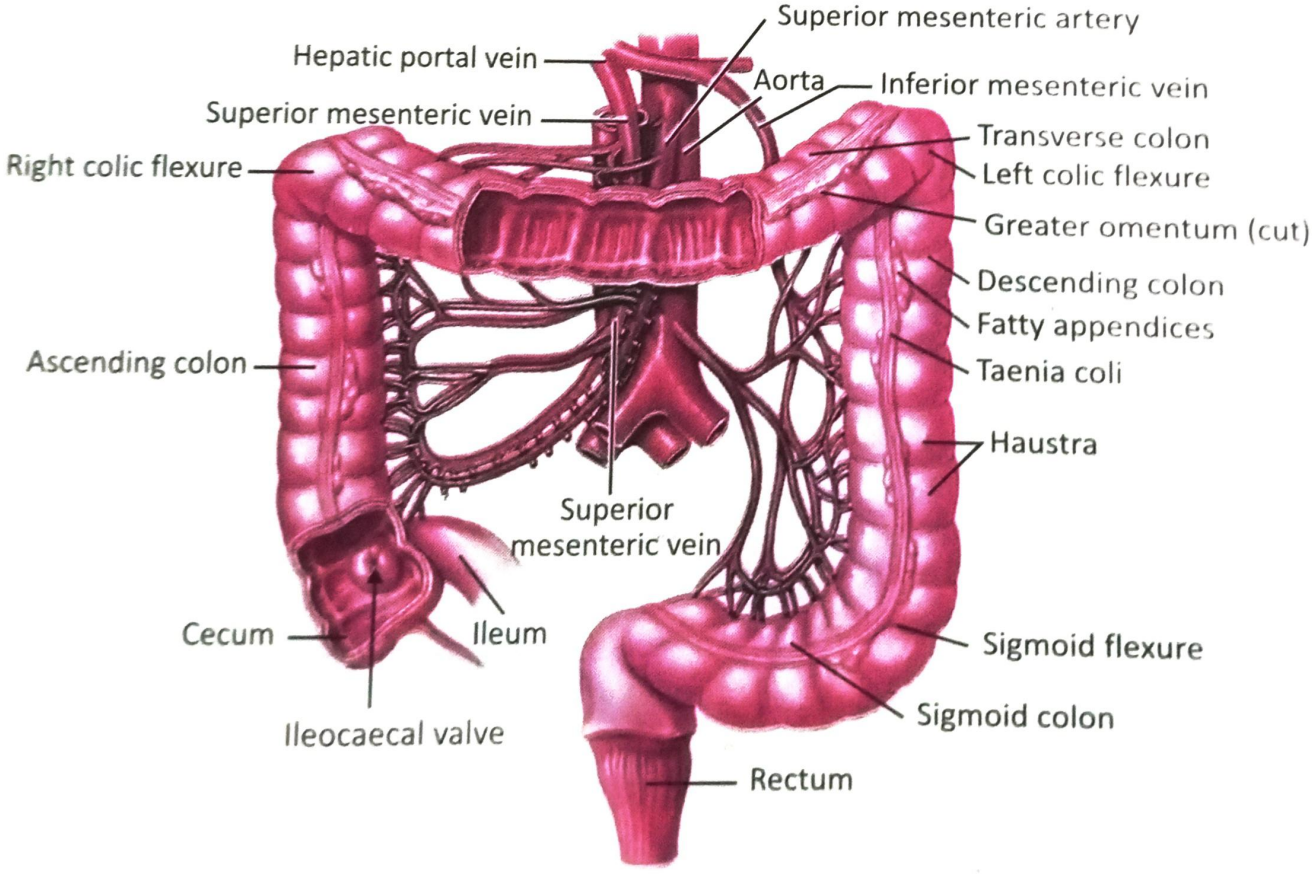

Fig. 9.16: *Longitudinal section of Large intestine*

Structurally, the four major regions of the large intestine are:

(a) Cecum

(b) Colon-ascending colon, transverse colon, descending colon, sigmoid colon.

(c) Rectum

(d) Anal canal.

1. **Cecum:** It is first and dilated pouch like portion of large intestine. The small intestine (ileum) opens into the cecum. This opening is guarded by ileocecal sphincter (valve) which allows materials from the small intestine to pass into the large intestine.

   A narrow tube about 8 cm in length attached to the end of the cecum is called as vermiform appendix. Its function is not known.

2. **Colon:** The end of cecum merges into a along tube called the colon (food passage.) which is divided into ascending, transverse, sigmoid colon.

   (i) **Ascending colon:** This passes upward from the cecum to the level of the liver where it curves to the left at the hepatic flexure (right colic).

   (ii) **Transverse colon:** It passes across the abdomen from hepatic flexure (right colic) to the splenic flexure (left colic).

   (iii) **Descending colon:** Transverses colon passes down to the left side of the abdominal cavity and then curves towards the midline.

   (iv) **Sigmoid colon (Sigm.-s shaped.):** It is S shaped curve in the pelvis that ends as a rectum.

3. **Rectum:** It is last portion of G.I. tract. The terminal 2-3 cm of the rectum is called **anal canal.** The exterior opening of the anal canal is called anus. It is guarded by an internal anal sphincter of smooth muscle (involuntary) and external anal sphincter of skeletal muscles (voluntary). Normally these sphincters keep the anus closed except during elimination of faces.

Histology of Large Intestine

Large intestine consists of following layers:

1. **Serosa:** Outermost layer.
2. **Muscle layer:** Inner layer-circular muscles

Outer Layer – Longitudinal Muscles:

Longitudinal muscles show typical arrangement. These muscles are arranged in 3 bands called as Taeniae coli. This gives puckered appearance to the colon.

1. **Submucosa layer:** Thick layer of areolar connective tissue and contains blood vessels, lymphatics and nerves.

2. **Mucosa layer:** Here, circular folds and villi are absent. It contains large number of goblet cells that secreate mucus and solitary lymph nodes.

Functions of Large Intestine

1. **Production of Certain Vitamins:** Number of microorganisms are found in large intestine like E. coli, E. aerogens, Cl. welchi, S. faecalis. Which synthesize certain vitamins and folic acid.
2. **Absorption of Water, Ions, Vitamins.**
3. **Formation of Feces:** Faeces consists of water, epithelial cells, bacteria and undigested food.
4. **Defecation or Elimination of Faeces from the Body:** Peristaltic movement pushes faecal material from sigmoid colon into rectum. So rectum become distended and stimulates stretch receptors which starts defecation reflex that empties the rectum.

The defecation reflex occurs as follows:

Distension of rectum due to faecal matter

↓

Rectum stimulate stretch receptors

↓

Stretch receptors send sensory nerve impulses to the sacral spinal cord

↓

From sacral spinal cord, motor nerve impulses travel along parasympathetic nerves back to rectum

↓

Resulting in contraction of the longitudinal rectal muscles shortens the rectum By increasing the pressure within it

↓

This pressure and voluntary contraction of diaphragm and abdominal muscles with parasympathetic stimulation open the internal and external sphincter

↓

Resulting in defaecation

Digestion and Absorption of Nutrients

Digestion is the process by which enzymes converts the complex food (carbohydrates, proteins, fats) into simpler form (glucose, amino acids, fatty acids and glycerol) which may be readily absorbed by the cells and utilized for energy.

End products of digestion are:

1. Carbohydrates into glucose (monosaccharides)
2. Proteins into amino acids
3. Fats into fatty acids and glycerol

	Mouth	Stomach	Small intestine with Pancreatic juice and bile		Large intestine
	Digestion	Digestion	Digestion	Absorption	Absorption
Carbohydrates	Salivary amylase Convert polysaccharides (starches) into disaccharides	Hcl stops the action of salivary amylase	1. Pancreatic Amylase- Starches converts into disaccharides. 2. Sucrase, maltase, Lactase- disaccharides to Mono-saccharide (glucose)	Glucose absorbed into blood Capillaries of villi	—
Proteins	—	Pepsin Converts Proteins to polypeptides	Chymotry-sinogen and trypsin converts polypeptides to amino acids	Amino acids absorbed into blood capillaries of villi.	—
Fats	—	—	1. Bile from liver Emulsify, i.e., breakdown of fats. 2. Pancreatic lipase Convert fats into Fatty acids and Glycerol	Fatty acids and Glycerol Absorbed into lacteals of the villi	—
Water	—	Stomach absorbed small amount of water	—	Maximum absorbed here	Remaining Water absorbed here

	Mouth	Stomach	Small intestine with Pancreatic juice and bile		Large intestine
Vitamins		Stomach absorbed Vitamin B_{12} due to intrinsic factor.	—	Water Soluble absorbed into capillaries & fat soluble vitamins absorbed into lacteals of villi	Bacteria synthesize Vitamin K in colon

IMPORTANT QUESTIONS

1. Define digestion. Name the activities in the alimentary canal or GIT.
2. Draw a well labeled diagram showing various parts of alimentary canal.
3. Name the different teeth. How teeth are classified?
4. Draw structure of a tooth and explain.
5. Describe different coats of the stomach.
6. Describe composition and function of gastric juice.
7. Explain digestion in stomach. Give the important functions of stomach.
8. Mention different parts of large intestine. Draw them.
9. Give the composition and functions of intestinal juice.
10. What are the product of digestion and absorption of carbohydrates, proteins, fat? How they reach in blood circulation?
11. Give the composition and functions of Pancreatic juice.
12. Give the composition of bile and functions.
13. Write down the physiology of Liver.
14. Give the structure of Pancreas and its functions.

10

CHAPTER

Muscular System (Skeletal Muscles)

INTRODUCTION

Muscle is the important elemental tissue of the body. Muscles contains muscle cells or fibers, they can contract and relax and produce movement. Thus, muscles perform very vital function of contraction and relaxation.

TYPES OF MUSCLES

There are three types of muscles in our body:

1. **Skeletal or voluntary muscles or striated muscles:** These are attached to the bones and responsible for body movement.
2. **Smooth or voluntary or non-striated muscles:** These are deep in organs like stomach, intestine responsible for contraction and relaxation of the internal organs.
3. **Cardiac or involuntary muscles:** Present in the heart responsible for contraction and relaxation of the heart.

FOUR SPECIAL PROPERTIES OF MUSCLE TISSUE

1. **Electrical excitability:** Responding to stimuli by producing electrical signal called as action potential.
2. **Contractility:** Ability to generate tension to do work. This helps in the movement
3. **Extensibility:** It is the ability to be extended (stretched) without being damaged.
4. **Elasticity:** It is the ability to return to its original length and shape after contraction or extension

Functions of Muscle Tissue

Through contraction and relaxation, muscular tissue performs four important functions:

1. Producing body movements
2. Stabilizing body movements
3. Moving substances within the body and regulating organ volume
4. Generates heat

SKELETAL OR VOLUNTARY MUSCLES OR STRIATED MUSCLES

Skeletal muscles so called because these are attached to the skeleton (bones or bony frame work). These are also called striated muscles because of striations of dark and light bands.

These are also called as voluntary because these muscles are under control of our will.

Skeletal muscle contracts in response to motor nerve impulses originating in the brain or spinal cord, arriving at the neuromuscular junction.

MICROSCOPIC STRUCTURES OF SKELETAL MUSCLE

(Skeletal Muscle Cell/Fibre is the Structural Unit of Skeletal Muscle)

1. Skeletal muscle consists of muscle fibre (muscle cells) which are elongated and often tapering to the end. Such muscle cells are described as muscle fibres. Length of fibers varies from 10 to 40 mm. One single skeletal muscle consists of number of muscle fibres and these are attached to bones by tendons.

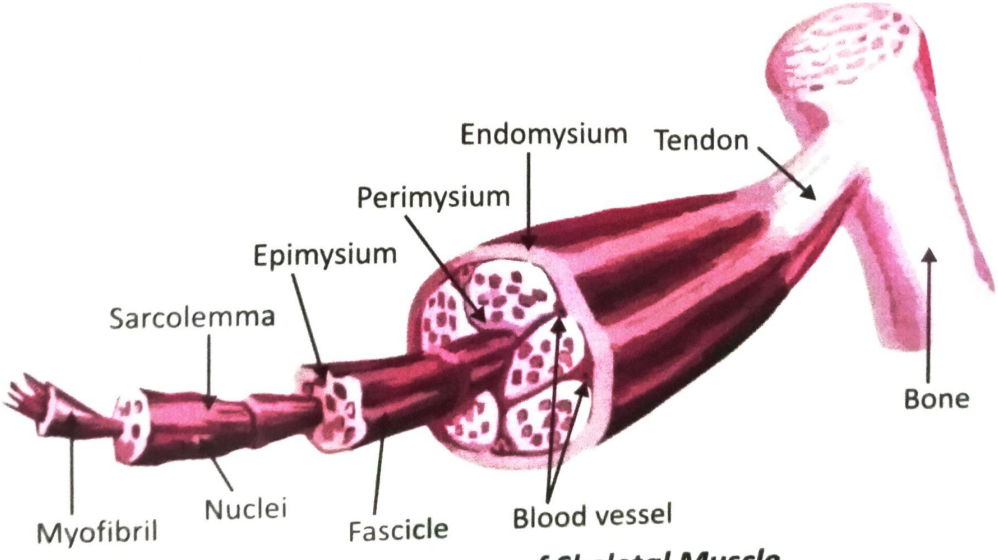

Fig. 10.1: ***Structure of Skeletal Muscle***

2. Each muscle fibre lie parallel to one another and when viewed under microscope, they show transverse dark and light bands called striations, hence, the name striated or stripped muscle.
3. Each muscle fibre is covered by a fibrous connective tissue called endomysium. Bundles of muscle fibres surrounded by connective tissue called perimysium and complete skeletal muscle is covered by a sheath of connective tissue called epimysium
4. Each muscle fibre (muscle cell) consists of cell membrane is called sarcolemma below which several nuclei are situated. Sarcolemma folded back to form sheath called T-tubules, i.e., transverse tubules.
5. The cytoplasm of muscle cells is called sarcoplasm. Sarcoplasm consists little threads called Myofibrils (contractile elements of skeletal muscle). The endoplasmic reticulum (fliud filled membraneous sac) present in the sarcoplasm around the myofibrils is called sarcoplasmic reticulum. It is a store house of calcium during muscle contraction.
6. Myofibrils consists of thin and thick myofilaments arranged in compartments called sarcomeres. Thin filament consists of proteins actin, tropomyosin and troponin where as thick filament consists of protein myosin.
7. The overlapping of thin and thick myofilaments produces striations, i.e., light and dark bands. Light band is called I band or Isotropic band and dark band is called A-band or anisotropic band
8. **Myofibrils composed of three types of proteins:**

   (a) Contractile Proteins: Actin and Myosin

   (b) Regulatory Proteins: Tropomyosin and troponin

   (c) Structural Proteins: Titin, myomesin, nebulin, dystrophin.

ADDITIONAL PROPERTIES OF SKELETAL MUSCLES

1. **Muscle tone (tonos–tension):** Even at rest Muscle exhibits muscle tone, i.e., small amount of tension in the muscle due to weak or involuntary contraction. It is always in a state of partial contraction. It is responsible for a posture of the body.
2. **Muscle fatigue:** Here, muscle contraction is decreased or lost completely is called muscle fatigue.
3. **Twitch:** This type of contraction is rapid jerky response to single stimulus.
4. **Tonicity:** It is a state of normal tension or partial contraction of muscle fibres while at rest.

NEUROMUSCULAR JUNCTION (NMJ) OR TRANSMISSION OF IMPULSE AT NEUROMUSCULAR JUNCTION

1. Neuromuscular junction the connection between skeletal muscle fibre and end of the nerve fibre (neuron).
2. From the skeletal muscle membrane that is sarcolemma, the neuron is passes. The neuron spreads to form many branches called terminal axons. The distal end of terminal axon are expanded into a bulb like structures called as a synaptic end bulb. The synaptic end bulb contains synaptic vesicles which contain a chemical substance (neurotransmitter) acetylcholine (Ach). Which is responsible for the stimulating the muscle fibre. The space between terminal axons and sarcolemma of the muscle fibre is called synaptic cleft.
3. The nerve impulse from neuron is necessary for the contraction of skeletal muscles.

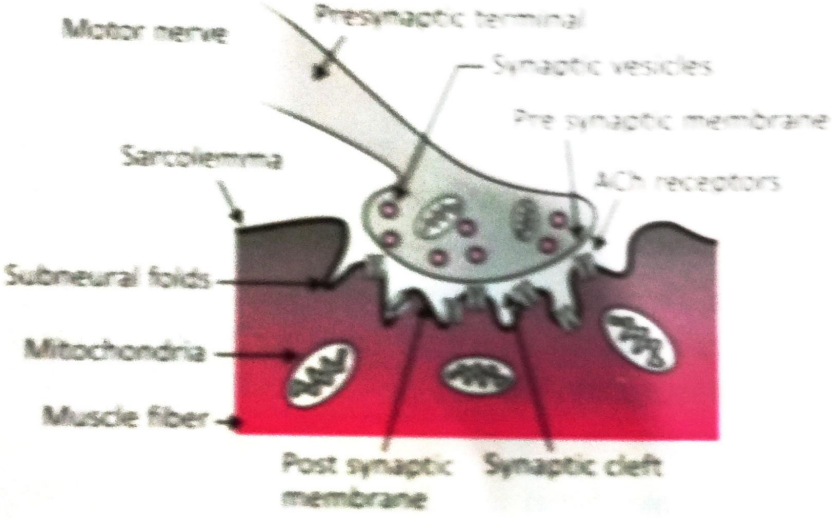

Fig. 10.2: *Neuromuscular Junction*

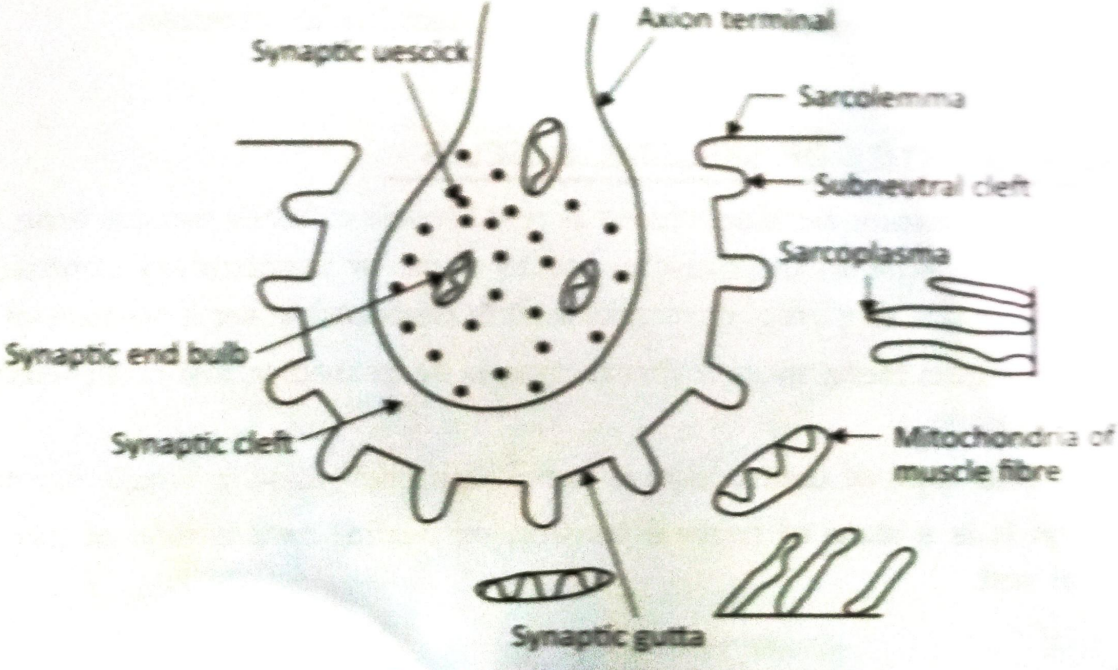

Fig. 10.3: *Synaptic Cleft*

The contraction of skeletal muscles is takes place in the following way:

(i) **Release of Ach:** Nerve impulses reaches to the neuromuscular junction and it produces electrical signal or action potential. This action potential causes small vesicles of Ach to rupture into the synaptic cleft. Now ACh released into synaptic cleft by the process of exocytosis.

(ii) **Activation of Acetylcholine receptors:** Ach binds to Ach receptors. As a result there is inward (inside the skeletal muscle) movement of sodium ions.

(iii) **Production of Action potential in muscle:** The inflow of sodium (Na^+) in the muscle causes generation of action potential or positive charge or depolarization. This action potential then propagates along the sarcolemma and causes release of Ca^{++} ions from sarcoplasmic reticulum into sarcoplasm, so skeletal muscle contracts.

(iv) **Termination of Ach activity:** The Ach is rapidly broken down or degraded by an enzyme called Acetyl cholinesterase. Due to this enzyme, Ach is is converted into Acetyl and choline and terminate the action of Ach. This result into repolarisation or relaxation of muscle. Then there is generation of another impulse. This cycle is repeated.

Nerve impulse
↓
Release of Ach
↓
Generation of action potential
↓
Sodium ions goes inside the muscle and Release of calcium ions in the sarcoplasm
↓
Depolarization & contraction of muscle after contraction,
Ach breakdown by Acetyl cholinesterase
↓
Skeletal muscle relaxation
↓
Physiology of Muscle contraction or events takes place during the contraction & relaxation of skeletal muscles

The skeletal muscle contract when it receives stimuli from motor neuron at Neuromuscular junction. It was observed by researchers that during contraction the thick and thin filament slide over one another. This mechanism is known as the 'sliding filament mechanism'.

Due to propagation of action potential through the sarcoplasm reticulum into cytosol. The calcium binds to troponin and cause troponin –tropomyosin complex to move away from myosin binding site on actin. Due to availability of free binding site the contraction

cycle starts (contraction cycle means repeating sequence of sliding filament). The contraction cycle consists of following steps:

1. **ATP hydrolysis:** The myosin head consist of ATP binding site and an enzyme ATPase. The enzyme ATPase hydrolyzes ATP to ADP and phosphate group. The hydrolysis causes reorientation and energize myosin head.
2. **Attachment of Myosin to actin or Formation of cross bridge:** The energized myosin head bind to myosin binding site on actin. This binding during contraction is known as cross bridges. In this step previously attached phosphate group is also released.
3. **Power stroke:** After formation of cross bridges, the power stroke sliding of thick and thin filament over one another and shortens the sarcomere.
4. **Detachment of Myosin from actin:** At the end of power stroke, the cross bridges remain firmly attached t actin till another ATP molecular binds to ATP binding site on myosin it detaches from actin. The contraction cycle repeats till the calcium level is higher in thin filament. When the nerve stimulation stops, the muscle relaxes. The calcium is pumped back into its Intracellular storage area that is sarcoplasmic reticulum. This breaks the bridge between actin and myosin filament. The thin and thick filament slide back into their starting position, due to which sarcomere returns to original length. The process of muscle contraction can be summarized as follows:

Motor neuron terminal at NMJ

↓

Nerve impulse causes release of Ach at synaptic cleft

↓

Ach diffuses and bind to Ach receptor and trigger action potential in muscle

↓

Action potential generated causes release of calcium in cytosol from SR

↓

Calcium bind to troponin & expose binding site for myosin

↓

Contraction, power stroke

↓

Calcium taken up by SR so decrease in cytosolic calcium

↓

Troponin –tropomyosin complex slide back

↓

Muscles relax

↓

Ach esterase destroy Ach in synaptic cleft so another potential start

DISORDERS OF SKELETAL MUSCLES

1. **Myasthenia Gravis (MG)** is a chronic autoimmune disorder in which antibodies destroy the communication between nerves and muscle (neuromuscular junction), resulting in weakness of the skeletal muscles (fatigue) or failure in muscle contraction.
2. **Muscular Dystrophy** is a group of diseases that cause progressive weakness and loss of muscle mass. In muscular dystrophy, abnormal genes (mutations) interfere with the production of proteins needed to form healthy skeletal muscle.
3. **Myalgia:** Means muscle aches or pain of skeletal muscles.
4. **Myositis:** Means inflammation (Weakness, swelling and pain) in skeletal muscles.
5. **Muscle Strain:** Means tearing or overstretching of skeletal muscles. This usually occurs in sports.

IMPORTANT SKELETAL MUSCLES OF THE BODY

Muscles of the Face

These muscles are involved in changing facial expression and movement such as chewing and speaking. The important muscles of the face are summarized in the following table:

Sr. No.	Name of the Muscle	Description	Function
1.	Occipitofrontalis	Present at the anterior part of frontal bone and over occipital bone. It is flat tendon over skull.	It raises eyebrows.
2.	Levator palpebrae superioris	It extend from posterior part of orbital cavity to upper eyelid.	It raises eyelid
3.	Orbicularis oculi	Surround eye, eyelid, orbital cavity	It closes the eye.
4.	Orbicularis oris	Surrounds mouth	It closes lips
5.	Buccinator	Flat muscles of cheek	Involved in chewing and forcible expulsion of air from mouth.
6.	Masseter	Broad muscle, extend from zygomatic arch to angle of jaw.	Help in chewing and closes jaw
7.	Temporalis	Covers temporal bone	Closes mouth and assists with chewing.
8.	Pterygoid	Extend from sphenoid bone to mandible	Closes mouth, pulls jaw forward.

Muscles of the Neck

Sr. No.	Name of the Muscle	Description	Function
1.	Sternocleidomastoid	Starts from manubrium of sternum and clavicle and extend to Mastiod process of the temporal bone.	It helps head from side to side. Extend head and elevate sternum during forced inhalation.
2.	Trapezius	Covers shoulders, back and neck	It pulls head backwards and controls movement of the scapula when shoulder joint is in the use.

Muscles of the Trunk

Muscles of the trunk are described as muscles of back and muscles of abdominal wall.

1. Muscles of the back: Some muscles are on both sides of the vertebral column.

Sr. No.	Name of the Muscle	Description	Function
1.	Latissmusdorsi (on both sides)	It arises from spinous processes of lumbar and thoracic vertebrae and extend to humerus.	It helps in the movement of arms such as rotation extension and adduction.
2.	Teres Major (on both sides)	It originates from inferior angle of scapula and extends to just below the shoulder joint.	It helps in the movement of the arms.
3.	Quadratus lumborum (on both sides)	It originates from the iliac crest (hip bone) then passes upward, parallel and close to vertebral column and it is inserted into 12th rib.	Together the two muscles fix the lower rib during respiration and cause extension of the vertebral column (bending backwards)
4.	Sarcospinalis (erector spinae)	This is a group of muscles lying between the spinous and transverse processes of the vertebrae. They originate from the sacrum and are finally inserted into the occipital bone	They cause the extension of vertebral column.

2. Muscles of the Abdominal Wall:

Sr. No.	Name of the Muscle	Description	Function
1.	Rectus abdominis muscle	It is broad and flat, originating from the transverse part of the pubic bone and extend to xiphoid process of sternum.	It compresses the abdominal organs.
2.	External oblique	Extend from lower rib to iliac crest.	It compresses the abdominal organs
3.	Internal oblique	These muscles lie deep to the external oblique. The fibres form right angle to external oblique muscle.	It compresses the abdominal organs.
4.	Tranverse abdominis	This is the deepest muscle of abdominal wall. Its fibres arise at right angle to rectus abdominus.	It compresses the abdominal organs
5.	Inguinal canal/ ligament	Inguinal ligament passes obliquely through the abdomen wall. It is 2.5-4 cm long and is weak part of the abdominal wall.	It compresses the abdominal organs

Muscles of the Pelvic Floor

Sr. No.	Name of the Muscle	Description	Function
1.	Levatorani	This is a pair of broad flat muscles, forming the anterior part of the pelvic floor.	It supports organs of pelvis and help to maintain continence that is resist increased pelvic pressure during micturition and defecation.
2.	Coccygeus	It is a paired triangular sheet of muscle Situated behind the levatorani.	Same as above.

Muscles of the Shoulder

Sr. No.	Name of the Muscle	Description	Function
1.	Subclavius	It is anterior thoracic muscle, originated in the first rib and insert into clavicle.	It helps to move clavicle anteriorly and helps to stabilize shoulder girdle.
2.	Pectoralis minor	An anterior thoracic muscle originates from second to fifth rib and extends to coracoids process of scapula.	Rotates scapula downward and elevates ribs during forced inhalation.
3.	Serratus anterior	An anterior muscle originating at superior eight/nine rib and insert at inferior angle of scapula and border of vertebral column.	Rotates scapula upward and elevates ribs
4.	Trapezius	A posterior muscle. It orinates at superior notch of occipital bone, spines of the seventh cervical and thoracic vertebrae and inserts.	Help to elevate scapula, help to extend head, rotate scapula upward and stabilize scapula.
5.	Levator scapulae	A posterior thoracic muscle originating at superior 4th or 5th cervical vertebrae and inserting to superior vertebral border of scapula.	Helps in the elevation of scapula and rotation in downward direction.

Muscles of the Upper Limb

Sr. No.	Name of the Muscle	Description	Function
1.	Deltoid muscle	It is a scapular muscle and originate at acromian extremity of clavicle and inserts at deltoid tuberosity of humerus.	Rotates the shoulder joint.
2.	Biceps	lies on the anterior aspect of the upper arm.	Flexion of elbow and shoulder joint.
3.	Triceps	Lies on the posterior aspect of the upper arm.	Extension of elbow and shoulder.
4.	Coraco brachialis	starts at coracoids process of scapula and lies on the upper medial aspect of the arm.	Helps in the flexion and adduction of arm at elbow joint.

Muscles of Hip & Lower Limb

Muscles of hip & lower limb help in the movement of hip and lower limbs such as bending forward/backward rotation of hip, walking and running.

Sr. No.	Name of the Muscle	Description	Function
1.	Psoas	It originates at the bodies of lumbar vertebrae and inserts into lesser tronchanter of femur.	It help in the flexion of thigh at hip joint, rotate thigh laterally and flaxiox of the trunk on the hip in sitting and sleeping position.
2.	Iliacus	It originates at iliac fossa and sacrum and inserts into lesser tronchanter of femur.	Extension of thigh at hip joint and laterally rotates the thigh.
3.	Gluteus medius	It originates at ilium and inserts into greater tronchanter of femur.	It abducts thigh at hip joint and rotates it medially

Muscles of the Lower Limb

Sr. No.	Name of the Muscle	Description	Function
1.	Quadriceps femoris	It orignates at iliac spine and head of femur.	It helps in the extension of leg at knee joint and flexion of thigh at the hip joint.
2.	Sartorius	This is the longest muscle in the body. It originates from anterior superior iliac spine and passes obliquely across the hip joint, thigh and knee joint, inserted into the medial surface of the upper part of the tibia.	Flexion of leg at knee joint and lateral rotation of thigh.
3.	Hamstrings	These lie on the posterior aspect of the thigh.	Flexion and extension of leg.
4.	Soleus	This is one of the main muscles of the calf of the leg, originates from the head and upper part of the tibia, fibula.	It causes plantar flexion at the ankle and helps to stabilize the joint when standing.

IMPORTANT QUESTIONS

1. Give the microscopic structure of skeletal muscles. (W-97, 98; S-03)
2. Give the physiology of muscular contraction. (W-97, 98, 00, 01; S-00)
3. Name the three muscles of facial expression with their attachment and functions. (S-96; W-96)
4. Define following properties of skeletal muscles-tonicity, fatigue. (W-98)
5. Explain neuromuscular junction in short. (S-02)
6. What is muscle tone? Give the functions of muscle. (S-97, 01; W-96)

11

CHAPTER

Nervous System

FUNCTIONS OF NERVOUS SYSTEM

1. All body's all activities voluntary (e.g., walking), involuntary (e.g., heartbeat) are controlled by Nervous system.
2. Sensation, Integration and response to changes inside and outside the body.
4. Nervous system is the center of all mental activities including thought, learning and memory, emotions.
3. Together with endocrine system it controls body functions (Hypothalamus and pituitary gland).

Nervous system regulates various activities of body by responding rapidly using nerve impulses (action potential) where as the endocrine system responds more slowly by releasing different hormones from glands.

NEURON

Neuron/Nerve cell is a structural and functional unit of Nervous system.

The neurons or nerve cells conduct electrical signals, i.e., electric impulses that passes information to other nerve cell, muscles, glands and the brain, spinal cord.

The different parts of neuron are as follows:

Neurons have three parts – cell body, axon and dendrites.

1. **Nerve cell body:** It contains nucleus and some organelles such as Mitochondria, Golgi apparatus, Endoplasmic reticulum, ribosomes. It has slight gray appearance.

2. **Dendrites:** These are the short fibers or processes on the cell body. Dendrites of one neuron receives electrical impulses from other neurons and then transmit these impulses towards the cell body of other neuron. Each neuron has many dendrites.

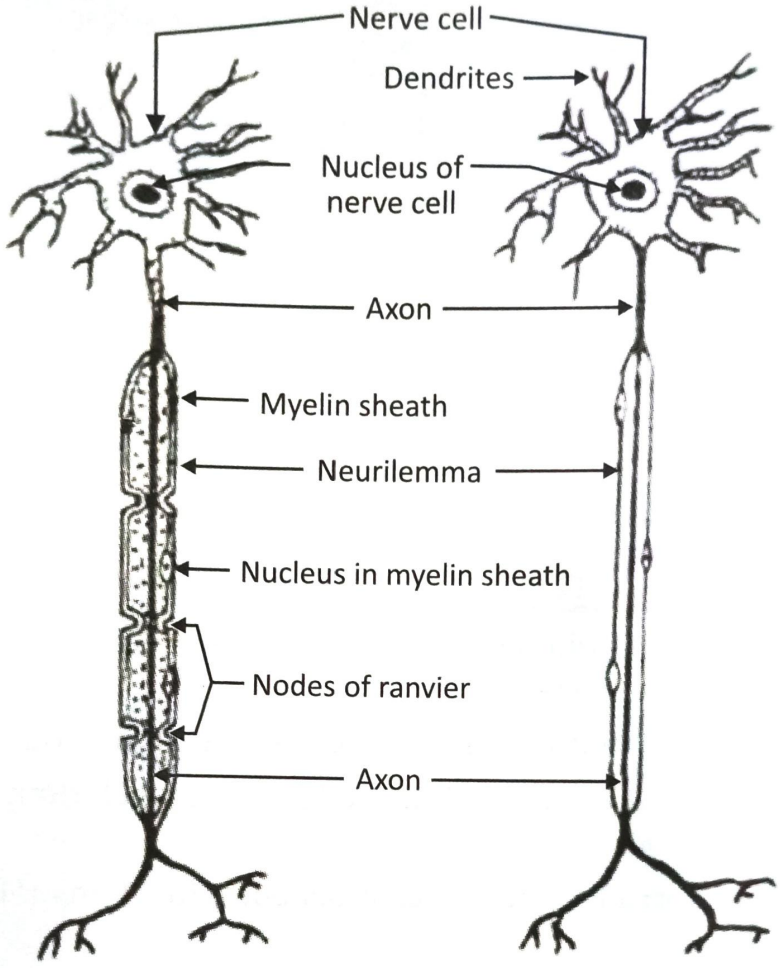

(a) Myelinated neuron **(b) Non-myelinated neuron**

Fig. 11.1: ***Neuron***

3. **Axon:** Axon is a long fiber arise from the cell body. Each nerve cell has only one axon which carries impulses away from the nerve cell body. The axon ends by dividing into many fine processes called axon terminals which have bulb like structure, i.e., synaptic knob. Inside the synaptic knob bag like structure known as synaptic vesicles which contain neurotransmitter.

The plasma membrane of axon is known as axolemma and cytoplasm inside is called axoplasm.

Some neurons are enveloped with lipid rich sheath called myelin sheath around them so called myelinated neurone. They are found in spinal and cranial nerves. Myelinated neuron:

(i) Conduct nerve impulse fastly through axon.

(ii) Prevent the leakage of nerve impulse (biological insulator)

(iii) Also protects axon from injury.

Myeline sheath is as produced by of Schwann cells which are lipid rich cells. Myelin sheath is covered by a nucleated membrane called neurilemma. Some neurons are enclosed by Schwann cells but they do not produce a myelin sheath, they are called as Non-myelinated neurone. It contains only neurilemma and due to absence of myelin sheath it conduct nerve impulse slowly.

The gaps which are present between two Myeline sheaths are called as Nodes of Ranvier. They provide nourishment to the neuron. The group of neurons is called as a nerve.

CLASSIFICATION OF NERVOUS SYSTEM

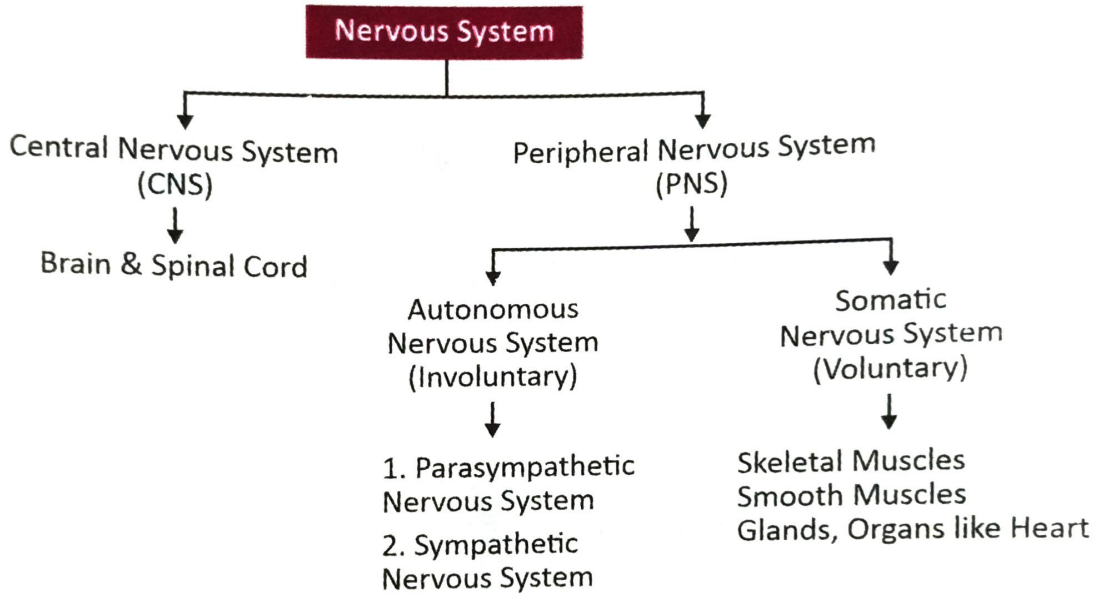

Nervous system divided into:

A. The Central Nervous System (CNS) consisting of brain and the spinal cord.

CNS is responsible for sensory information, e.g., thoughts, memories, emotions.

B. The Peripheral Nervous System (PNS) lies along the peripheries of the body. It consisting of all the nerves outside the brain & spinal the cord. A nerve is formed by the collection of many neurons (nerve fibres).

Neurons (Nerve Fibres) of the PNS are of two types:

(a) **Sensory Neuron or Afferent Fibres:** Its function is to carry the impulse or sensory information from various tissue or organs to CNS so that CNS can accordingly respond and control the body.

(b) **Motor Neuron or Efferent Fibres:** Its function is to carry the impulse or regulatory information from CNS to peripheral tissue or organs through which the response of the body is shown.

Divisions of PNS

1. **Somatic Nervous System:** It consists of motor neuron transmits impu regulatory information from CNS to skeletal (voluntary) muscles.
2. **Autonomous Nervous System:** It consists of motor neuron transmits impu regulatory information from CNS to smooth muscles (involuntary) organ glands of the body.

Autonomous nervous system consists of Parasympathetic and Sympathetic ner system.

CENTRAL NERVOUS SYSTEM (CNS) – BRAIN AND SPINAL CORD

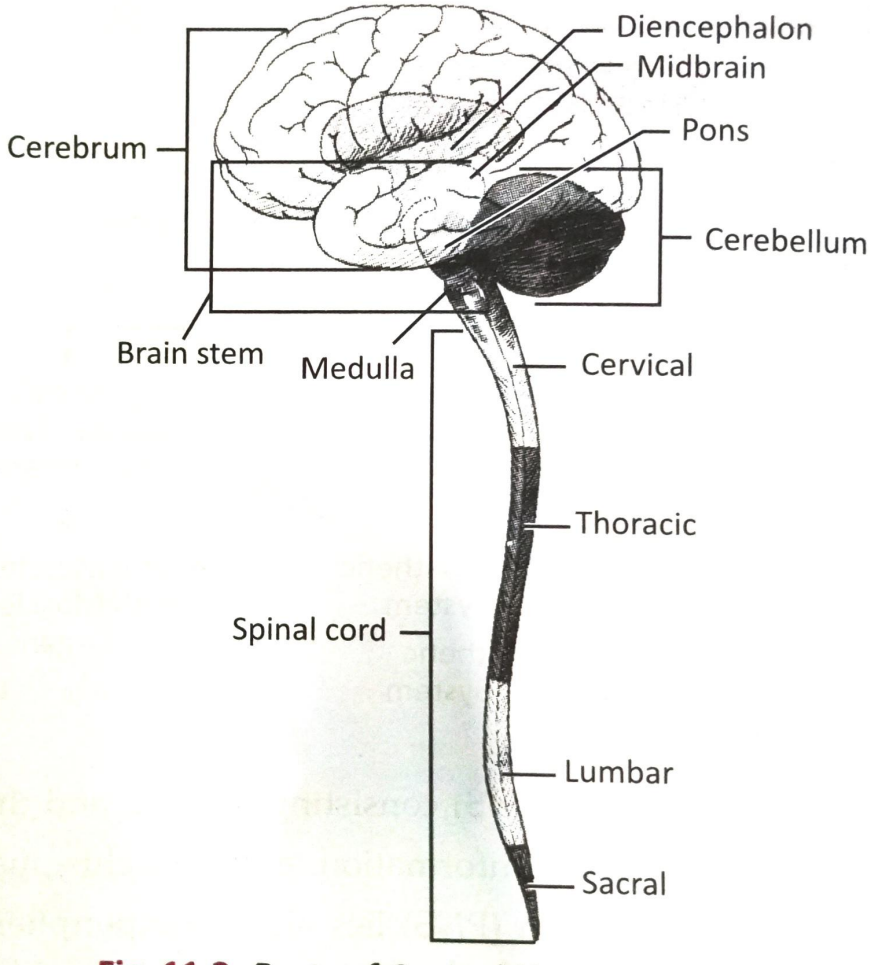

Fig. 11.2: ***Parts of Central Nervous System***

1. Brain has a soft and delicate structure and looks like a walnut. It has wrin surface and situated in the cranial cavity. Its weight is about 1 kg.
2. It consists of Cerebrum, Midbrain, Pons Varolii, Medulla oblongata, Cerebel
3. Brain and Spinal cord is covered by protective covering called Meninges between the brain and the skull. Meninges are three in number:
   (i) **Outer Duramater:** It is thick and tough outer layer made up of a t connective tissue called as fibrous tissue.

(ii) **Middle Arachnoid:** It thin middle layer made up of delicate connective tissue.

(iii) **Inner Piamater:** It is contact with brain. It thin layer and highly vascular.

The space between Duramater and Arachnoid membrane is called subdural space.

The space between Arachnoid and Piamater membrane is called subarachnoid space which contains Cerebrospinal Fluid (CSF)

4. **Functions of meninges are:**
   (a) To protect and support nervous tissue.
   (b) To supply blood and nourishment to central nervous tissue.
5. Brain consists of fluid filled spaces called ventricles. Total four ventricles are present in the brain. Ventricles filled with fluid, i.e., is Cerebrospinal Fluid (CSF). These are lateral left and right ventricles lies inside the hemisphere of the cerebrum.

Third ventricle present at the area of thalamus. Fourth ventricle lies at the central canal of the spinal cord. In the walls of ventricles, there are networks of capillaries called choroid plexues. Which secretes cerebrospinal fluid.

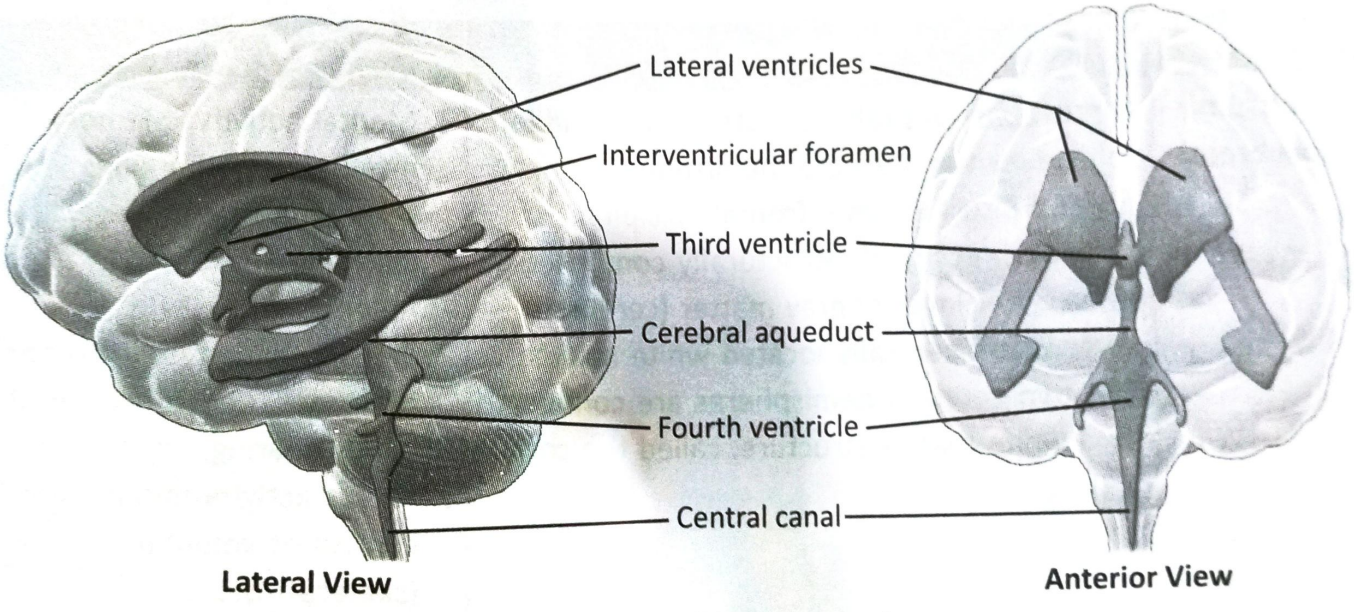

Fig. 11.3: ***Ventricles of the Brain***

CEREBROSPINAL FLUID (CSF)

1. Cerebrospinal Fluid (CSF) is a clear colourless liquid that protects the brain and spinal cord from chemical and physical injuries. It carries oxygen, glucose and cations (sodium, potassium, calcium and magnesium) and anions (Chloride and bicarbonates) from blood to neurons. CSF continuously circulates through the cavities of in the brain.
2. **Composition:** Total volume of CSF is 80 to 150 ml in an adult. It is clear, slightly; alkaline fluid with a specific gravity of 1.005. The normal hydrostatic pressure of

CSF is 130 mm of water (10 mm of Hg). It consists of glucose, proteins, urea, lactic acid, cations (sodium, potassium, calcium, magnesium) and anions (chloride and bicarbonates), white blood cells.

3. **Functions:**

(i) **Protection:** It acts as shock absorber and protects the brain and spinal cord from chemical and physical injuries. Due to CSF, brain floats in the cranial cavity.

(ii) **Circulation:** CSF supplies nutrients to the brain and spinal cord and removes waste from the brain and spinal cord

(iii) **Moisturization:** It keeps the brain and spinal cord moist.

(iv) **Maintains of Uniform Pressure:** It maintains uniform pressure and ionic balance around the brain and spinal cord.

PARTS OF CENTRAL NERVOUS SYSTEM

Part	Anatomy	Physiology
Cerebrum (Forebrain)	Largest part of brain consists of right and left folds, i.e., two Cerebral hemispheres which divided into 4 lobes – frontal, occipital, temporal, occipital. Structurally composed of an outer layer of gray matter (cerebral cortex) and centrally located white matter. The two cerebral hemispheres are connected by a white matter structure, called the corpus callosum.	1. Mental activity: Memory, intelligence, thinking, reasoning moral sense, learning, sense of responsibility. 2. Sensory activity: Perception of senses, i.e., Touch, smell, taste, hearing, sight. 3. Motor activity-initiation and control of voluntary (skeletal) muscle contraction.
Basal Ganglia	It is present as a group of nerve cells deep in the Cerebrum.	1. To regulate initiation and termination of movements. 2. To regulate muscle tone required for specific body movements. 3. Control the subconscious contraction of skeletal muscles, e.g., automatic arm swings while walking.

Part	Anatomy	Physiology
Thalamus	It is an oval structure present in the middle of each cerebral hemisphere of cerebrum.	Acts as a relay centre, i.e., sensory messages must pass through the thalamus then reach to the brain. All motor messages from brain must pass through the thalamus. Thus it is major coordinating centre for sensory and motor signaling.
Hypothalamus	It is situated below and infront of thalamus.	1. Control of ANS: Through the autonomic nervous system, hypothalamus regulate visceral activities like heart rate, movement of food through G.I.T. contraction of urinary bladder. 2. Production of Hormones 3. Regulation of emotional and behavioral patterns, e.g., aggressions, pain, pleasure sexual behavior 4. Regulation of eating and drinking. 5. Control of body temp. by promoting heat loss or heat retention Thus act as a thermostat. 6. Regulation of circadian rhythms i.e., biological clock of body and state of consciousness, e.g., awakening and sleep pattern.

Part	Anatomy	Physiolo
Cerebellum	Situated below the posterior portion of cerebrum occupying the posterior cranial fossa. It is ovoid in shape and has 2 hemispheres separated by median strip called vermis.	1. It doe move move smoo move hand 2. Main Balai the 3. Play lang
Pons	Pons consists of fibre tracts (bundle of nerve fibres) that connect different regions of brain.	Pons a cerebr It cons centre respir
Medulla oblongata	Posterior part that connects various part of the brain and the spinal cord.	*Medu* **1. Car** reg rhy co of **2. Re** Re of **3. Va** si v v **4. F** s

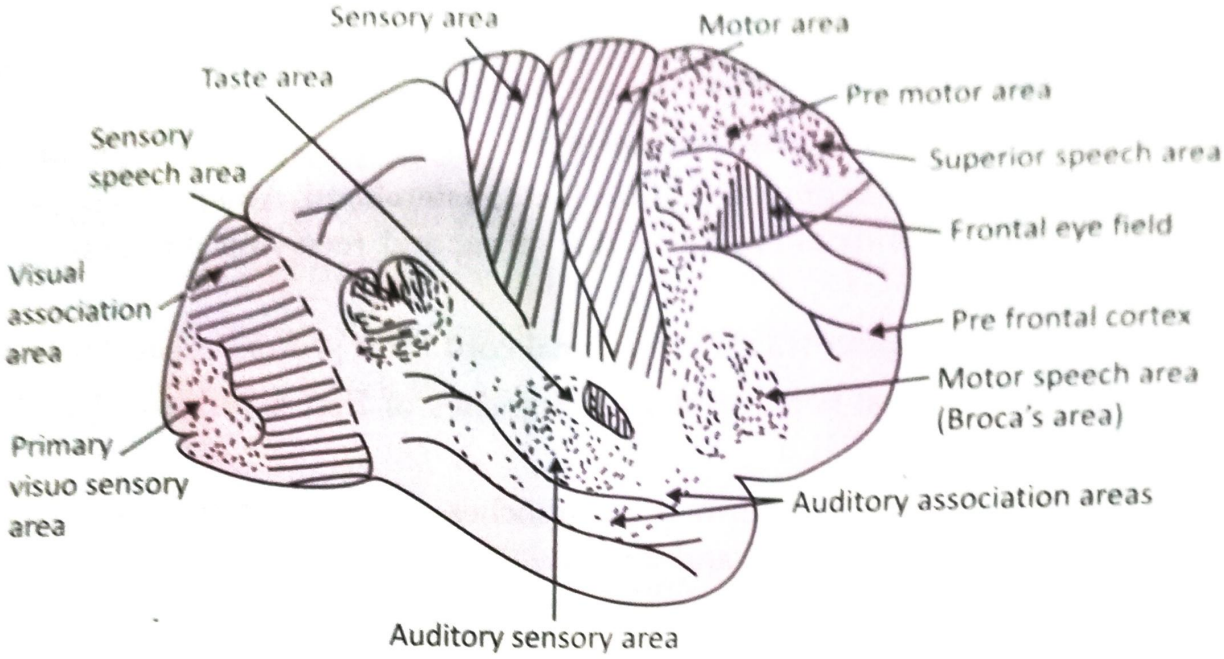

Fig. 11.4: ***Functional area showing of the Cerebellum***

SPINAL CORD

1. It is elongated and most cylindrical part of the CNS. It is situated in the neural canal of the vertebrae.
2. It starts from atlas above to the first lumbar vertebra below.
3. It continues with the medulla oblongata.
4. It is about 45 cm long and is about the thickness of the little finger. It is surrounded by dura, arachnoid and piamater. CSF (Cerebrospinal Fluid) is present in the central of the spinal cord and subarachnoid space.
5. It is link of nervous tissue between the brain and other organs of the body.
6. 31 pairs arise from the spinal cord which is known as spinal nerves. Each nerve has a posterior and anterior nerve root. 8 pairs of cervical nerves, 12 pairs of thoracic nerves, 5 pairs of lumbar nerves, 5 pairs of sacral nerves and 1 pairs of coccygeal nerve.
7. The lumbar, sacral and coccygeal nerves leaves the spinal cord before its termination and extends vertically below, thus, having the appearance like wisps of hair called as cauda equine
8. Spinal cord divided into two equal parts, anteriorly by shallow median fissure and posteriorly by posterior median septum. T.S. of spinal cord shows grey matter shaped like the letter H and is surrounded by white matter. The gray matter consists of sensory nerve fibre or neurone (which receive sensory impulses from periphery of body) connector and motor nerve fibre or neuron (which carry

motor impulses to the skeletal muscle or effector organs in which response shown). Gray matter is responsible for reflex action.

9. In the centre, there is a central canal which contains cerebrospinal fluid.
10. The white matter is arranged in three bands-lateraband, Anterior band, Posterior band. It also contains nerve fibres delivering and receiving information to and from the brain.
11. The spinal nerves after leaving the spinal cord form groups called plexuses.
    (i) **Cervical Plexus:** It is formed by branches of first 4 cervical spinal nerves (C1-C4)
    (ii) **Brachial Plexus:** It is formed by branches of last 4 cervical nerves and first thoracic nerves. (C5-C8 and T1)

    In thoracic region plexus is not formed but there are 12 pairs of thoracic nerves distributed to the intercostals muscles.
    (iii) **Lumbar Plexus:** It is formed by branches of lumbar nerves. (L1-L4)
    (iv) **Sacral Plexus:** It is formed by branches of lumbar nerves (L4-L5) and sacral nerves (S1-S4)

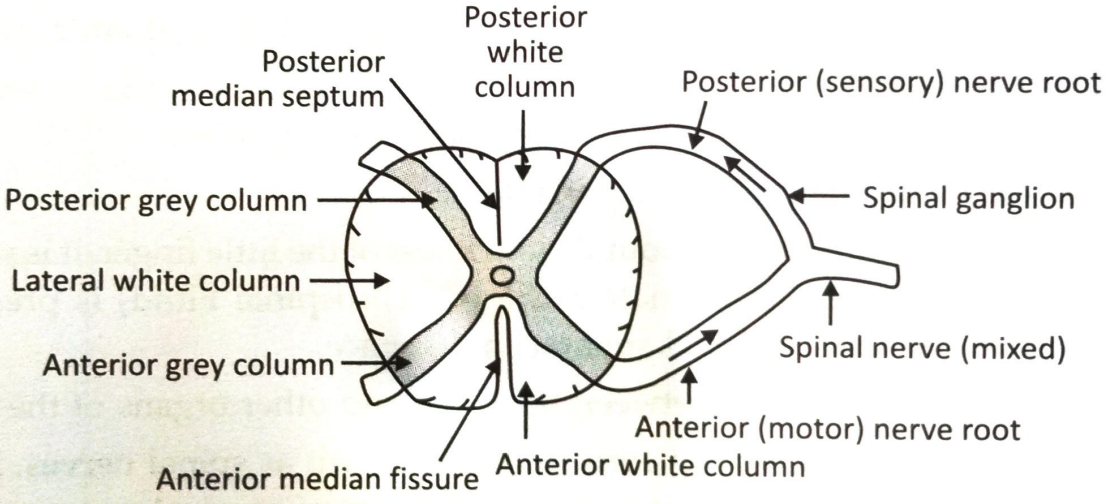

Fig. 11.5: ***T.S. Section of Spinal Cord***

12. **Functions of Spinal Cord:**
    (i) It is the connection between the peripheral organs and the brain.
    (ii) Spinal cord gives reflex action.

REFLEX ACTION

Definition

Reflex action is the rapid (fast) automatic motor response to the sensory stimulus given by the spinal cord without involving our brain.

Most of the reflex actions are protective in nature. Reflex actions are the part of defense mechanism of the body and occur very fastly.

The important reflex action are:

1. Quick closing of an eye lid if the eye is touched with something.
2. Quick recovery of the balance of the body to prevent falling after a slip.
3. Sudden withdrawal of the hand if the fingers touched with something hot.
4. Sudden coughing attack if a any particle is inhaled.

Reflex Arc

1. The structure which is responsible for reflex action is called as reflex arc.
2. **Anatomy of Reflex arc or reflex pathway:**

   (a) Sensory Receptors: Means nerve endings present in the skin detect stimulus. e.g., Hot object.

   (b) Sensoryneurone: It is afferent nerve (goes to spinal cord). It carries sensory impulses from skin (sense organ) to spinal cord via posingaterior nerve root.

   (c) Connector Neurone: It is acting as a association neurons in between sensory and motorneurons and carries away the impulses.

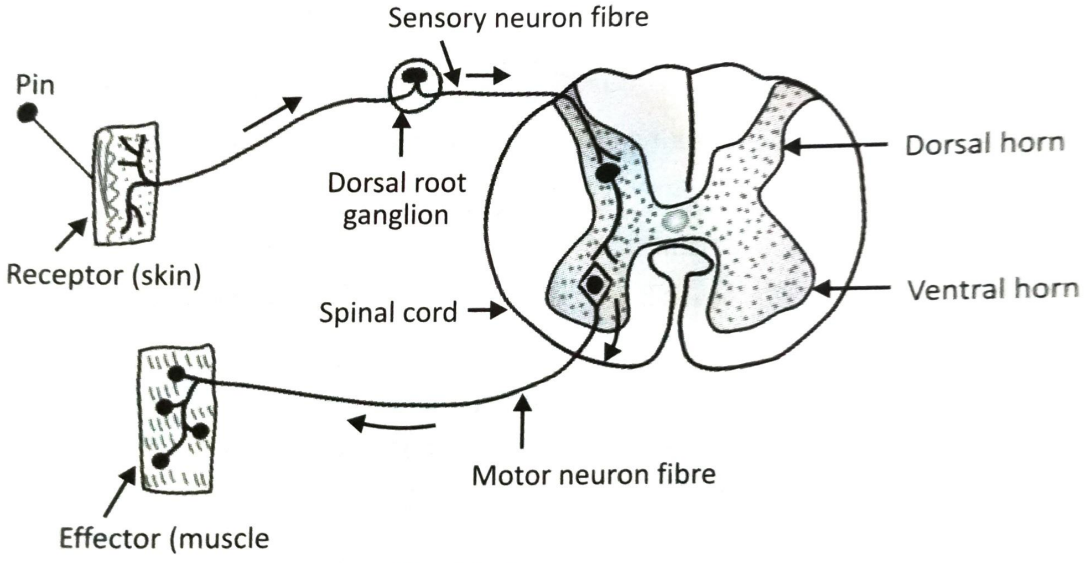

Fig. 11.6: ***Reflex Arc***

(d) Motor Neuron: It carries nerve impulses to the effectors or skeletal (striped) muscles in which responses will be shown.

(e) Effectors: It is the organ of the body which responds to the motor impulse.

The response of the effector organ is called as a reflex.

PERIPHERAL NERVOUS SYSTEM (PNS)

1. PNS is constituted by the nerves which arise from the brain and spinal cord. They are called Cranial and spinal nerves.
2. PNS is subdivided into Somatic nervous system and autonomus nervous system.

Autonomus Nervous System

1. Generally ANS consists of motor fibre and controls the visceral organs and hence named as visceral nervous system.
2. The function of ANS is to control and coordinate the activities of visceral organs. Its Parasympathetic and Sympathetic nerves work against one another. It consists of 2 neurons Preganglionic and Postganglionic neurone.

Central Nervous System	Autonomic Nervous System
1. CNS makes persons aware of external environment and thus, it is mainly related with receiving the sensations from external environment, interpretation of senses and response to the received sensations.	1. ANS makes persons aware of internal environment It is related with the activities visceral organs like heart, various glands and the smooth muscles
2. It enable a person to adjust with external environment, e.g., thinking, learning.	2. It enables the person to adjust with internal environment. Heart rate. B.P
3. The function of CNS occur according to the will power of the person, e.g., thinking, learning	3. The functions of ANS do not occur according to the will power of the person Heart rate. B.P
4. It consists of sensory and motor nerves. Sensory nerves sent nerve impulse from sense organs to brain and from brain motor nerves sent nerve impulse to the sense organ.	4. It consists of Parasympathetic and sympathetic nerves and both nerves goes to smooth muscles of visceral organs, e.g. heart G.I.T.
5. Nerves of CNS work in coordination, e.g., reflex action.	5. Nerves of ANS work against one another e.g., sympathetic nerve increases heart rate and Parasympathetic nerve decreases heart rate.

Parasymphathetic Nervous System	Symphathetic Nervous System
1. It participate in tissue building.	1. It enables the individual to adjust to stress condition.
2. Preganglionic neurons in the cranial nerves (III, VII, IX, X) and sacral nerves also post ganglionic fibres terminate in the visceral organs. So called Cranio sacral outflow.	2. Preganglionic neurons in thoracic and lumbar spinal nerves and post ganglionic fibres terminate in the visceral organs. So called thoracolumbar outflow.
3. It originates in cranial and sacral region of the spinal cord.	3. It originates in thoracic and lumber region of the spinal cord.
4. Parasympathetic Ganglia (small masses of nervous tissue) are situated near the effector or visceral organ.	4. Sympathetic Ganglia (small masses of nervous tissue) are situated near the spinal cord.
5. Long preganglionic fiber	5. Short preganglionic fiber
6. Short post ganglionic fiber	6. Long post ganglionic fiber
7. Also known as Cholinergic system	7. Also known as Adrenergic system
8. It is a peace maker which allow Restoration processes to occur quietly	8. It prepares body for fight and flight Response (stress condition)
9. Neurotransmitter within Parasympathetic Ganglia and at terminal synapse is acetylcholine.	9. Neurotransmitter within sympathetic Ganglia is acetylcholine and at terminal synapse is either adrenaline or noradrenaline.

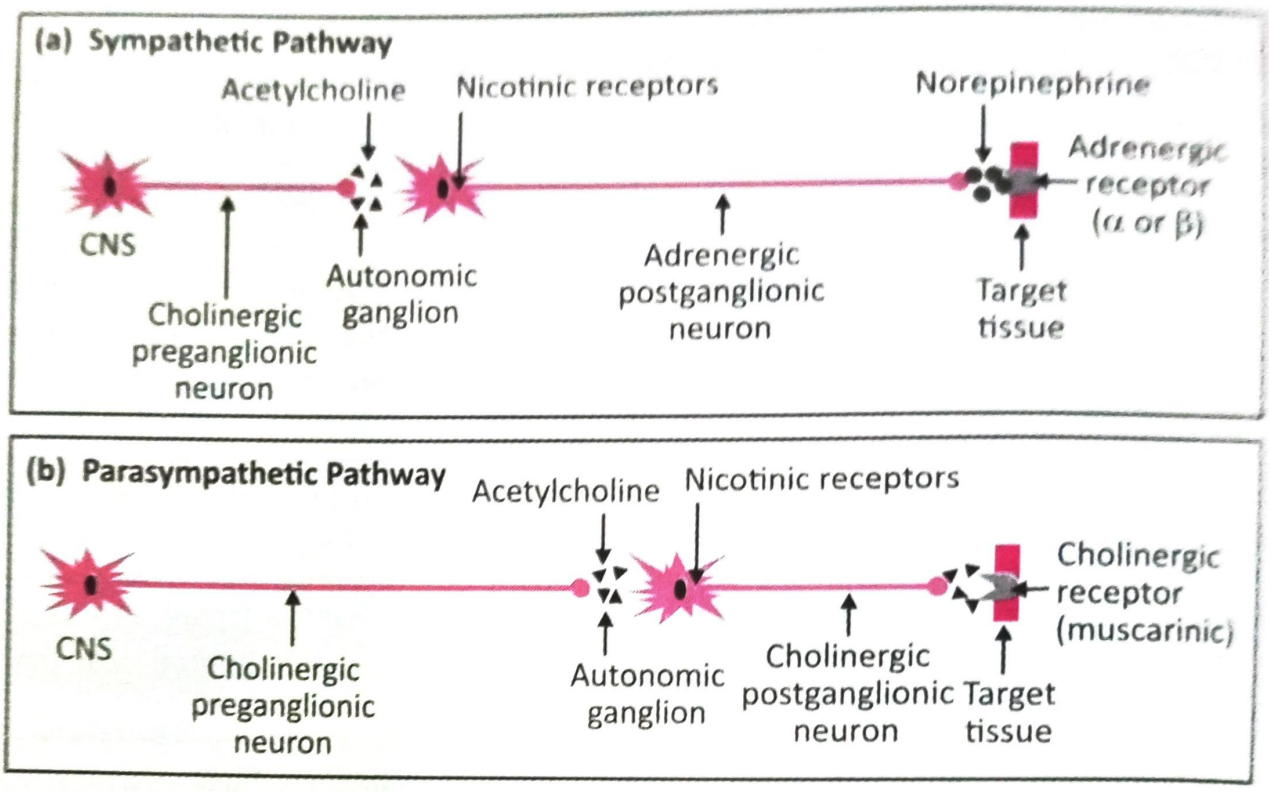

Fig. 11.7: ***Anatomy of Autonomous System***

ANATOGONISTIC ROLE OF PARASYMPATHETIC AND SYMPATHETIC NERVOUS SYSTEM

	Parasympathetic Stimulation	Sympathetic stimulation
1. Eyes	Miosis-constriction of pupil and accommodation of lens for near vision	Mydrasis-dilatation of Pupil and accommodation of lens for longer vision
Lacremal glands	Increases secretion of lacreal glands	No effect
2. Respiratory track-bronchi	Bronchoconstriction (broncho-spasms) Increases bronchial secretion	Bronchodilatation
3. Heart	Slows the heart rate and decreases force of contraction.	Increases the heart rate and force of contraction
4. Blood vessels:		
• **Coronary artery**	Coronary blood vessels constricts Coronary vasoconstriction	Coronary blood vessels dilates Coronary vasodilation
• **Skeletal blood vessels**	Skeletal blood vessels constricts (vasoconstriction)	Skeletal blood vessels dilates (vasodilation)

	Parasympathetic Stimulation	Sympathetic stimulation
• Other blood vessels	Other blood vessels dilates (Vasodilation)	Other blood vessels constricts Vasoconstriction
5. Digestive system G.I.T.	Increases G.I.T. motility	Decreases G.I.T. motility
6. Glands • Sweat glands	No innervations	Increases sweating
• Salivary glands	Increase salivation	Decrease salivation
• Gastric glands	Increase secretion of gastric juice.	Decrease secretion of gastric juice.
• Gall bladder	Stimulate bile flow	Inhibits bile flow
7. Liver or metabolic effect	No effect	Increases metabolism and liver releases glycogen and convert into glucose.
8. Kidney– Adrenal glands	—	Stimulates adrenal glands to secrete adrenaline and nor adrenaline.
9. Urinary bladder	Contract urinary bladder and Micturition (Urination)	Relaxes urinary bladder.

SPINAL NERVES

The peripheral nervous system consisting of Periphery of the body starts from vertebrae.

There are 31 pairs of spinal nerves:

1. Cervical nerves _____ 08
2. Thoracic nerves _____ 12
3. Lumbar nerves _____ 05
4. Sacral nerves _____ 05
5. Coccygeal nerves _____ 01

CRANIAL NERVES

12 pairs of cranial nerves-starts below cranium or skull Sensory type responsible for sensation and motor type responsible for muscle contraction (movement of any organ).

Number	Name	Type	Function
1 or I	Olfactory nerves	Sensory	Sense of smell.
2 or II	Optic nerves	Sensory	Sense of sight.
3 or III	Occulomotor	Mixed (Sensory & Motor)	Giving sensation to the muscles of eyeball, Movement of eyelids and eye ball, lens.
4 or iv	Trochlear	Mixed (Sensory & Motor)	Giving sensation to the muscles of eyeball, movement of eyelids and eye ball, lens.
5 or IV	Trigeminal	Mixed (Sensory & Motor)	Sensation of touch, pain, temperature, movement of jaw muscles for chewing.
6 or VI	Abducens	Mixed (Sensory & Motor)	Giving sensation to the muscles of eyeball, movement of eyelids and eye ball, lens.
7 or VII	Facial	Mixed (Sensory & Motor)	Sensation of taste, facial expression, movement of neck.
8 or VIII	Vestibulocochlear	Sensory	Sensation of sound, i.e., hearing, maintenance of balance and equilibrium.
9 or IX	Glassopharyngeal	Mixed (Sensory & Motor)	Sense of taste movement of pharynx during swallowing
10 or X	Vagus	Mixed (Sensory & Motor)	Sensation of taste, touch, pain temp. and peristaltic movement and swallowing, secretion of gastric glands, coughing and voice production.
11 or XI	Accessory	Mixed (Sensory & Motor)	Sensation and movement of head, shoulder.
12 or XII	Hypoglossal	Mixed (Sensory & Motor)	Movement of tongue during speech and swallowing.

IMPORTANT QUESTIONS

1. Draw a well labelled diagram of brain showing its parts. (S-01)
2. What are meninges? Write their names. (S-96, 01, 02; W-00)
3. Describe the function of cerebrospinal fluid. (S-96, 00; W-99, 01)
4. Draw a well lebelled diagram of cerebrum and explain showing functional areas of cerebrum. (S-00; W-00, 01, 02)
5. Give the functions of cerebrum. (S-96; W-96, 99, 01)
6. What is basal ganglia? Give its function. (S-97; W-98)
7. What is thalamus? Give its function. (S-98)
8. Write a note on hypothalamus. Give its functions. (S-98; W-96, 98, 00, 02)
9. Describe medulla oblongata. Give its functions. (S-01, 03; W-97)
10. Describe cerebellum and its functions. (S-02, 03; W-96)
11. Name the different cranial nerves. (S-96, 03)
12. Draw a neat sketch of T.S of spinal cord and label it. (S-97, 98, 02, 03; W-99)
13. What is Cauda Equina? (W-01)
14. What is plexus? Name the different plexuses. (S-97)
15. What is reflex action? Give the structure of reflex arc. (W-97; 99, 01)
16. What is autonomic nervous system? (S-97)
17. What are the two divisions of ANS? Explain their relationship with one another. (S-03)
18. Discuss the anatomy of ANS. (W-97; S-01)
19. Write the effect of sympathetic stimulation on salivary gland, heart and eye. (S-96, 97, 00; W-98, 99, 02)
20. Write the effect of sympathetic stimulation on respiratory system, digestive and urinary system. (S-96, 97; W-98, 02)
21. What will be the effect of stimulation of sympathetic stimulation on heart, eye, blood vessels and G.I.T.? (W-02)
22. Describe the effect of Parasympathetic stimulation of digestive and urinary system. (W-97, 01)
23. What is the effect of Parasympathetic stimulation on Heart? (S-97)

12
CHAPTER

Sense Organs

FIVE SPECIAL SENSE ORGANS

1. **Eye:** Sight
2. **Ear:** Hearing
3. **Skin:** Touch
4. **Tounge:** Taste (Refer Chapter 9)
5. **Nose:** Smell (Refer Chapter 8)

EYE AND SIGHT

EYE

It is a sensory organ of vision that resembles a camera. It is a globe or sphere of about 2.5 cm in diameter with a transparent membrane in the front. Eye is situated in the orbital cavity supplied by second cranial nerve that is Optic Nerve.

ANATOMY OF EYE

Eye is composed of three distinct coats or layers Sclera, Choroid, Retina.

1. **Outer fibrous layer:** Sclera and Cornea
2. **Middle vascular layer:** Choroid, ciliary body, iris
3. **Inner nervous layer:** Retina.

The structures inside the eye ball are lens, aqueous fluid and vitreous body.

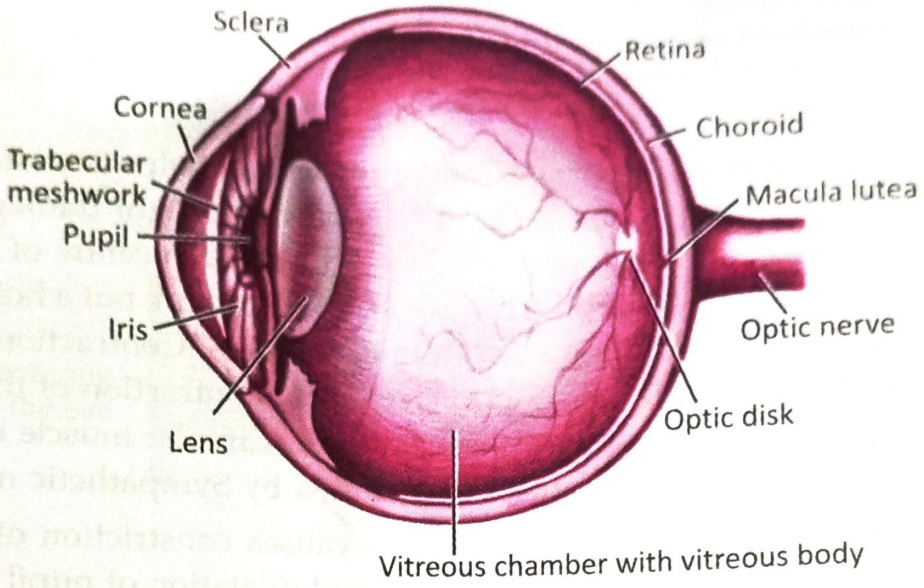

Fig. 12.1: ***Structure of Eye***

Sclera

It is an opaque fibrous coat which is white in colour and forms a transparent membrane in front, known as Cornea. Sclera is the thickest and strongest part of the eye ball.

Functions of Sclera

1. Sclera protects the delicate structures that lie inside of the eye.
2. It also maintains the shape of the eye ball.

Cornea

Cornea is the transparent coat of sclera. It is a circular in shape. Cornea acts as a transparent window and protects the inner structures and also helps in focusing the image on the retina.

Choroid

It is the middle vacular coat contains blood vessels. Choroid also contains melanocytes (melanin producing cells) which produce dark pigment melanin. Due to melanin choroid has brown black colour.

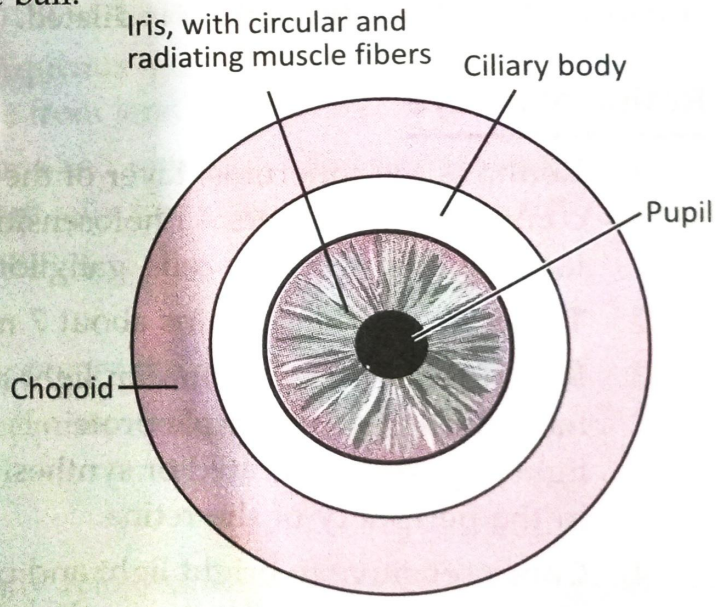

Fig. 12.2: ***Choroid, Ciliary Body and Iris view from the front***

Pupil, Iris and Ciliary Body

In front of the eye, choroid forms the iris which has a central opening called pupil and ciliary body.

Iris is a muscular curtain situated in front of the lens. It helps to protect the retina, controls the amount of light entering the eye. A powerful light damage the sensitive structures and reflexly contracts in response to bright light. In centre of the pupil, there is a circular aperature known as pupil. The pupil is not structure but a hole in the iris. It contains both circular and radiating smooth muscle fibres. Contraction of the circular muscle fibres constrict pupil (decreases pupil size) and Contraction of the radial muscle fibres dilates the pupil (increases pupil size) of the eye. Circular muscle is innervated by Parasympathetic nerves and radial muscle innervated by Sympathetic nerves.

Thus, stimulation of Parasympathetic nerves causes constriction of pupil (miosis) where as stimulation of sympathetic nerves causes of dilatation of pupil (mydriasis).

The ciliary body consists of ciliary muscle (smooth muscle fibres) and secretary epithelial cells. It gives attachment to the suspensory ligament. The contraction and relaxation of the ciliary muscle (smooth muscle fibres) controls the thickness of the lens through the suspensory ligament. When the ciliary muscle contracts, it moves forward, releasing the pull on the lens, increasing the thickness of the lens (thicker the lens becomes to allow focusing). It is supplied by Parasympathetic branches of the oculomotor nerve (3rd cranial nerve).

The iris contains radial muscles to dilate (widen) and circular muscles to constrict the pupil. The pupil vary size depending upon intensity of light. In bright light, pupil is constricted while in dim light it is dilated.

Retina of an Eye

1. Retina is the innermost layer of the eye. It gets stimulated by the light rays. It is composed of 3 layers – Photosensitive layer made of rod and cone cells, middle layer of bipolar nerve cells, ganglion nerve cells, horizontal cells, amacrine cells.
2. The entire retina contains about 7 million cones and 75 to 150 million rods.
3. Rods function mainly in dim light and provide black-and-white vision, the rods have rhodopsin or purple protein is photosensitive pigment. It gets bleached with light & gets regenerated or synthesized by Vitamin A. The rods are present more in the periphery of the retina.
4. Cones sensitive to bright light and colour. Coneopsins (also known as photopsins or iodopsin) present in cone cells, are used in colour vision.
5. The central retina has macula lutea or yellow spot made up of only cone cells. It has central depression called fovea centralis. All the nerve fibres of retina form the

optic nerve. The small area of the retina where the optic nerve leave the eye is known as optic disc or blind spot as no light sensitive cells are present here.

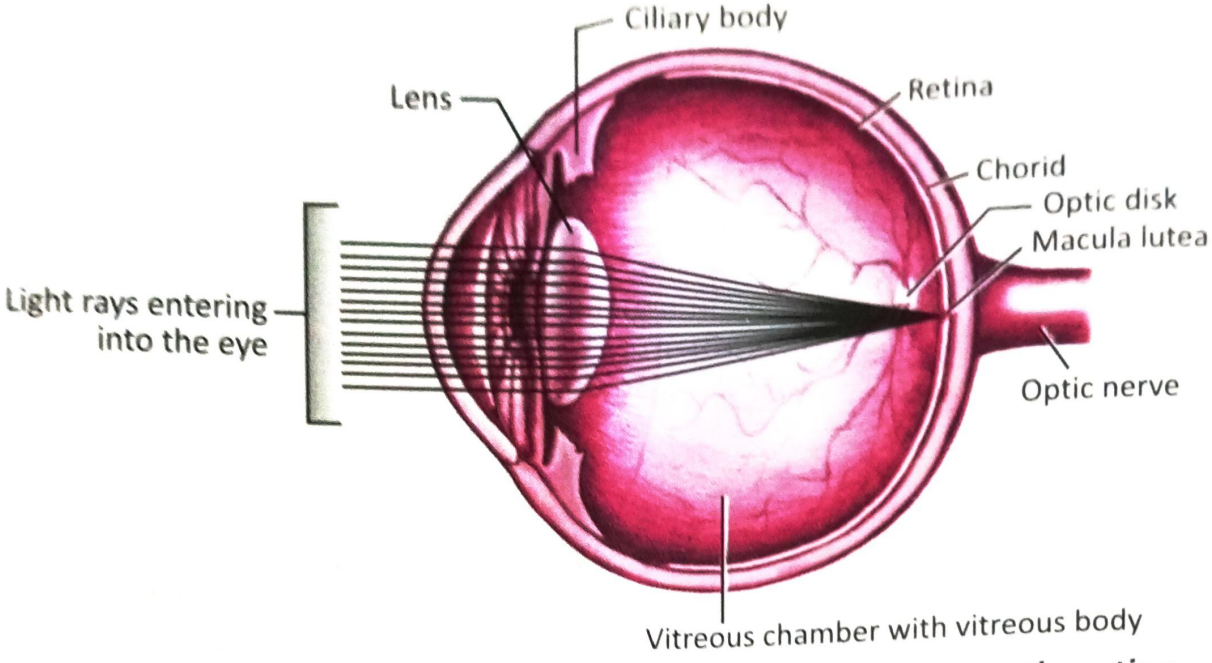

Fig. 12.3: ***Section of the eye showing the focusing of light rays on the retina***

CAVITIES OF AN EYE

Eye is divides into two cavities or chambers by iris:

1. **Anterior cavity or anterior chamber:** It is the space between cornea and iris
2. **Posterior cavity or posterior chamber:** It is the space between iris and lens

Both these filled with watery fluid called Aqueous humor which is secreted by ciliary body. It supplies nutrients and removes waste from lens and cornea.

The space or cavity at the back between lens and retina is called as Vitreous body or vitrous chamber. It is filled with colourless, soft jelly like substance contains 99% water, some salts and proteins is called as vitreous humor.

Functions of Vitreous humor are:

1. It maintains the shape of the eye and prevent the eyeball from collapsing.
2. It maintains intraocular pressure to supports retina against choroid

Lens

It is elastic circular biconcave transparent body lying immediately behind the pupil. It consists of protein fibres enclosed in a capsule is held in position by suspensory ligament. Its thickness is controlled by ciliary body through suspensory ligament. Lens bends (refracts) the light rays reflected by objects. It is the only structure that vary its refractive

power, achieved by changing its thickness. Nearer is the object, thicker is the lens. focus near object, ciliary muscle contracts, it moves forward, increasing the thickness the lens and nearer object being viewed.

ACCESSORY ORGANS OF THE EYE

Accessory organs protect the eye. These are:

1. Eye brows
2. Eyelids and eyelashes
3. Conjunctiva
4. Lacrimal apparatus

Eye Brows

These are bony ridges or curved areas above the each eye which usually consists of hair grow from the surface of the skin. Eye brows protect the eye from sweat, dust and other foreign bodies.

Eye Lids and Eyelashes

Eye lids are the two movable folds of skin situated above and below the each eye. It covers and protect the eye. On the free edges of the eyelids, there are short curved hairs called as the eyelashes.

Eye lids have following layers of tissue:

1. Thin covering of skin
2. A thin sheet of subcutaneous connective tissue (loose areolar) tissue.

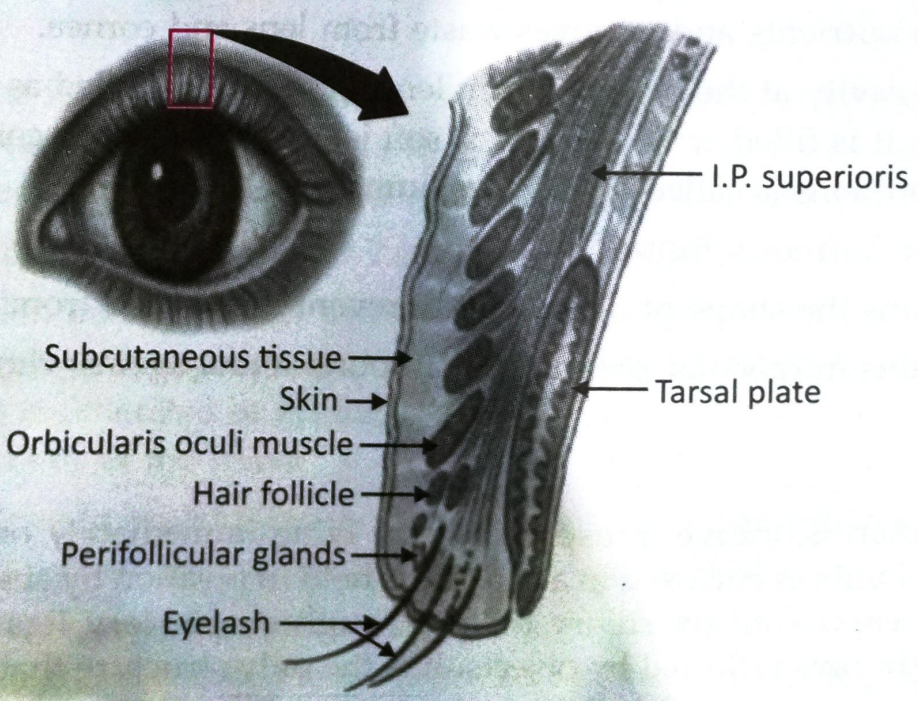

Fig. 12.4: Eye lids

3. Two muscles–orbicularis oculi and levator palpebrae superioris.
4. A thin sheet of dense connective tissue, tarsal plate, larger in the upper than the lower eyelid, which supports the other structures.
5. A membraneous lining, the conjunctiva.

Conjunctiva

It is a fine transparent membrane that lines the eyelids and surface of the eye. At eyelids, conjunctiva consists of highly vascular columnar epithelium. At cornea, conjunctiva consists of less vascular stratified epithelium. When eyelids are closed, the conjunctiva becomes a closed sac & Protects the internal delicate structures of eye. Drug if it is to be applied to the eye it is placed in the lower conjunctival sac.

Lacrimal Apparatus

The lacrimal apparatus (lacrim-tears) includes the structures which form and drains lacrimal fluid or tears. It includes:

- 1 lacrimal gland and its ducts
- 1 lacrimal sac
- 2 lacrimal canaliculi
- 1 nasolacrimal duct

Lacrimal gland is a exocrine gland about the size of almond. It is situated at the superior lateral portion of each orbit and is composed of secretory epithelial cells. Lacrimal glands are supplied by parasympathetic fibres of the facial (VII) nerves. These glands secretes tears that passes to the front of the eye by several small lacrimal ducts to medial canthus where they drain into the two lacrimal canaliculi. Tears then enters into the lacrimal sac which is upper expanded part of the nasolacrimal duct. From lacrimal sac ,tears pass down the nasolacrimal duct into the nasal cavity'

Flow of Tears

Lacrimal Gland
↓
Lacriaml ducts
↓
Lacrimal canaliculi
↓
Lacrimal sac
↓
Nasolacrimal duct
↓
Nasal cavity

Tears or Lacrimal fluid are the watery secretions of lacrimal gland which contains water, sodium chloride, antibodies and lysozyme, a bactericidal enzyme. Lacrimal fluid Protects, cleans, lubricates and moistens the eye ball. Each gland produces about 1 ml of lacrimal fluid per day. In case of inflammation of nasolacrimal duct, as in cold, eyes look watery as the drainage is blocked. During emotions and happiness, due to stimulation of parasymphathetic nerves lacrimal glands produces excessive lacrimal fluid, i.e., crying occur.

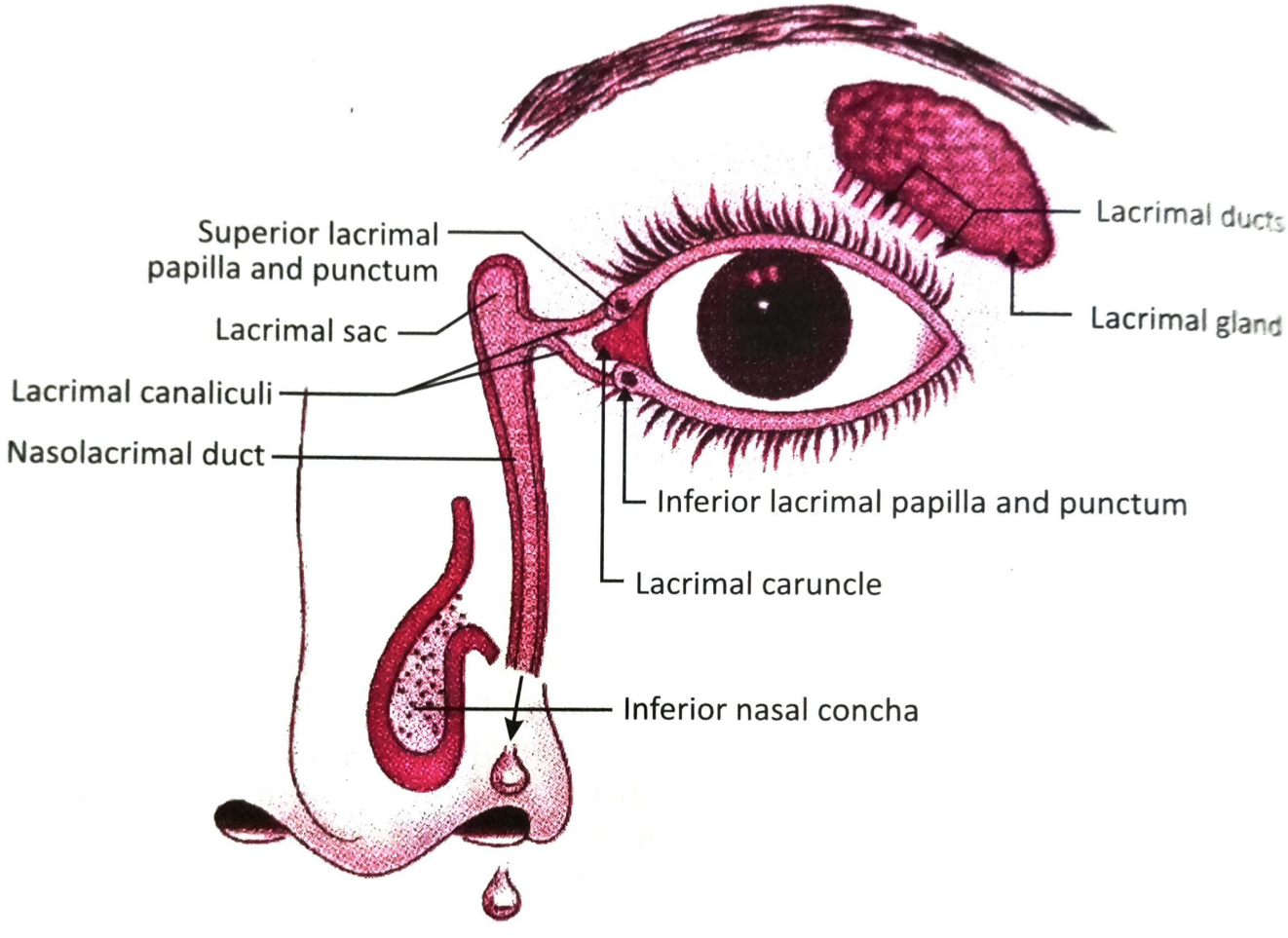

Fig. 12.5: ***Lacrimal apparatus***

Physiological events of vision consist of following;

1. Refraction (bending) of light rays entering in the eye
2. Accommodation of lens to focus object
3. Convergence of image
4. Photo-chemical activity in retina and conversion into neural impulse
5. Processing in brain and perception

1. Refraction of light entering the eye:

- Light wave travels parallel to each other but they bend when passes from one medium to another. This phenomenon is called refraction.

- Before light reach retina it passes through cornea, aqueous humor, lens, vitrous humor, so refraction takes place in every medium before it falls on retina.

2. **Accommodation of lens to focus object:** The changing the shape of lens while focusing on the object is known as accommodation.
   - To focus on closer object, ciliary muscle contract and lens become thick.
   - To focus on distant object, ciliary muscles relaxes, so the tension of suspensory ligament become greater which pull lens and lens become thinner, due to which image forms on retina.
   - The normal eye is able to accommodate light from object about 25 cm to infinity.

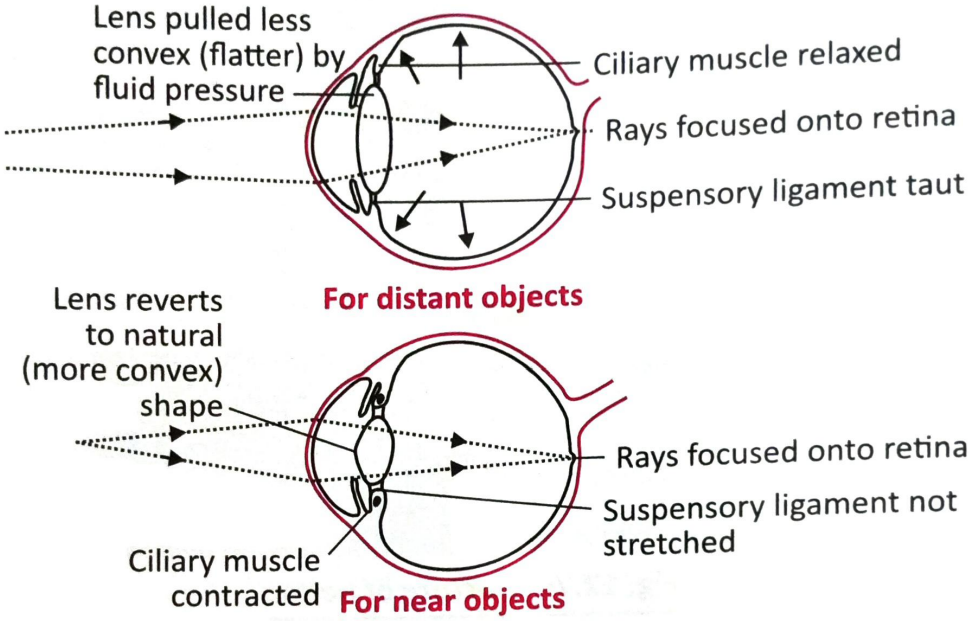

Fig. 12.6: ***Accodomation of lens to focus object***

3. **Convergence of image:**
   - Human eye have binocular vision, it means although we have two eye, we perceive single image
   - In binocular vision, two eye ball turns slightly inward to focus a close object so that both image falls on corresponding points on retina at same time. This phenomenon is called convergence.
4. **Photo-chemical activity in retina and conversion into neural impulse:** Light rays fall on the photoreceptor cell (rods and cones) breaking up light sensitive pigment by specific wavelength of light. This causes stimulation of rods and cones which generate nerve impulse in the bipolar nerve cells. The nerve impulse is then transmitted to ganglion cells.
5. **Processing of image in brain and perception:** The nerve impulses from the axon of ganglion cells conveyed into the optic(II) Nerve, through the optic chaism

and optic tract, to the thalamus. From thalamus, impulses for vision propagate the cerebral cortex(occipital lobe-visual area) where nerve impulse are analyzed and the image is formed on the retina.

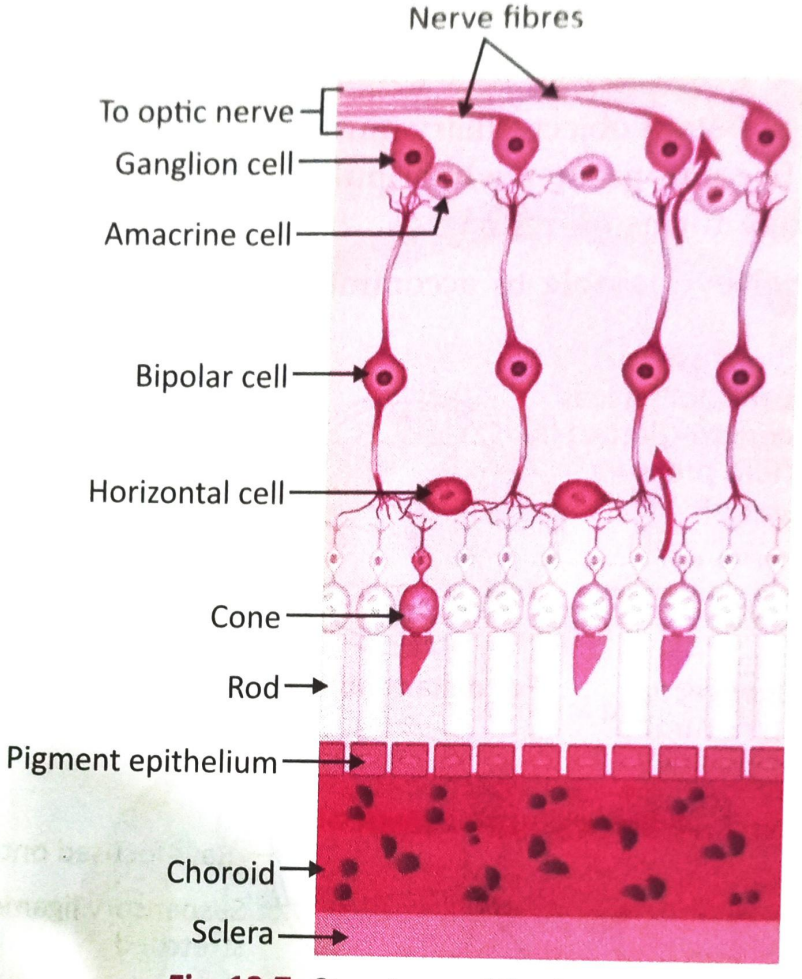

Fig. 12.7: ***Structure of Retina***

DISORDERS OF THE EYE

In the normal eye, light from near and distant objects is focused on the retina.

1. **Myopia (Nearsightedness):** Myopic person is shortsighted. They can see the near objects perfectly but find difficulty in seeing the distant objects. A person is able to see only nearer objects clearly because light from near object is focused on the retina. In this case eye ball is longer than normal and person cannot able to see longer (distant) objects clearly because light rays from from distant objects are not focused on the retina but in front of the retina. Distant vision is blurred (faint unclear).

2. **Hypermetropia (Farsightedness):** Hypermetropic person is longsighted. They can see distant objects perfectly but find difficulty in seeing the near objects. A person is able to see only distant objects clearly because light rays from distant (longer) objects is focused on the retina. In this case eye ball is too short than

normal and person cannot able to see near objects because light rays from near objects is focused behind the retina. Near vision is blurred (faint, unclear).

3. **Astigmatism:** It results in blurred vision due to abnormal curvature of part of the cornea or lens (oblong shape of the cornea and the lens) This interferes with the light path through the eye & prevents focusing of light on the retina, causing blurred vision. This may co-exist with hypermetropia, myopia or presbyopia. The correction is achieved using cylindrical lenses.
4. **Presbyopia:** As a process of aging, the lens loses its elasticity and weakening of ciliary muscles; the distant objects are seen clear but close objects are blurred. This results in difficulty with reading after the age of 40 years as the individual needs to hold reading material at arm's length. Old lady threading the needle from longer distance is a typical example of presbyopia.
5. **Cataract:** Here lens is cloudy means loses its transparency due to changes in the structure of the lens proteins. It results in visual impairment. It may be due to degenerative changes in old age. This condition can be treated surgically by removing the original lens and an artificial plastic lens fitted permanently in its place by ophthalmic surgeon.
6. **Glaucoma** is a condition characterized by increased intraocular pressure (pressure within the eye) (either through increased production or decreased outflow of aqueous humour) persistently raised intraocular pressure may damage the optic nerve and results into partial or even total blindness. The patient has attacks of severe pain in and around the eyes, sees halos particularly around light and has blurred vision. (Halos are bright circles that appear to surround a source of light, such as oncoming car headlights.)
7. **Blindness:** Blindness means lack of vision. Night blindness means due to defiency of vitamin A. Such a person cannot see in dim light.
8. **Stye:** It is an acute and painful bacterial infection of sebaceous or tarsal glands of the eyelid margin.It is also known as hordeolum.
9. **Conjunctivitis:** Inflammations of the conjunctiva due to irritants such as smoke, dust, wind,cold or microbes.

EARS

Ear is the organ of hearing. Ear is supplied by the eighth cranial nerve known as vestibulocochlear nerve which is stimulated by vibrations caused by sound waves.

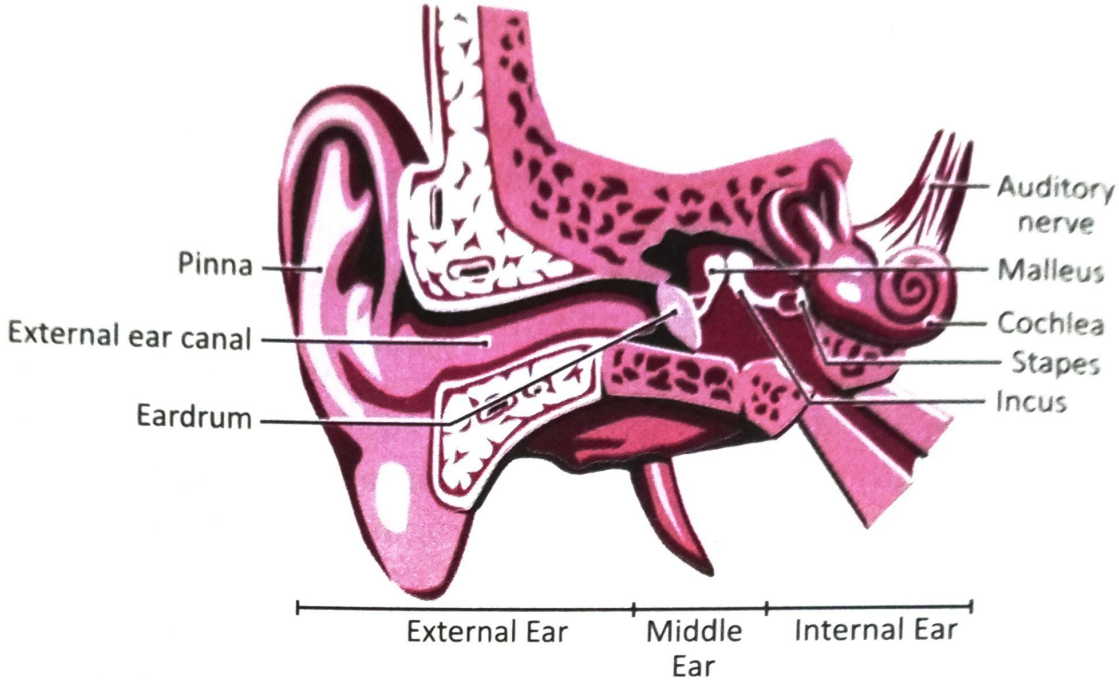

Fig. 12.8: ***Structure of Ear***

ANATOMY OF EAR

The ear is divided into three distinct parts:

1. **External (Outer) Ear:** It collects sound waves and transmits them to inside of ear
   (a) Auricle – Helix Lobule
   (b) External Acoustic Meatus or External Auditory Canal
   (c) Tympanic Membrane or Ear Drum
2. **Middle Ear:** It conveys sound waves to the inner ear.
   (a) Auditory Ossicles (Smallest Bones – Malleus, Incus, Stapes)
   (b) Auditory Tube or Eustachian Tube or Pharyngotympanic Tube
3. **Internal ear or Labyrinth of ear:** It changes sound waves to electrical si (nerve impulse) transmit to brain and responsible for hearing and equilibri
   (a) Semicircular Canals
   (b) Vestibulae
   (c) Cochlea
   (d) Vestbulochochlear Nerve

EXTERNAL EAR

External ear collects sound waves and transmits them to inside of ear.

External ear consists of three basic parts:

(a) **Auricle (Pinna):** It is a visible part outside the head and consists of flap of elastic cartilage covered by the skin. The rim of the auricle is the helix, the inferior (lower) portion is the lobule.

(b) **External Auditory Canal (External Acoustic Meatus):** It is a passageway or a curved tube 2.5 cm long from outside of headto ear drum. It contains a few hairs and specialized sebaceous (oil) glands called ceruminous glands that secreat the ear wax (cerumen). Hairs and cerumen prevent dust and foreign materials from entering the ear.

(c) **Ear Drum or Tympanic Membrane:** It is a thin layer of connective tissue (collagen, elastic fibres) partition between the external and middle ear. Due to sound waves, tympanic membrane vibrates. These vibrations are then transferred to the middle ear.

MIDDLE EAR (TYMPANIC CAVITY)

1. Middle ear conveys sound vibrations to the inner ear.
2. Middle ear is a small, air filled cavity in the temporal bone. It cosists of auditory ossicles and auditory tube or Eustachian tube or Pharyngotympanic tube.
3. **Auditory ossicles:** Middle ear consists of three smallest bones known as auditory ossicles Malleus, Incus Stapes transmit sound vibrations to inner ear. These bones named for their shapes:
   (i) **Malleus:** Lateral hammer shaped bone. The handle of the malleus attaches to the internal surface of the eardrum. Head of the malleus articulates with the body of incus.
   (ii) **Incus:** It is a middle anvil shaped bone. It has three parts body, long process and short process:
      (a) Body joins with the malleus
      (b) Long process joins with the stapes
      (c) Short process fixed to posterior wall of the tympanic cavity by fibrous tissue.
3. **Stapes:** It is stirrup shaped bone. It consists of two parts:
   (i) Head articulates with the incus
   (ii) Its footplate fits into oval window.
4. Middle ear is connected to nasopharynx through a tube called as auditory tube or Eustachian tube or Pharyngotympanic. It aerate the middle are and helps in equalizing air pressure on two sides of the eardrum.

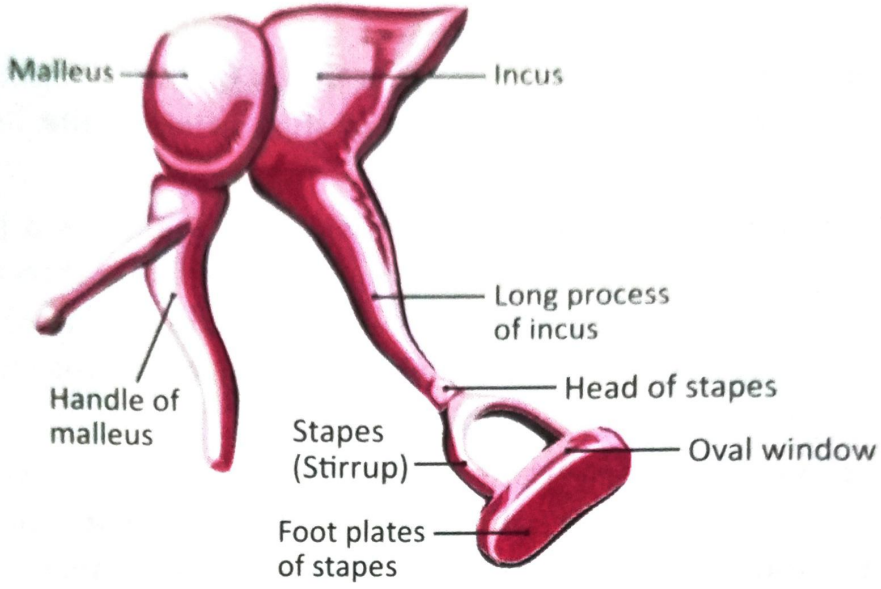

Fig. 12.9: ***Ossicles of the Ear***

INTERNAL (INNER) EAR OR LABYRINTH

The internal (inner) Ear is also called the labyrinth of ear because of its complicated series of channels. Internal ear connected to middle ear through small opening upper oval shaped oval window and the lower round shaped round window.

Internal ear consists of two regions:

(a) **An outer bony labyrinth:** Outer bony cavities namely semicircular canals, the vestibule, cochlea

(b) **Inner membranous labyrinth:** Inside the bony labyrinth is a membranous labyrinth which is series of tubes and sacs and divided into three parts semicircular ducts, utricle, saccule.

The bony labyrinth contain the fluid perilymph (chemically similar to cerebrospinal fluid) where as membranous labyrinth contain the fluid endolymph.

Outer Bony Labyrinth

Structurally, it consists of three parts:

1. Semicircular canals
2. The vestibule
3. Cochlea

The semicircular canals and the vestibule contains receptors for equilibrium where as cochlea contains receptors for hearing.

1. **Semicircular Canals:** These are three interconnected tubes superior, posterior and lateral situated at right angle to each other. Each canal has a swelling at one

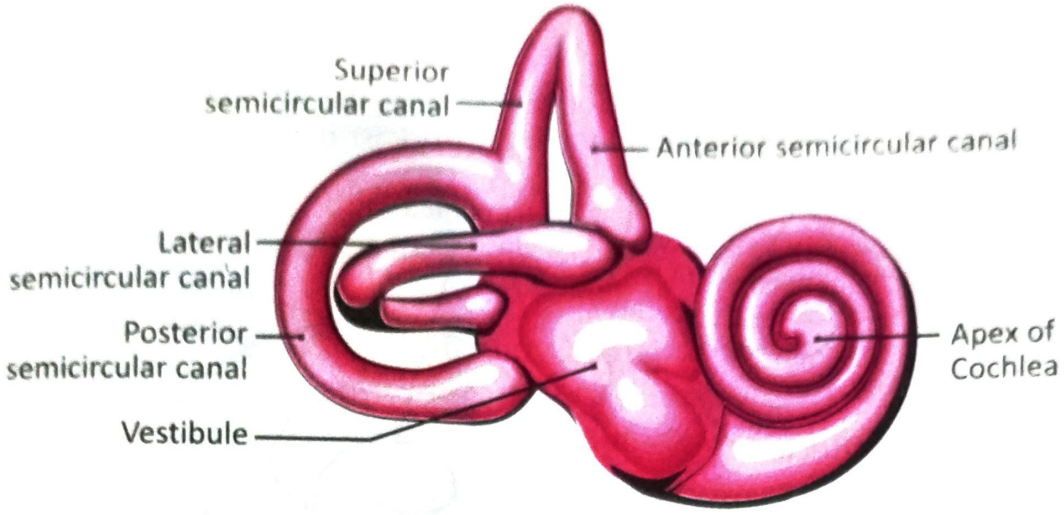

Fig. 12.10: ***Bony Labyrinth***

end called ampulla which helps the cerebrum in maintaining equilibrium or balance.

2. **The Vestibule:** It is the central portion of the bony labyrinth present between semicircular canals and chochlea. It is separated from the middle ear by the oval window.

   Two parts of the membranous labyrinth utricle (closer to the semicircular canal) and saccule (closer to chochlea) are located within vestibule. The utricle and saccule contains receptors that helps in maintaining equilibrium or balance

3. **Chochlea:** The coiled portion of the labyrinth (inner ear) is called Chochlea. It is the main hearing organ of inner ear. Chochlea is made up of three cannals namely:

   (i) An upper Scala vestibuli which ends at the oval window

   (ii) A middle Scala media–upper membrane of scala media is called reissner's membrane and lower membrane is called as basilar membrane.

   (iii) A lower Scala tympani ends at the round window.

   Both Scala-vestibuli and Scalatympani contain perilymph where as Scala media contains endolymph.

   (iv) At the apex of chochlea, Scala vestibule and Scala tympani are connected with each other through small hole called helicotrema.

   (v) **Organ of corti or spiral organ:** It is located on the basilar membrane and is composed of the sensory receptor cells– hair cells, basal cells, supporting cells. Hair cells are present in rows and acts as auditory receptors. They have projected processes called as stereo cilia.

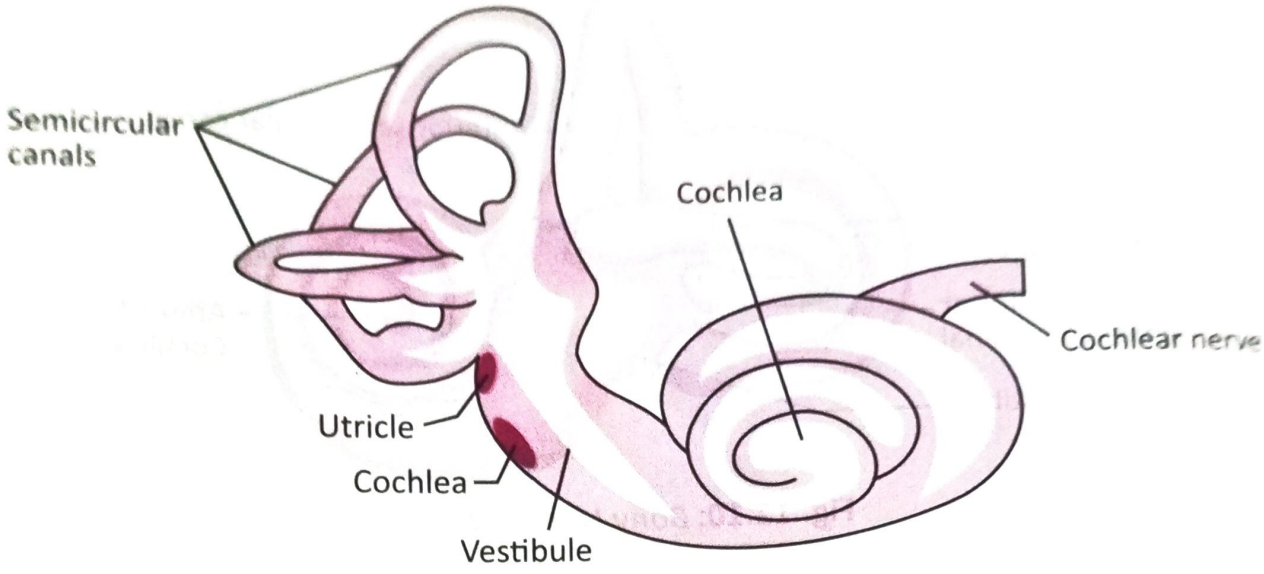

Fig. 12.11: ***Cochlea***

Tectorial membrane is a delicate and flexible membrane lies on the hair cells. Lo end of the hair cells is in close contact with afferent nerve fibres (carry nerve imp from ear to brain) of the vestibulochochlear nerve (eighth cranial nerve).

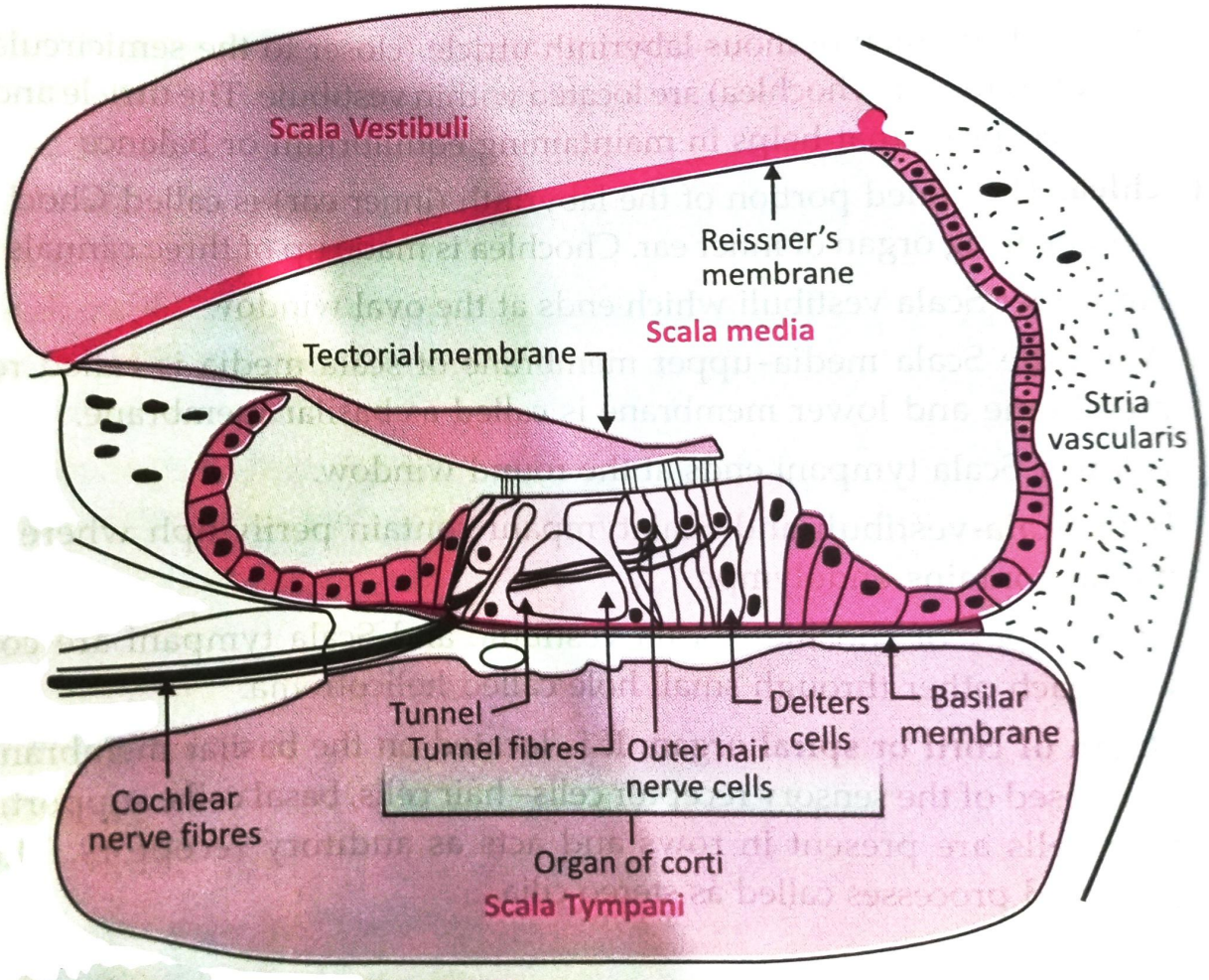

Fig. 12.12: ***Anatomy of Inner Ear***

PHYSIOLOGY OF HEARING

1. The external ear collects and receives the sound waves and directs along auditory canal to the ear drum or tympanic membrane.
2. After receving the sound waves the ear drum become vibrate.
3. The vibrations generated in the ear drum passed to the three ear ossicles (Malleus, Incus, Stapes).
4. Ear ossicles increases the intensity of the of the sound vibrations and transmit them to the oval window (it acts as a door of inner ear, sound vibrations from middle ear enters into inner ear through oval window.
5. The sound vibrations passes to the oval window to chochlea (part of inner ear).

   At oval window, Scalavestibuli (upper chamber) containing perilymph is present. Firstly movement of oval window sets up sound waves are in perilymph of Scala vestibule.
6. After perilymph sound wave enters into endolymph of scala media resulting in vibration of basilar membrane.
7. Due to vibration of basilar membrane bends the hair cells of Organ of corti (present on the basilar membrane) and press them against the flexible tectorial membrane present on them (hair cells). As a result nerve impulses are generated in the afferent neuron of hair cells and transmitted to the brain via auditory nerve or vestibulocochlear nerve.
8. The nerve impulses are analysed in the brain (cerebrum) and sound is recognised or is perceived.

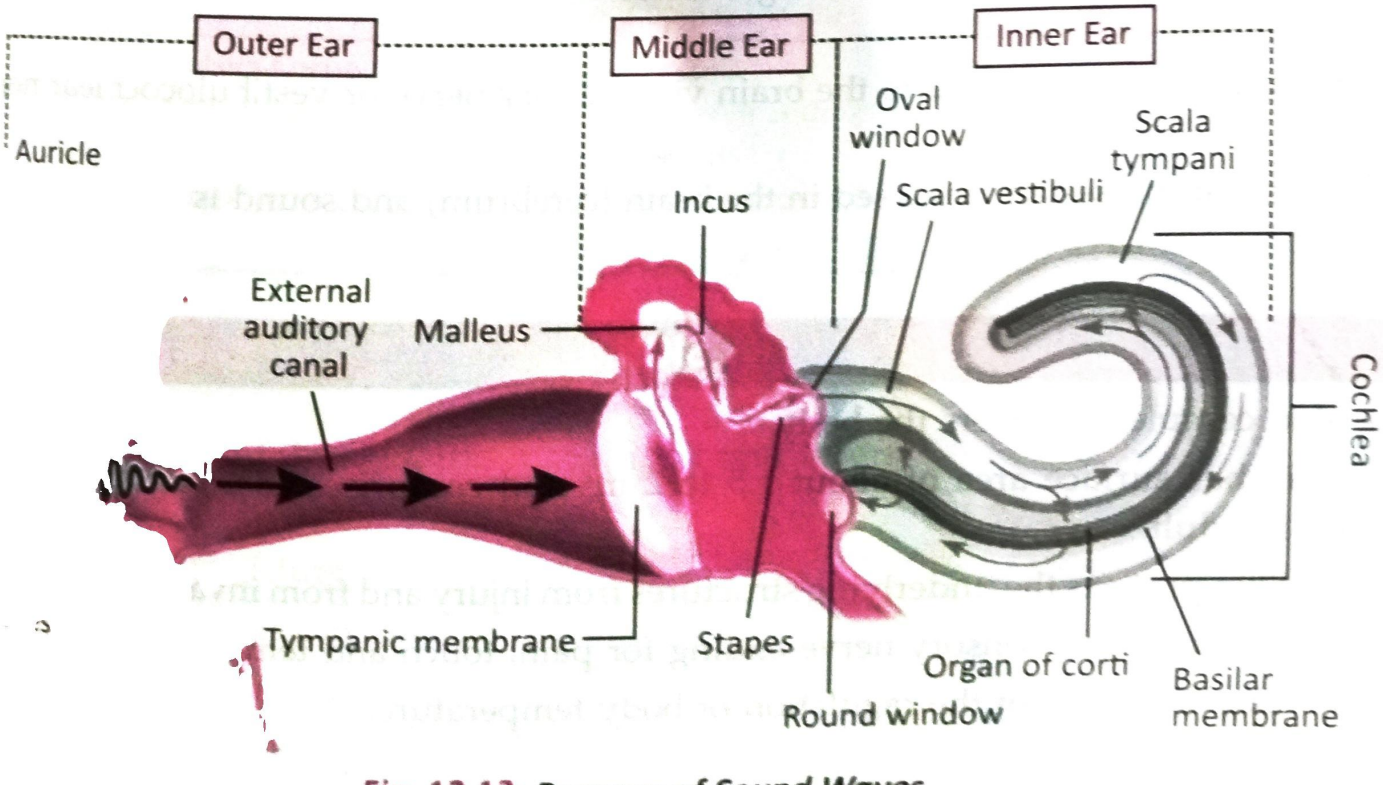

Fig. 12.13: ***Passage of Sound Waves***

MECHANISM OF HEARING

External ear collects and receives the sound waves

↓

Directs along auditory canal to the ear drum

↓

Ear drum gets vibrated

↓

Vibrations pass to the three ear ossicles (Malleus, Incus, Stapes)

↓

From ear ossicles vibrations transmit to oval window

↓

Movement of oval window sets up sound waves are in perilymph of Scala vestibule

↓

Sound wave enters into endolymph of scala media, resulting in vibration of basilar membrane.

↓

Due to vibration of basilar membrane bends the hair cells of Organ of corti (present on the basilar membrane) and press them against the flexible tectorial membrane present on them (hair cells)

↓

As a result, nerve impulses are generated in the afferent neuron of hair cells

↓

Nerve impulses transmitted to the brain via auditory nerve or vestibulocochlear nerve

↓

Nerve impulses are analysed in the brain (cerebrum) and sound is recognised

SKIN

The skin completely covers the body.

The skin has surface area of about 1.5 to 2 m^2 and comprises 15% of the total body weight in adult.

1. Skin protects the underlying structures from injury and from invasion of microbes.
2. Skin contains sensory nerve ending for pain, touch and temperature.
3. Skin involved in the regulation of body temperature.

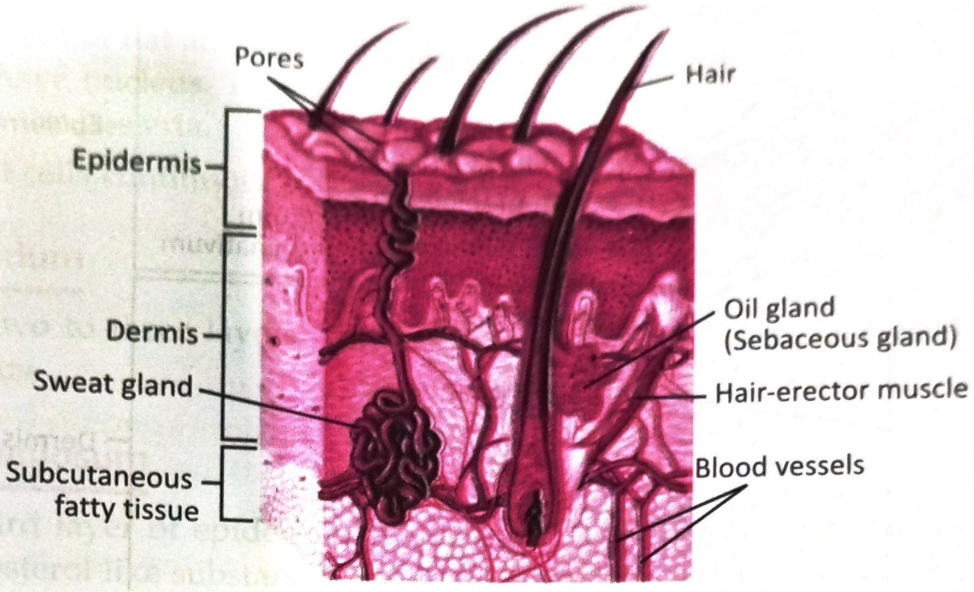

Fig. 12.14: *Structure of Skin*

STRUCTURE OF SKIN

SKIN

Epidermis	Dermis (Connective Tissue)	Subcutaneous Tissue
1. Stratum Corneum 2. Stratum Lucidum 3. Stratum Granulosum 4. Germinative Layer 5. Hair Follicle	1. Blood Vessels 2. Sensory Nerve Endings 3. Sweat Glands 4. Sabaceous Glands	

EPIDERMIS

It is the outer layer of the skin. It is made up of four layers:

1. **Stratum Corneum**
2. **Stratum Lucidum**
3. **Stratum Granulosum**
4. **Stratum Germinativum**

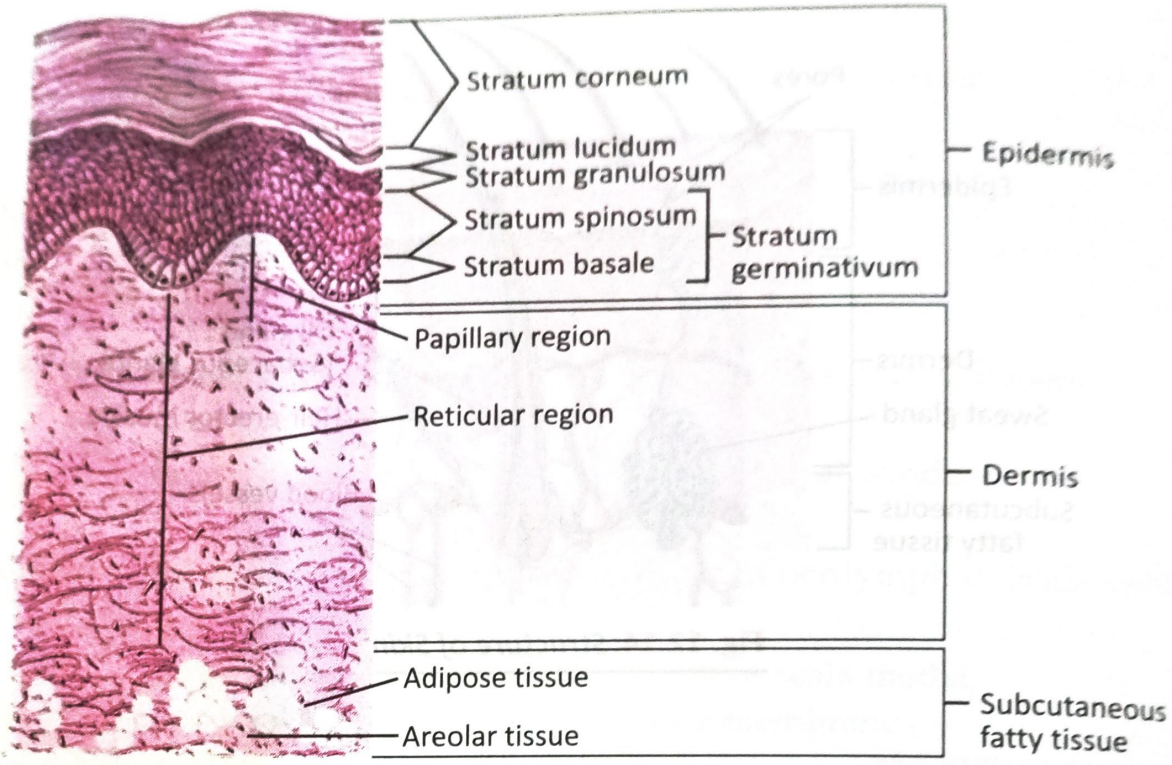

Fig. 12.15: ***Microscopic Structure of Skin***

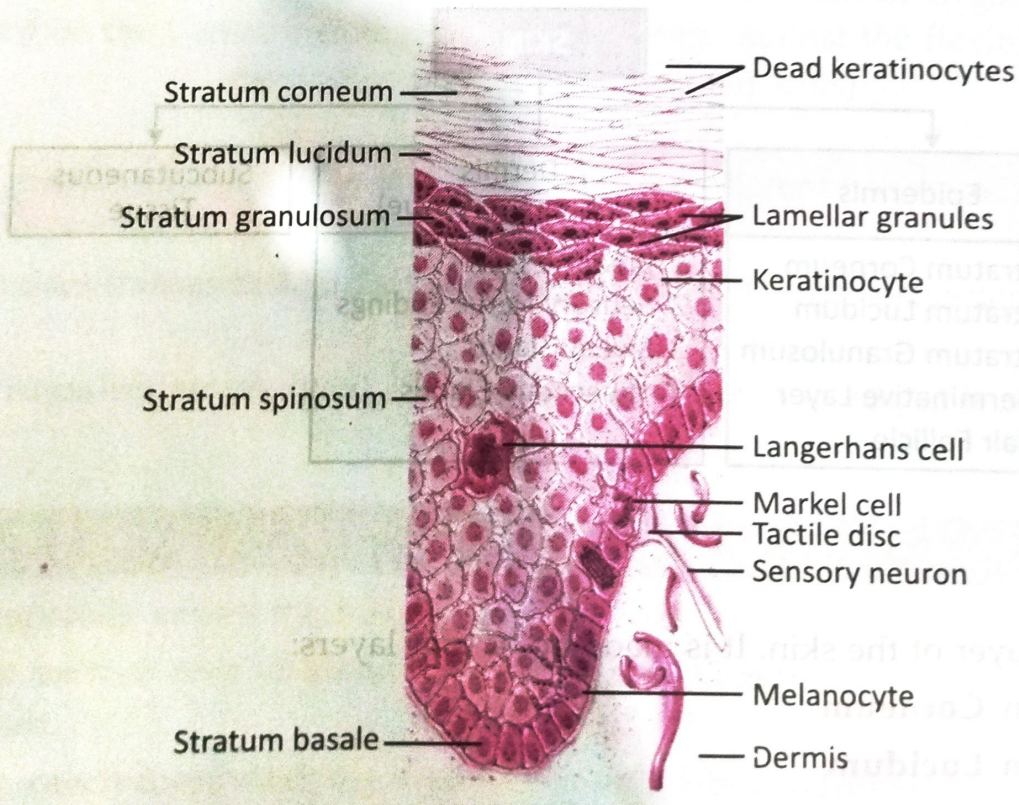

Fig. 12.16: ***Epidermis***

Stratum Corneum

It is the outer coat of flat and dead cells. There are many layers of such cells. Cells in this layer do not have nucleus. They contain substance known as keratin which is acidic in nature, it kills the bacteria.

Superficial cells continuously cast off and new layers are formed.

Stratum Lucidum

It consist of two to three layers of flat cells. Some cells having nucleus, some do not possess nucleus.

Stratum Granulosum

This is the third layer of epidermis. It consists of 2 to 5 layers of flat cells. These cells contains cholesterol like substances under the effect if U.V. rays of sun. It is converted to Vitamin D.

Stratum Germinativum

This is the innermost layers of the epidermis. These are cuboidal cells. It undergoes cell division continuously and the cells formed and push to the superficial layer. The cuboidal cells present in the stratum have coloured granules. These granules are made up of dark pigment melanin. These cells are called melanocytes. The colour of the skin depends upon the amount of melanin present in these cells.

These 4 layers of skin are not having good blood supply and nerve supply. So superficial injuries do not bleed and they are also not painful.

DERMIS

It is second, deeper part of skin and composed of connective tissue containing collagen and elastic fibres. Dermis contains collagen and elastic fibres with the age, the elasticity of the skin becomes less and less and so wrinkles appear on the skin. The cells present in the dermis are fibroblast, macropahges and some adipocytes.

The structures in the dermis are:

- Blood vessels
- Sensory nerve endings
- Skin glands (sweat gland & sebaceous gland)
- Hairs, arrectorpili muscles.

Sensory Nerve Endings

Sensory receptors or Sensory nerve endings sensitive to touch, temperature, pre and pain are widely distributed in the dermis.

Incoming stimuli activate different types of sensory receptors. Nerve impu generated in the sensory receptors, these sensory nerves sent nerve impulse to the sp cord and then to the sensory area of the cerebrum where the sensation are perceived

Sweat Glands (Sudoriferous Glands)

Sweat glands are widely distributed through the body and more in the palms of hands, soles of the feet, axillae and groins. Sweat glands are composed epithelial ce The bodies of the glands are coiled in the subcutaneous tissue and opens on to the surface.

Sweat glands are stimulated by sympathetic nerves in response to increases bo temperature (during exercise) and fear.

The main function of the sweat is the regulation of body temperature. In summ production of sweat increases than the rate of evaporation and so sweat appears on surface of the skin.

Hairs

These are formed by a down growth of epidermal cells int o thedermis or subcutaneou tissue, called Hair Follicles. At the base of the, hair follicle, there is a cluster of cells a called bulb. The part of hair above the skin is the shaft and in the skin is root. Th arrectorpili are the smooth muscles attached to the hair follicles. Due cold, autonom nerves stimulate the arrectorpili muscles to contract and hairs stand erect which cause elevation of skin. This action is called 'goose flesh or goose bumps'.

Surrounding each hair follicle are dendrites of neurons called hair root plexuses th are sensitive to touch.

Functions of Hairs

Hairs offers limited protection –from the sun, heat loss and entry of foreign particles in eyes, nose and ears. They also function in sensing light touch.

Sebaceous (Oil) Glands

These are usually connected to hair follicles. They are absent in palms and soles. Sebaceo glands produce oily substance that is called sebum which contains triglyceride cholesterol, proteins and inorganic salts. Sebum coats the surface of hairs and moiste them. Sebum also prevents excessive evaporation of water from the skin and keeps th skin soft and pliable also inhibits the growth of certain bacteria.

Acne is an inflammation of sebaceous glands that usually begins at puberty when the sebaceous glands grow in size and increase their production of sebum.

FUNCTIONS OF SKIN

1. Protection
2. Regulation of Body Temperature
3. Formation of Vitamin D
4. Cutaneous Sensation
5. Absorption
6. Excretion

1. **Protection:** Skin protects the body from mechanical injury, from chemicals, heat. Skin also prevent entry of microorganisms into the body. Epidermal cells helps in the increasing immunity.
2. **Regulation of body temperature:** Skin helps in maintaining body temperature. The body temperature is maintained at 36.8°C in healthy persons with the variations of 0.5 to 0.75°C. In the body, heat is produced due to metabolic activities of liver, digestive organs, muscles.

   The temperature regulating centre in the hypothalamus is responsible to the circulating blood. This centre controls body temperature through autonomic nerve stimulation (sympathetic) of sweat glands when body temperature rises.

   The vasomotor centre in the medulla oblongata controls the diameter of the small arteries and arterioles and therefore amount of blood which circulates in the capillaries in the dermis.

   When the body temperature increases, then temperature regulating centre in the hypothalamus sent nerve impulse to the vasomotor centre in the medulla oblongata and stimulate sympathetic nerves of sweat glands.

   The vasomotor centre dilates blood vessels and so more blood reaches to the skin which contains more heat. The sympathetic nerves stimulate sweat glands. Due to heat (slight hot skin) sweat evaporates from the skin. Thus, body temperature decreases. In this way skin maintains body temperature.

Body Temperature increases

↓

Temperature regulating centre in the hypothalamus sent nerve impulse to the vasomotor centre in the medulla and stimulate sympathetic nerves

↙ ↘

Vasomotor centre dilates blood vessels of skin | Sympathetic nerves stimulate sweat glands

↓ | ↓

Blood transfer heat to skin through sweat glands → Sweat is released, sweat evaporates

↓

Temperature maintained

3. **Formation of Vitamin D:** 7–Dehydrocholesterol is a fatty substance in the skin. The Ultra Violet (UV) light from the sun converts 7–Dehydrocholesterol into Vitamin D.

$$\text{7–Dehydrocholesterol} \xrightarrow{UV} \text{Vitamin D}$$

4. **Cutaneous sensation:** Skin contains nerve ending and receptors. Thus the skin we senses touch, temperature, pain and pressure.
5. **Absorption:** Few oily substances can be absorbed through skin. Many ointments therefore can be applied to the skin.
7. **Excretion:** Through sweat, skin excretes (remove) some waste products.

PHYSIOLOGY OF PAIN

Pain is the protective mechanism of the body. Pain occurs whenever any tissue are being damaged. Pain receptor are the nerve endings present in almost all tissues (deep in the skin).

Whenever tissue being damaged there is released of chemical substances like bradylinnes, so their is stimulation of pain receptors. Pain receptors passes sensory pain impulses to spinal cord and central nervous system that is thalamus then cerebral cortex then there is feeling of pain.

Tissue being damaged

↓

Release of chemical substances like bradykinins

↓

Stimulation of pain receptors

↓

Pass sensory pain impulse to spinal cord, thalamus, cerebral cortex

↓

Feeling of Pain

IMPORTANT QUESTIONS

1. Name four special sense organs. (W-96; S-97)
2. Give the functions of Tongue. (W-96; S-97)
3. How sense of taste is developed? (S-97)
4. Explain the physiology of taste. (S-01)
5. What are the four fundamental sensations of taste? (W-97)
6. What is external ear? Describe it. (W-99; S-01, 02)
7. Write a note on middle ear or tympanic cavity. (S-03)
8. Draw a well labeled diagram of internal ear. (W-97)
9. Describe internal ear. (W-97)
10. Discuss the physiology of hearing or Trace the pathways for hearing from external ear to cerebral cortex. (S-00; W-00, 02)
11. Explain internal ear is helpful in maintaining equilibrium. (S-98; W-97)
12. Describe the structure of skin. (S-96, 02)
13. Draw and label the structure of organs of sensation of touch, pain and temperature.
14. Discuss the functions of skin (W-96, 97, 98, 01; S-97, 99, 00)
15. Explain in short V.S. of human skin. (S-96, 02)
16. Explain how skin helps in maintaining body temperature. (S-99, 01, 03; W-98.02)
17. Explain the physiology of pain. (S-99)
18. Draw a diagram of section of eye. (S-96, 00, 03; W-96, 00, 02)
19. Describe lacrimal apparatus. (S-02)
20. Describe the outer fibrous layer of eye. (W-02)
21. Discuss choroid, ciliary body and iris of eye. (W-97; S-01, 02)
22. Describe lens as a part of eye. Give its functions. (W-99)
23. Explain nervous layer or Retina of eye. (W-97, 02)
24. What is pupil? How its size is controlled? (W-97, 99, 02)
25. Where aqueous humour is present? Write its function. (S-03)
26. Define the terms:
    (a) Myopia (b) Hypermetropia
    (c) Presbyopia (d) Astigmatism
    (e) Glaucoma
    (f) Night blindness. (S-98, 02; W-00, 02)
27. Name the three muscles of facial expression with their attachment and functions. (S-96, 97; W-96)

CHAPTER

Urinary System

MAIN EXCRETORY ORGANS IN THE HUMAN BODY

1. **Kidneys:** Kidneys removes unwanted water and unwanted solutes from the bo in the form of urine. Thus, kidney filters blood and excretes waste.
2. **Lungs:** Excrete or remove carbon dioxide from the body in the form of exha air.
3. **Skin:** It excretes water, carbon dioxide in the form of sweat.
4. **Intestine or alimentary canal:** Remove solids or semi solids (undigested food the form of faecal matter.

The urinary system (Kidneys) is the main excretory system.

ORGANS OF URINARY SYSTEM

1. Two kidneys secrete the urine.
2. Two ureters pass urine from the kidney to the urinary bladder.
3. One urinary bladder temporarily store urine.
4. An urethra discharges or removes urine from the body.

FUNCTIONS OF KIDNEY AND URINARY SYSTEM

1. **Urine formation and water balance.**
2. **Excretion of waste (unwanted material) from the body,** e.g., urea, billru creatinine, uric acid and other wastes, i.e. subst [illegible] lungs and to

3. **Regulation of electrolyte balance**, e.g., sodium, potassium, calcium, chloride, phosphate.
4. **Regulation of blood pH** (amount of hydrogen ion).
5. **Regulation of blood volume:** Kidneys adjust blood volume by removing excess water in the urine.
6. **Regulation of blood pressure:** Kidneys also regulate blood pressure by secreting the enzyme renin, which increases the blood pressure.
7. **Regulation of blood osmolarity (concentration of solutes):** By regulating loss of water and sodium, chloride, bicarbonate in the urine, kidneys maintains a constant osmolarity
8. **Production of Hormones:** Kidneys produces two hormones Calcitrol and Erythropoietin. Calcitrol participate in Vitamin D synthesis to regulate the calcium level in the body. Erythropoietin stimulates production of red blood cells.

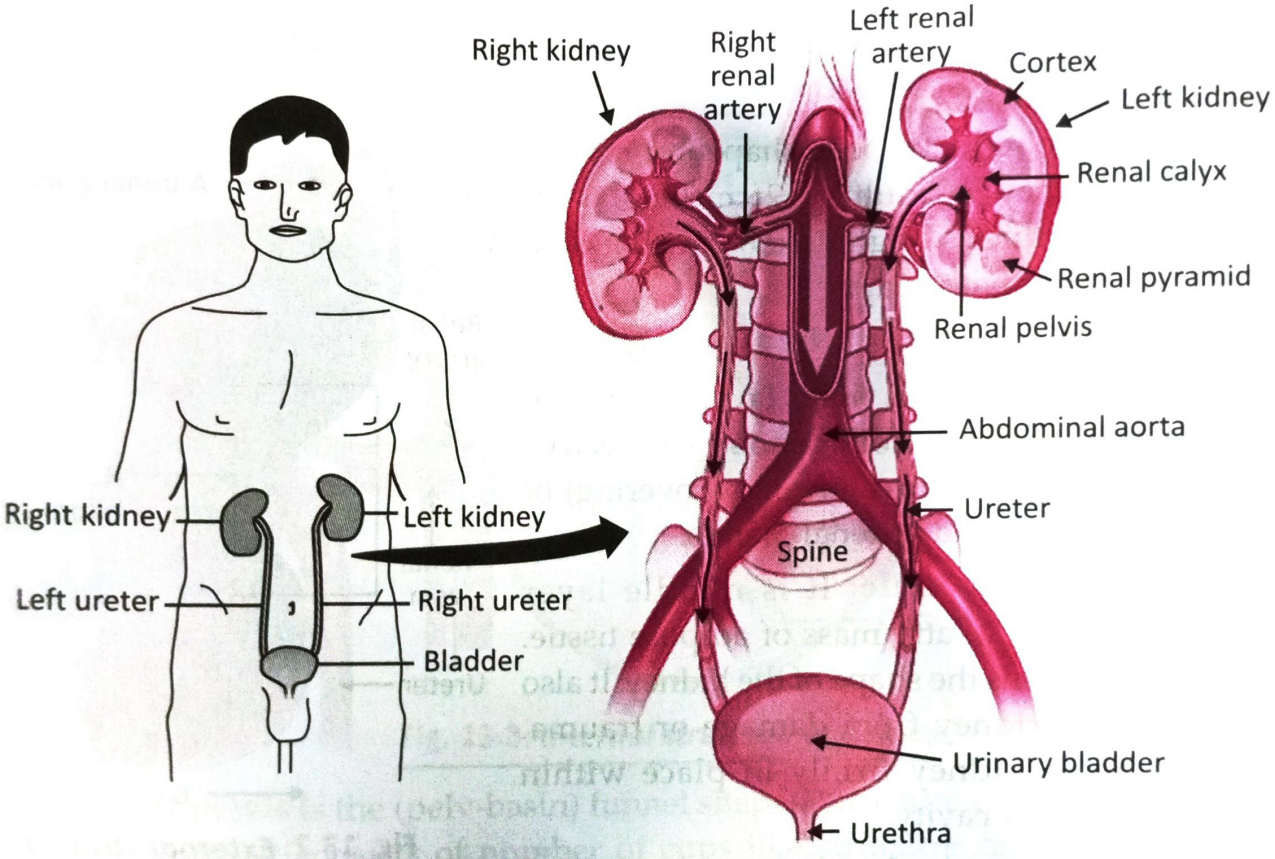

Fig. 13.1: *Urinary System*

ANATOMY, HISTOLOGY AND PHYSIOLOGY OF KIDNEY

Anatomy of Kidney

1. Location
2. External structure
3. Internal structure

LOCATION OF KIDNEYS

Kidneys are located on posterior abdominal wall, on each side of the vertebral column between the level of twelfth (12th) thoracic vertebra and third 3rd lumbar vertebra, below the diaphragm. The right kidney is slightly lower than the left kidney because liver occupies the space on right side above to right kidney.

EXTERNAL STRUCTURE OF KIDNEY

1. Kidneys are reddish, bean shaped organs. A typical kidney in adult is 12 cm long, 6 cm wide, 3 cm thick, weight is 150 gm about the size of bar of bath soap.
2. **Each kidney is covered by three layers:**
   - (a) **Renal Fascia:** It is outer layer consists of a thin sheet of collagenous connective tissue which forms envelop (covering) of the kidney and adrenal glands.
   - (b) **Adipose Capsule:** It is middle layer consists of a fatty mass of adipose tissue. It maintains the shape of the kidney. It also protect kidney from damage or trauma. It holds kidney firmly in place within abdominal cavity.
   - (c) **Renal Capsule:** Inside layer consists of tough connective tissue. It also protects kidney from damage or any injury.

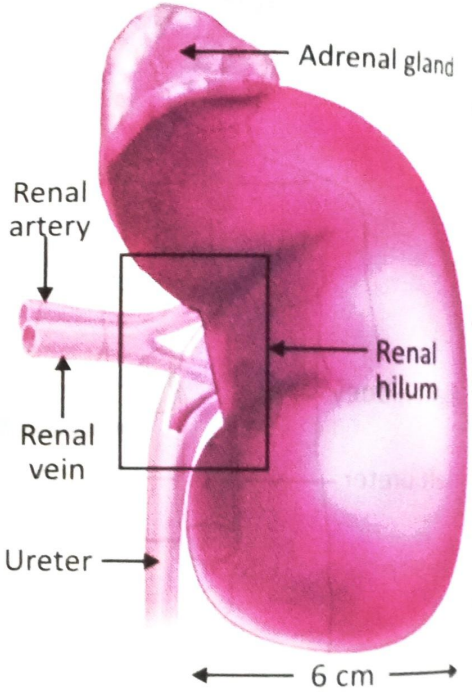

Fig. 13.2: *External Structure of Kidney*

3. **Renal Hilum:** It is a deep vertical concave medial border of the kidney in which blood vessels, i.e., renal artery and renal vein enters and ureter emerges from kidney.

INTERNAL STRUCTURE OF KIDNEY

A Longitudinal Section of Kidney (L.S.) shows three areas which can be clearly distinguished:

1. **Renal Cortex:** Smooth reddish outer region.
2. **Renal Medulla:** Deep reddish brown inner region. It consists of several conical shaped striations (linear marks) called **Renal Pyramids.** The base of each pyramid called **Renal Papilla** (small rounded part). Together the renal cortex and renal medulla constitute the Parenchyma (functional portion) of kidney. About 1 million microscopic structures called **Nephrons** are presents within the Parenchyma. Urine formed by the nephrons drains into large papillary duct.

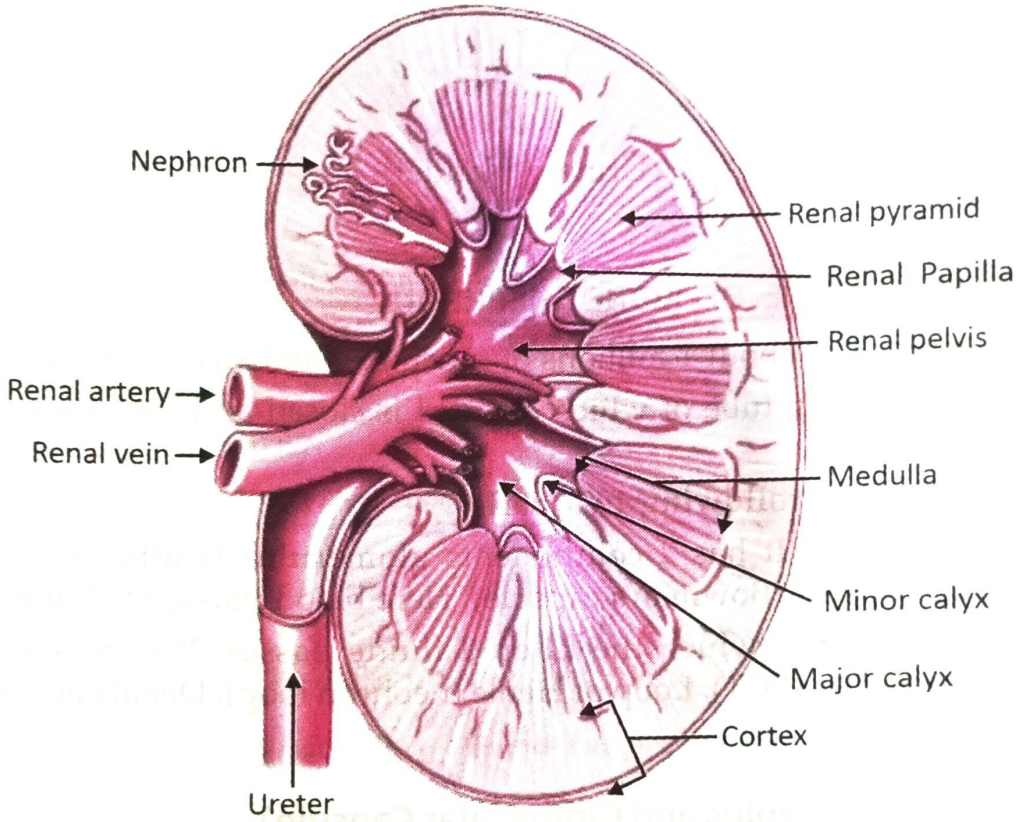

Fig. 13.3: ***Internal structure of Kidney***

3. **Renal pelvis** is the (pelv-basin) funnel shaped structure that acts as receptacle for the urine. It consists of number of cups like structure called **minor and major calyces** (singular-calyx) where urine collection starts. Each kidney has 2 to 3 major calyces which in turn divide into 8 to 18 minor calyces and urine passes from papillary duct to minor calyx then to major calyx then enter into a single large cavity called **Renal Pelvis** then ureter to the urinary bladder. The walls of pelvis contain smooth muscles and transitional epithelium tissue which causes peristalsis movement and propels urine through pelvis to ureter to urinary bladder. This is an intrinsic (automatic) property of smooth muscle.

PATH OF URINE OF URINE DRAINAGE

Urine formed by Nephron
↓
Papillary duct in renal pyramid
↓
Minor calyx
↓
Major calyx
↓
Renal pelvis
↓
Ureter
↓
Urinary bladder

MICROSCOPIC STRUCTURE OF KIDNEY-NEPHRON

Each kidney composed of about 1 millions of functional and structural units, Nephrons

Each nephron is a long tube of which one end is closed and the other end is opens into collecting tubule.

Nephron consists of following two parts:

1. **Renal Corpuscle:** It has 2 components glomerulus (capillary network) and glomerular capsule (Bowman's capsule). Here blood plasma is filtered.
2. **Renal Tubule:** Into which the filtered fluide passes. It consists of Proximal convoluted tubule (PCT), Loop of Henle (nephron loop), Distal convoluted tubule (DCT).

Renal Corpuscle (Glomerulus and Glomerular Capsule)

Glomerulus

It is a bunch of interconnected capillaries. In kidney, Renal artery divides into smaller arteries, arterioles and then into afferent arteriole. Thus afferent – towards arteriole is a branch of Renal artery which carries blood to the glomerulus. Afferent arteriole divides into compact capillaries. This ball shaped network of capillaries called glomerulus (glomerulus-little ball) Glomerular capillaries reunite to form an efferent – away arteriole (ef-out) that carries blood out of the glomerulus. The diameter of the efferent arteriole is smaller than the afferent arteriole so it gives some resistance to flow of blood which causes higher blood pressure in the glomerulus.

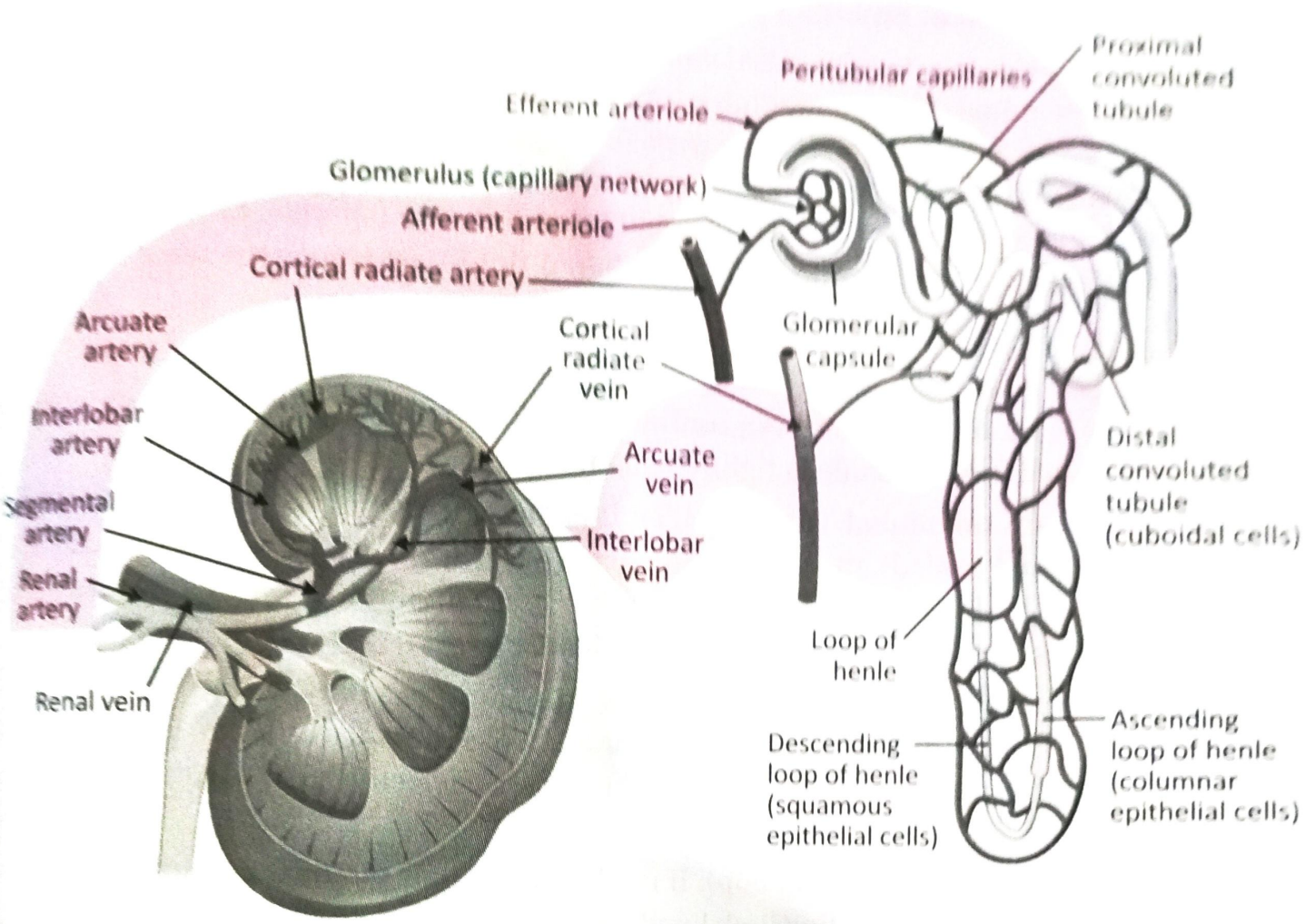

Fig. 13.4: ***Structural and Functional unit of Kidney that is Nephron***

Due to high B.P, filtration of blood plasma takes place in glomerulus which acts as a filtering unit of kidney. The wall of capillaries (glomerulus) consists of single layered flattened epithelial cells which is responsible for filteration.

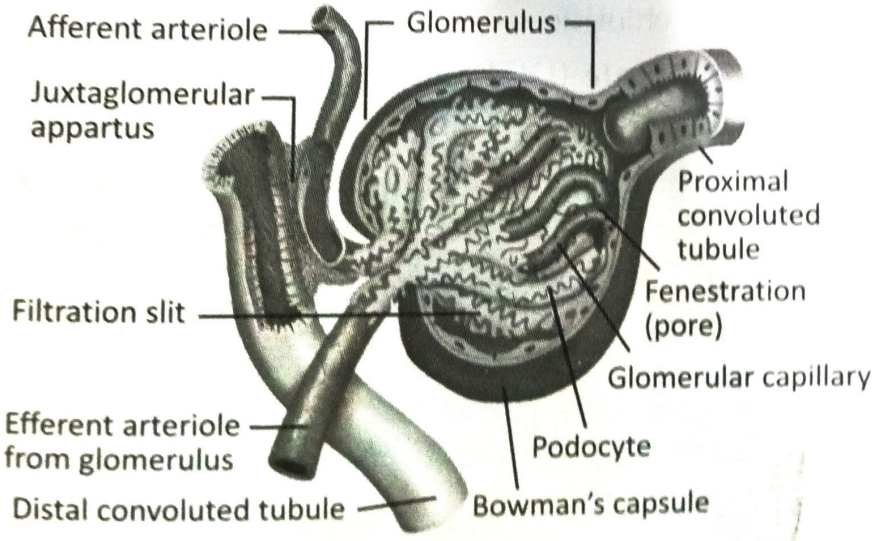

Fig. 13.5: ***Structure of Glomerulus***

Glomerular Capsule or Bowman's Capsule

Glomerular capsule is a double walled cup like structure of epithelium cells which in cortex. It surrounds the glomerulus (glomerular capillaries). Outer wall of Bo capsule is known as parietal wall. It consists of simple squamous epithelial cells. wall of Bowman's capsule is known as visceral wall. It consists of special type of cells that is podocytes which consists of small filteration slits (spaces). Blood plasma filtered in the glomerular capsule and then filtered fluid passes into the renal tubule

Renal Tubule

Renal tubule is a long tube which is a continuity of Bowman's capsule. It consists of parts-convoluted means tubule is tightly coiled.

1. **Proximal Convoluted Tubule (PCT):** It is the first part of the renal tubule convoluted (coiled) attaches to the glomerular capsule. PCT consists of cubo epithelial cells with brush like border that is microvilli. It is present in cortex further extends to medulla as loop of Henle.

   Function of PCT: Due to convolutions, filterate flows slowly and remain in PCT for longer duration so maximum amount of essential nutrients glucose, am acids, water, electrolytes are reabsorbed. Thus, selective reabsorption occurs PCT.

2. **Loop of Henle (Nephron Loop):** It is a U shaped hair pin like structure present medulla. It has descending limb lined with squamous epithelial cells and ascendi limb lined with columnar epithelial cells. It returns to the cortex to become distal convoluted tubule Loop of Henle is surrounded capillaries is called as Va recta.

   Function of Loop of Henle: Osmoregulation means maintaining water and so level in the body. Descending limb causes reabsorption of water and ascendi limb secretes sodium chloride

3. **Distal Convoluted Tubule (DCT):** It is highly coiled last part of renal tubu consists of cuboidal epithelial cells and leading into a collecting duct.

   Function of DCT: It reabsorbed water, sodium and bicarbonate ions and plays major role in acid base balance. DCT secretes hydrogen, potassium, ammonia

Renal capsule and both tubule lie within renal cortex where as the loop of Hen extends into the renal medulla.

Flow of Fluid through Nephron

Glomerular (bowman's) capsule (cortex of kidney)

↓

Proximal convoluted tubule (cortex of kidney)

↓

Loop of Henle (medulla of kidney)

↓

Distal convoluted tubule (drains into collecting tubule) (cortex of kidney)

↓

Papillary duct (medulla)

↓

Renal pelvis (urine)

PHYSIOLOGY OF URINE FORMATION

1. **Kidney form urine by following steps:**

   (a) Glomerular Filteration or Ultrafilteration

   (b) Tubular Reabsorption or Selective Reabsorption

   (c) Tubular Secreation

   (a) Glomerular Filteration or Ultrafilteration: In the first step, water and solutes of blood plasma move across the glomerulus (glomerular capillaries) into the glomerular capsule and then into the renal tubule. This takes place through the semipermeable membrane walls of the glomerulus and glomerular capsule (epithelium cells whose function is absorption and secretion).

   Glomerular filteration depends on three main pressures. One pressure promotes filteration and two pressures oppose filteration.

   1. The afferent arteriole carry the blood to the glomerulus and the efferent arteriole carry blood away from the glomerulus. The diameter of the efferent arteriole is smaller than the afferent arteriole so it gives some resistance to flow of blood which causes higher blood pressure in the glomerulus which is about 55 mmHg is known as Glomerular Blood Hydrostatic Pressure (GBHP).
   2. Capsular Hydrostatic Pressure (CHP) is the back pressure exerted due to capsular epithelium itself which opposes filteration is about 15 mmHg
   3. Blood Colloid Osmotic Pressure (BCOP) which is due to the presence of proteins in the blood. As the protein concentration (BCOP) is very high in

glomerular capillaries then water from filtrate moves back to the glomerular capillaries. BCOP also opposes filteration. This pressure is about 30 mmHg.

The Net Filteration Pressure (NFP) is the total pressure that promotes filteration is as follows

NFP = GBHP – (CHP + BCOP)

= 55 – (15 + 30)

NFP = 10 mmHg

Thus due to 10 mmHg, blood plasma (except plasma proteins) is filtered from the glomerulus into the capsular space.

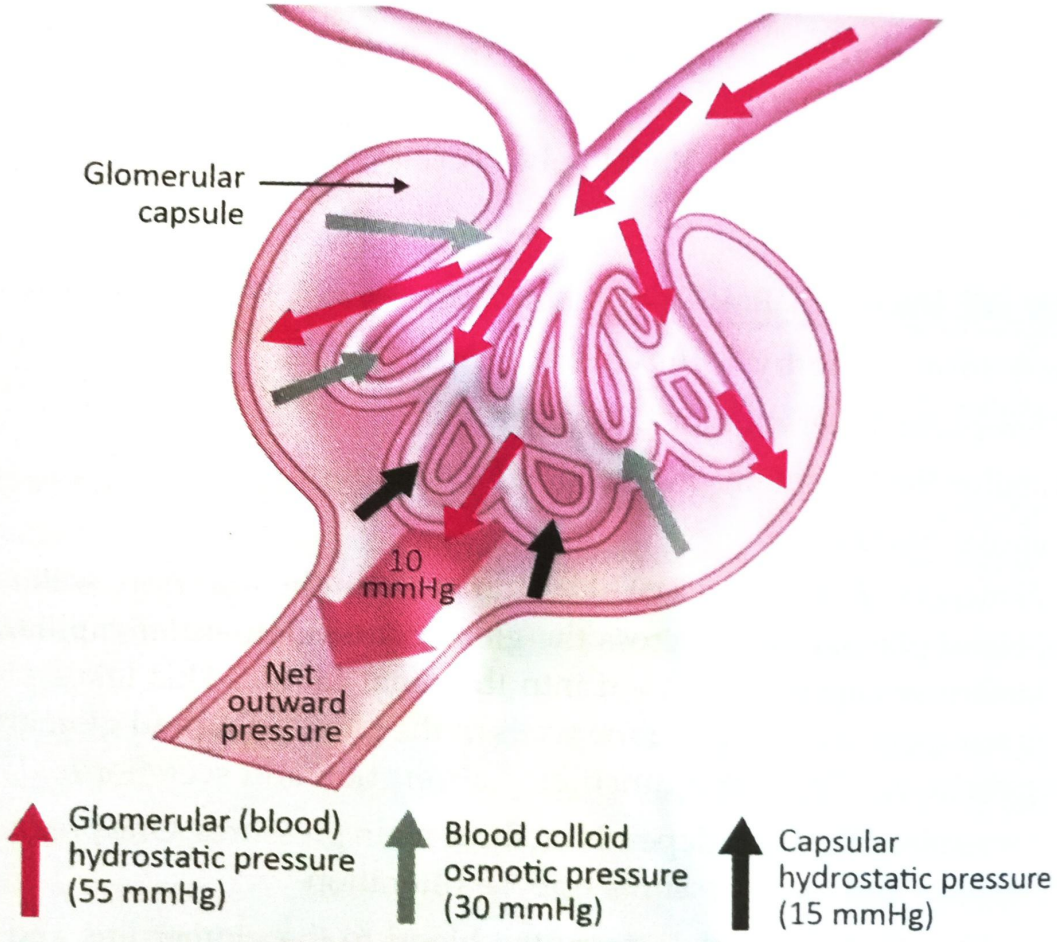

Fig. 13.6: *Net Filteration Pressure*

Filtration of constituents depends upon their molecular weight. Due to the pressure the constituents of blood are filtered in the nephron. All the constituents of blood are filtered, e.g., water, mineral salts, amino acids, ketoacids, glucose, creatinine, urea, uric acid some drugs are filtered due low molecular weight. Blood cells (RBCs, WBCs, platelets) and plasma proteins are not filtered because they all having high molecular weight.

GFR (Glomerular Filteration Rate): The volume of filterate formed by both kidneys in one minute is called glomerular filteration rate.

Filterate: 120 ml/min., 180 litre per one day

Urine: 1 ml/min., 1 litre per one day

(b) **Tubular Reabsorption or Selective Reabsorption** : As the filterate flows along the renal tubule, tubular cells reabsorb about 99% of the filterate with useful solutes. Reabsorption refers to the returning most of the filterate and many of the filtered solutes to the blood. Epithelial cells (cuboidal) of the renal tubule and collecting duct carry out reabsorption, but PCT cells makes more reabsorption. Solutes such as sodium, glucose, amino acids are reabsorbed by active (ATP) process and Water, solutes such as urea potassium, ammonia reabsorbed by passive process.

(i) High threshold substances – absorbed completely, e.g., glucose sodium, potassium, calcium chloride, bicarbonate.

(ii) Low threshold substances – absorbed to some extent, e.g., urea, uric acid, phosphate.

(iii) No threshold substances – not absorbed at all, e.g., creatinine, sulphates.

(c) **Tubular Secretion:** Here, tubular cells secrete substances like hydrogen ion, potassium ion, Ammonium ions, creatinine, Urea, Some Hormones, some drugs etc into the filtrate. By this process, the ionic, acid-base and the balance of other body fluids are maintained. Lastly urine comprises of 95% water and 5% wastes such as ions of sodium, potassium and calcium and nitrogenous wastes such as creatinine, urea and ammonia.

2. **Water Balance:** Water balance in the body is also maintained by the kidneys. Water loss through kidneys is rigorously controlled and varies from 1 litre to 1.5 liter in 24 hours. Water output (water loss) is mainly controlled by the Antidiuretic Hormone (ADH). The ADH is released into the blood by the posterior lobe of the Pituitary gland.

(a) Osmoreceptors (nerve cells) detect changes in the osmotic pressure of blood. When osmotic pressure (pressure due to proteins) of Blood is increases, i.e., water level in body decreases then osmoreceptors in hypothalamus are stimulated.

(b) The stimulation of Osmoreceptors in the hypothalamus results in increases release of Antidiuretic Hormone (ADH) from posterior pituitary gland.

(c) ADH acts on the tubules of the kidney. It increases the permeability of the distal convoluted and collecting tubules. This causes reabsorption of water from tubule into circulating blood and less urine formation by kidney. Then blood osmotic pressure in decreases and water level maintained.

(d) Conversely when water level increases, osmotic pressure decreases. Inhibition of ADH hormone and water loss from body, increases formation of urine.

Blood osmotic pressure increases and water level decreases

↓

Osmoreceptors in hypothalamus get stimulated

↓

Stimulate posterior pituitary gland and releases ADH hormone

↓

ADH acts on kidney tubules and increases its permeability

↓

Reabsorption of water by kidney tubules and less urine formation.

↓

Blood osmotic pressure lowered and water level in the body maintained.

2. **Electrolyte Balance:** The concentration of electrolytes changes in the body due to the changes in the amount of water and electrolytes. Sodium is the most common cations that exist in the extracellular fluid. As it is excreted in urine, its balance in the body is maintained by kidneys. When the amount of sodium in blood decreases Adrenal glands which are present on kidneys secrete aldosterone hormone. Aldosterone acts on kidney tubules increases its permeability and cause reabsorption of sodium.

Sodium level in blood decreases

↓

Adrenal glands on kidneys secrete Aldosterone hormone

↓

Aldosterone acts on kidney tubules

↓

Increases reabsorption of sodium

↓

Blood sodium level increases

3. **Blood Pressure Balance:**

(a) The Blood pressure is maintain by kidneys. When blood volume and the blood pressure decreases kidney secrete hormone renin into blood. Renin converts Angiotensinogen (protein forms in liver) into Angiotensin I.

(b) In blood, Angiotensinogen converting enzyme (ACE) converts Angiotensin I (Peptide Hormone) into Angiotensin-II which is a active peptide hormone.

(c) Angiotensin-II affect renal physiology in three main ways:

(i) by causing vasoconstriction of afferent arterioles and increases B.P.

(ii) It stimulate adrenal gland to secrete aldosterone hormone which causes reabsorption of sodium and water. This results in increases blood volume.

(iii) It decreases glomerular filteration rate.

Decreases Blood volume and blood pressure and sodium level

↓

Kidney secretes renin hormone

↓

Renin converts angiotensinogen into Angiotensin-I

↓

Anginotensinogen Converting Enzyme (ACE) converts Angiotensin-I into Angiotensin-II

Angiotensin-II
Vasoconstriction

Increases blood pressure and

Stimulate adrenal gland to secrete Aldosterone hormone causes reabsorption of sodium and water

↓

increases blood volume.

COMPOSITION OF URINE

Normal Constituents of Urine	Abnormal Constituents of Urine
1. Water (96%) 2. Urea (2%) 3. Uric acid, creatinine, ammonium sodium, potassium, chlorides all are about 2%	1. Albumin/Protein 2. Glucose 3. Red blood cells 4. White blood cells 5. Keton bodies 6. Bilirubin 7. Urobilinogen 8. Microbes

Abnormal Constituents of Urine and their Comment

1. **Protein that is Albumin:** The presence of excessive albumin in the urine called albuminuria indicates Nephritis, Nephrotic syndrome, Bacterial infections, mercury poisoning.
2. **Glucose:** Glucose in urine called glucosuria indicates diabetes mellitus.
3. **Red blood cells:** RBCs in urine called hematuria indicates acute inflammation of kidney.

4. **White blood cells:** WBCs in urine called leuckocytouria indicate bacterial infection in the kidney or to bladder.
5. **Pus (dead white cells with protein rich fluide):** Pus in kidney called pyuria indicate bacterial infection in the kidney.
6. **Ketone bodies:** Ketone bodies in urine called ketonuria indicates diabetes mellitus, anorexia, starvation
7. **Bilirubin:** Bilirubin in urine called bilirubinuria indicates more destruction of RBCs, liver damage
8. **Urobilinogen:** Urobilinogen (breakdown product of hemoglobin) in urine called urobilinogenuria indicates anemia hepatitis, jaundice, heart failure.
9. **Microbes:** Micobes in urine indicates infection of urinary tract, vagina.

CHARACTERISTICS OF URINE

1. **Volume:** 1 to 2 liters per day.
2. **Colour:** Yellow or amber due to pigment urochrome but varies with urine concentration and diet.
3. **Turbidity:** Transparent when fresh but becomes turbid (cloudy) upon standing.
4. **Odour:** Mildly aromatic but becomes ammonia like upon standing.
5. **pH:** Average 6.
6. **Specific Gravity (Density):** 1.001 to 1.035 higher the concentration of solutes the higher the specific gravity.

URETERS

These are thick walled narrow tubes that transport urine from kidneys to the urinary bladder. They are about 25-30 cm long and their diameter is about 3 mm. The ureters are continuous with the funnel shaped renal pelvis.

Anatomy: They consist of 3 layers of tissues:

(i) Outer covering of fibrous tissue.

(ii) Middle muscular layer of smooth muscles.

(iii) Inner layer of transitional epithelial cells.

Physiology: Peristaltic contractions of muscular walls of ureters push urine toward the urinary bladder.

URINARY BLADDER

Urinary bladder is a hollow, distensible muscular organ located in pelvic cavity at back of the pubic symphysis. It is smaller in female because uterus occupies the space and bigger in male. The shape of urinary bladder depends on how much urine it contains. When empty, it is collapsed and when filled with urine it becomes spherical or pear shaped. Its capacity averages 700-800 ml.

Anatomy: The bladder wall consists of three layers:

1. Outer layer of loose connective tissue
2. Middle layer of detrusor smooth muscles – contract during urination to excrete urine and relax to allow the bladder to store urine
3. Inner layer of transitional epithelium – stretch significantly to accommodate large volumes of urine.

Urinary bladder in floor consists of a small triangular area called **Trigone.** It has of 3 opening, 2 uretheral and 1 for urethra. Around the opening of urethra circular muscle cells or fibres form an internal urethral sphincter.

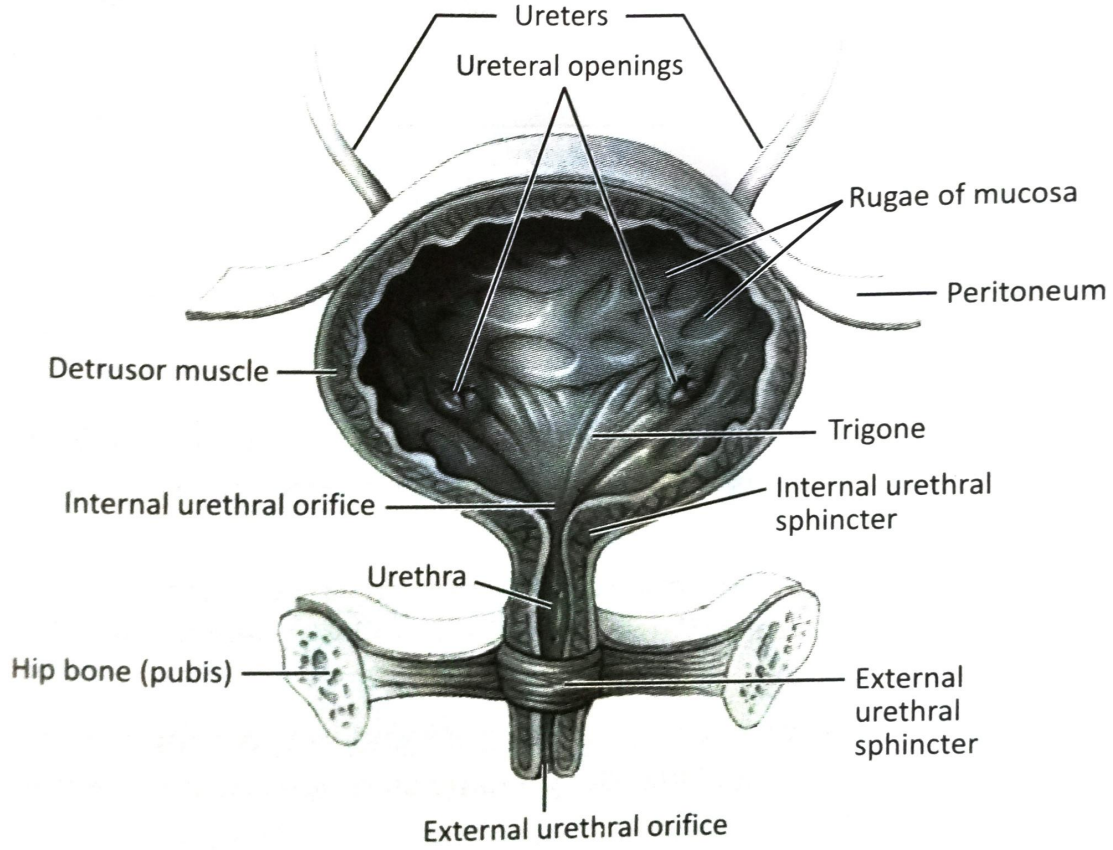

Fig. 13.7: *Urinary Bladder*

URETHRA

Urethra is the terminal portion (last) of the urinary system and passageway for urine from the body. Urethra is a fibromuscular small tube starts from the bladder to external of the body.

The urethral sphincters are two muscles used to control the flow of urine through the urethra. The internal urethral sphincter is located at the junction of the urethra and the urinary bladder. It is made of smooth muscle and is under autonomic or involuntary control. The external urethral sphincter surrounds the urethra outside the bladder that be relaxed for urination. It is made up of skeletal (striated) muscles and is under the somatic or voluntary control.

Male Urethra	Female Urethra
Male urethra is longer 20 cm	Female urethra is shorter 4 cm.
Male urethra opens at the extremity of the penis	Female urethra opens immediately in front of vaginal opening
Male urethra associated with urination and reproduction, i.e., discharge of semen (fluid contains sperms)	Female urethra associated with urination only.

MICTURITION/URINATION

Discharge of urine from urinary bladder through urethra to outside the body is called micturition or urination or voiding. Micturition is regulated by autonomic and somatic control.

1. When the volume of urine exceeds 200-400 ml, pressure within bladder increases and stretch receptors in its wall transmit nerve impulse through sensory neuron to the spinal cord.
2. These impulses propagate to micturition centre in sacral spinal cord (S2, S3) and relayed two sets of neurons (Parasymphathetic and somatic) to form Spinal reflex called micturition reflex.
3. Parasympathetic motor neurons are excited and act to contract the detrusor muscles in the bladder so that bladder pressure increases and the internal sphincter opens (relaxes).
4. At the same time, somatic motor neurons supplying the external sphincter allowing external sphincter (relaxes) to open and urine to flow out.

Volume of urine exceed 200-400 ml, pressure within bladder increases

↓

Stretch receptors transmit nerve impulse to the sacral spinal cord

↓

Stimulate micturition centre in sacral spinal cord

↓

Trigger spinal reflex called micturition

↓

Parasympathetic neuron contract the detrusor muscles in the bladder, bladder pressure increases and the internal sphincter opens

↓

Somatic motor neurons relaxes (opens) external sphincter

↓

Micturition or urination takes place

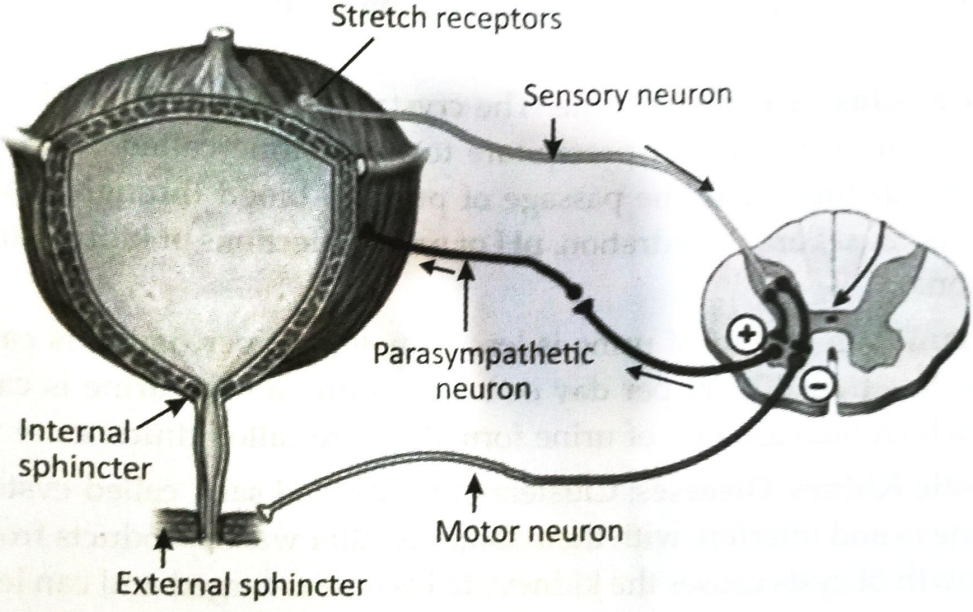

Fig. 13.8: *Micturition or Urination reflex*

DISORDERS OF URINARY BLADDER

1. **Nephritis:** Inflammation (redness, swelling, pain) of kidney due to infection of *E.coli*, Staphylococci and streptococci results in to oedema. If glomerulus is inflamed called glomerulonephritis and if many glomeruli inflamed called glomerulinephritis.

   If tubules are inflamed then tubular nephritis. If kidney and renal pelvis inflamed then known as Pyelonephritis.

2. **Nephrotic Syndrome:** It is a kidney disorder that causes body to remove much proteins in the urine, i.e., proteinuria (protein in urine). Loss of proteins from blood allows leak out of fluid from blood vessels into nearby tissue causes edema (swelling) around eye, feet, ankle, abdomen vein. Nephrotic syndrome occur due to several glomerular diseases and systemic diseases such as diabetes mellitus, cancer, AIDS.
3. **Renal Failure:** A condition in which the kidneys stop working and are not able to remove waste and extra water from the blood. Kidneys can become damaged from a physical injury or a disease like diabetes, high blood pressure or other disorders
   - **Acute Renal Failure (ACF):** Means sudden and severe reduction in glomerular filteration rate and kidney function. On treatment, it is reversible or curable
   - **Chronic Renal Failure (CRF):** Here 75% of nephron are damaged, kidney can not properly functioning and effectively not form urine (Oliguria). On treatment, it is not curable or irreversible. Its causes are glomerulonephritis, diabetes mellitus, hypertension. Treatment are either dialysis or kidney transplant.
4. **Renal Calculus or Kidney Stone:** The crystals of oxalates and phosphates salts are insoluble in urine and precipitate to form stone called renal calculus. Its symptoms include pain, the passage of pus and blood through urine and renal failure. Its causes are dehydration, pH of urine, infections of kidney and metabolic condition.
5. **Oliguria:** When output of urine is less than 400 ml per day. it is called oliguria when is less than 100 ml per day or total suppression of urine is called Anuria. Drugs which increase rate of urine formation are called diuretics.
6. **Polycystic Kidney Diseases:** Clusters of fluid-filled sacs, called cysts, develop in the kidneys and interfere with their ability to filter waste products from the blood. The growth of cysts causes the kidneys to become enlarged and can lead to kidney failure.
7. **Edema (Swelling):** It is an abnormally increase in tissue fluid which result in swelling of that part. It occurs due to increased capillary permeability, decreased concentration of plasma proteins. The net result is greater movement of fluid in to the tissue spaces causing oedema.

IMPORTANT QUESTIONS

1. Draw a well labeled diagram of Urinary system. (S-96, 97, 98, 01; W-96, 97, 98, 99)
2. Describe the structure of kidney. (S-00)

3. Draw structure of Nephron. (S-97, 99; W-96, 98, 99, 01)
4. Define Nephron (W-01)
5. How male urethra differs from female urethra? (S-01)
6. How urine is formed? (S-97, 98, 02; W-96, 98, 99 W-99, 00)
7. Give the functions of Kidney. (S-96, 97, 99; W-00, 02)
8. Explain the abnormal constituents of urine. (S-97; W-96, 01)
9. Explain the role of kidney in maintaining blood pressure. (S-99; W-97, 01)
10. Explain the role of kidney in maintaining water balance of body. (S-97)
11. Name the abnormal constituents of urine with name of disease they signify. (S-97; W-96, 01)
12. What is Nephritis? (S-00, 01; W-01)
13. What is edema? Describe it. (S-01, 02, 03; W-00, 02)
14. Name the different causes of edema. (S-98, 00, 02; W-02)
15. Explain Glycosuria, Proteinuria, Haematuria, Anuria, Diuretics. (S-96; W-01, 02)

CHAPTER 14

Endocrine System

INTRODUCTION

Function of endocrine system is to develop and regulate body functions.

Endocrinology is the study of effects of different hormones secreted by the endocrine glands.

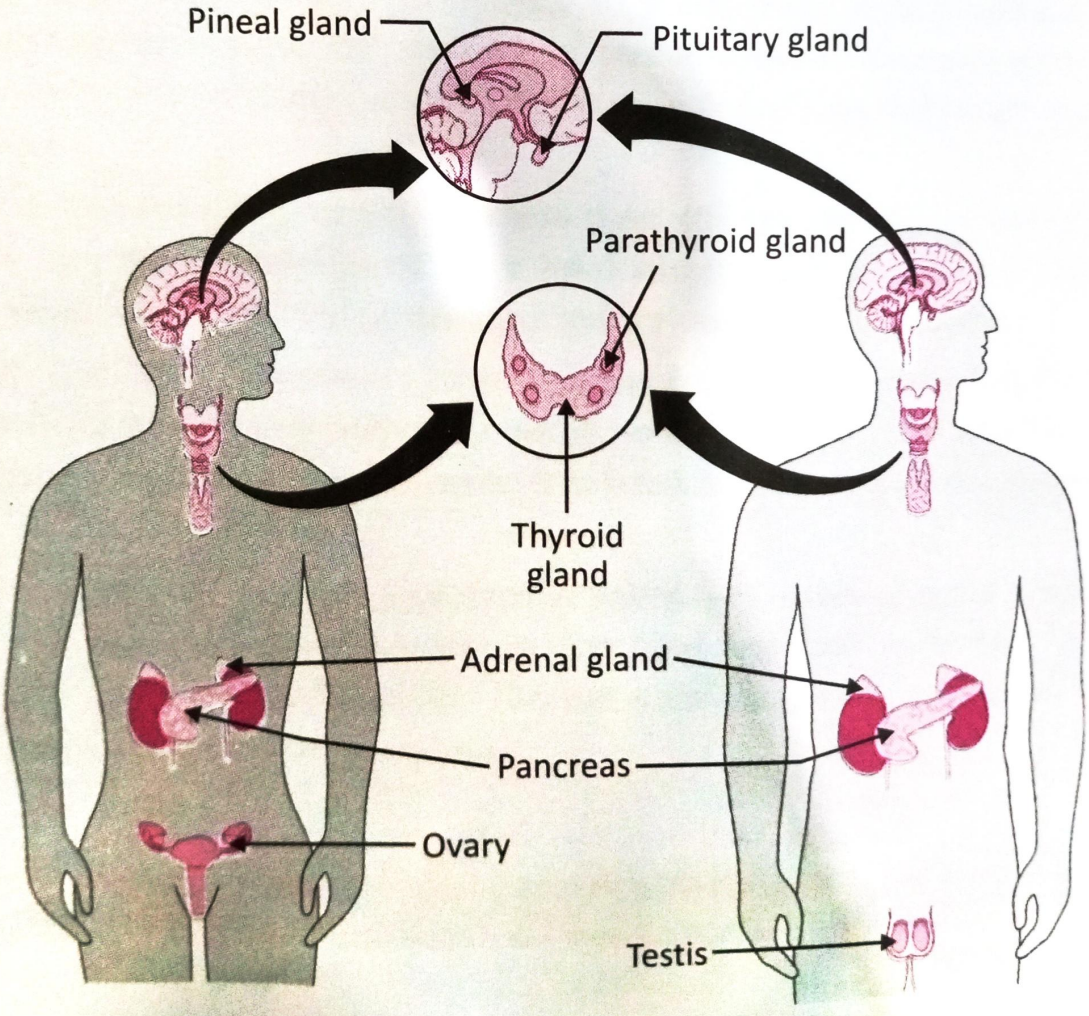

Fig. 14.1: ***Endocrine System***

Human Body contains two types of glands:

1. Exocrine glands
2. Endocrine glands

Exocrine Glands	Endocrine Glands
1. Exocrine glands have ducts or tubes.	1. Endocrine glands are ductless (do not have ducts or tubes)
2. They secrete theirsecreations into ducts.	2. They pour their secretions directly into the blood.
3. Secretions are enzymatic, excretory (sweat)	3. Secretion contains hormones.
Examples: Salivary glands, sweat glands, gastric glands.	Examples: Pituitary gland, thyroid gland, adrenal gland.

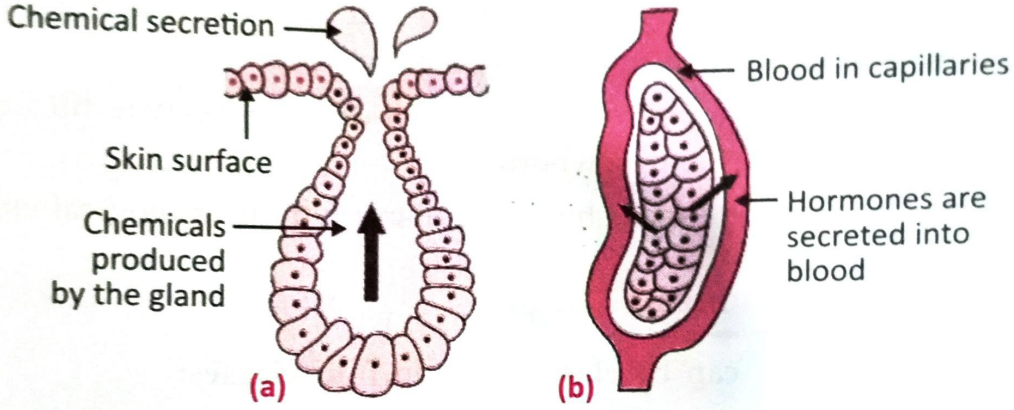

Fig. 14.2: *(a) Exocrine Gland; (b) Endocrine Gland*

Important endocrine glands are:

1. Pituitary gland – At the base of the brain.
2. Thyroid gland – In the neck and in front of trachea.
3. Parathyroid gland – In the neck and each side of thyroid gland.
4. Adrenal glands – On the kidney.
5. Pancreatic gland (Islets of Langerhans) – Distributed in Pancreas.
6. Pineal gland – Near corpus callosum in the brain.
7. Thymus Gland – Behind the sternum between two lungs
8. Ovaries – One on each side of uterus.
9. Testes in male – In scrotum.

HORMONES AND THEIR FUNCTIONS

Definition

The secreations of the endocrine glands are called Hormones.

Hormones are the chemical substances secreted by the endocrine glands and carr by blood to another organ/tissue, there by controlling their activity. Thus, hormo produced at one site and have action at the other site. Hormones are chemical messeng Chemically hormones are peptides, steroid and amines of amino acids.

Functions of Hormones

1. Hormones control growth and development.
2. Hormones help to regulate chemical composition and volume of inter environment.

   Metabolism and energy balance, contraction of smooth and cardiac musc glandularsecretions, some immune system activities.
3. Hormones helps in basic reproductive processes like puberty fertilization, delive nourishment of foetus and newborn.
4. Hormones help in the establishing circadian rhythms (biological clock).

Chemical Nature of Hormones

Chemically, the hormones can be classified into four classes:

1. **Steroids:** Hormones have steroid nucleus and are derived from cholesterol, e.g Hormones of Adrenal cortex–Aldosteron, Hormones of Gonds– Esrroge Testesteron and Progesteron.
2. **Biogenic Amines:** Synthesized from amino acids Catecholamines, i.e. Noradrnaline, Adrenaline secreted by the adrnal medulla.
3. **Protein or Peptide Hormone:** These consists of chain of amino acids, e.g., insuline Glucagon, TSH, FSH, GH and Relaxin.
4. **Fatty acid derived Hormones or Eicosanids:** Hormones are derived from arachidonic acid (fatty acid), e.g., Prostaglandins and Leukotrines.

Mechanism of Hormone Action

Blood transport hormones to all cells of the body. But only target cells (cells act due to hormones only) have hormone receptors respond to hormones. (Receptors are the macromolecule, protein or glycoprotein with which the hormones bind chemically and produces the response). The hormone receptors are present on the cell membrane (membrane recep or inside the cell (Intracellular receptors).

Following are the mechanism of Hormone actions:

1. **Mode of Hormone action through membrane receptors:** Lipid insoluble hormones like Biogenic amines and Protein hormones bind to specific receptors located on the cell membrane. The hormone receptor complex activates G-protein molecules on the inner surface of the cell membrane. Activated G-Protein molecules then activate the intracellular enzyme adenylate cyclase which converts ATP(Adenosine Triphosphate) to cyclic AMP (Aenosine monophosphate). In this process, For cell activation the first messenger is hormone and second messenger is cyclic AMP. The cyclic AMP then activates Protein kinase enzyme which phophorylases (Transfer of phosphate molecule to a protein for specialized task) other enzymes in the cell for the physiological responses.
2. **Mode of Hormone action through intracellular receptors:** Lipid solublesteroidal and thyrod hormones binds with specific intracellular receptors present in the cytoplasm of the cell forming a hormone-receptor complex that enters the nucleus. In the nucleus, hormone receptor complex binds to a specific regulatory site of DNA and through gene expression forms new messenger RNA(mRNA) under the direction of which new protein will be synthesized by ribosomes. This new protein intiates change in cell activity which is the chracteristics of the hormone.

HYPOTHALAMUS

1. Hypothalamus is an antomical and physiological connection between the nervous system and the endocrine system. Hypothalamus is connected to pituitary gland.
2. Hypothalamus contain several groups of neurosecretory cells called nuclei which produces two types of hormones:
   (i) Releasing hormones (stimulate the secretion of pituitary gland).
   (ii) Inhibiting hormones (inhibit the secretion of pituitary gland). Also hypothalamus is the master of Pituitary gland.

1. PITUITARY GLAND

1. Pituitary gland is located in the brain and attached to the hypothalamus.
2. Pituitary gland is called master gland because it secretes many hormones that control the secreation of other endocrine glands, e.g., thyroid gland, adenal gland, ovary.
3. **Feedback Mechanism of Pituitary gland:** Hypothalamus stimulates Pituitary gland. Pituitary gland stimulates other endocrine glands.

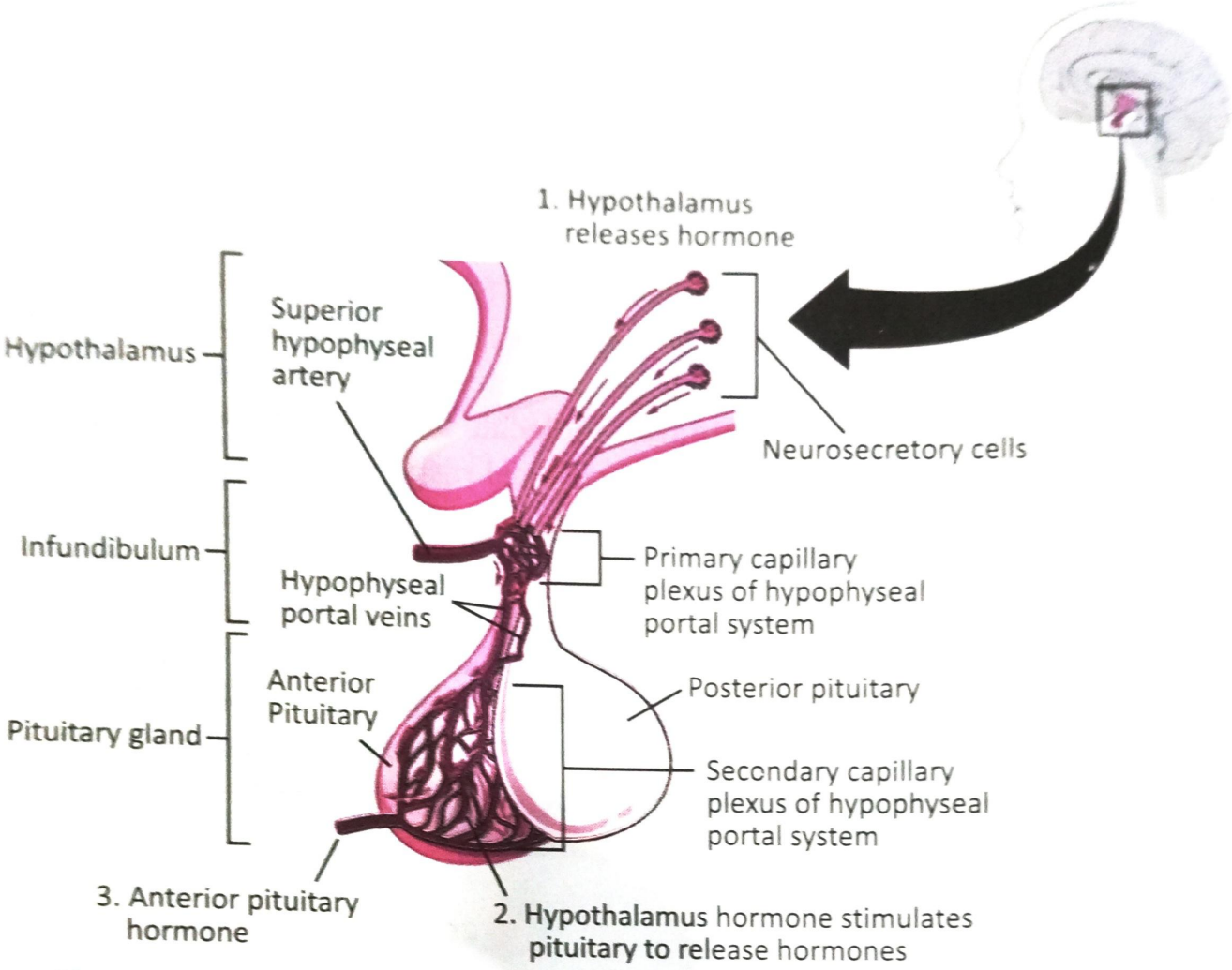

Fig. 14.3: ***The parts of the Pituitary Gland and its Relation to the Hypothalamus***

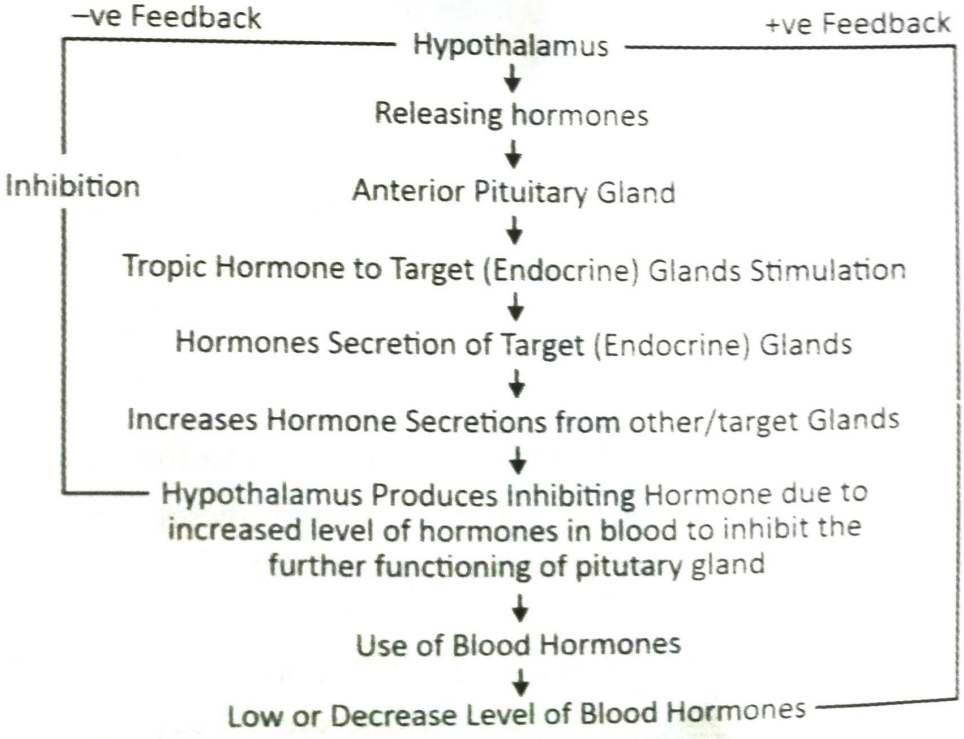

(i) +ve Feedback mechanism (↓ Level of Blood Hormones):

1. When there is less hormones in blood, then hypothalamus produces releasing hormone. This releasing hormone stimulate anterior lobe of pituitary gland.
2. Anterior lobe of pituitary gland produces tropic hormone.
3. This tropic hormone stimulates the target glands (other endocrine glands).

   Due to tropic hormones, other endocrine glands releases their hormones in blood. Thus, level of hormones in blood increases

(ii) –ve Hypothalamus Feedback Mechanism (↑ Level of Blood Hormones):

When level of hormones in blood is increases, hypothalamus stops the secretion of releasing hormone and produces inhibitins hormone and stops the stimulation of pituitary gland.

Hormones of Pituitary Glands

Anatomically Pituitary gland is divided into Adenophysis and Neurohypophysis

Part of Pituitary	Hormones	Action/Physiological role/Function
Adenophysis (Anterior lobe)	1. Growth Hormone (GH)	1. Growth of body specially muscles and bones of limbs 2. Stimulates protein synthesis
	2. Thyroid Stimulating Hormone (TSH)	Controls structure and functioning of thyroid gland and control the release of thyroid hormone
	3. Adrenocorticotropic Hormone (ACTH)	Controls structure and functioning of adrenal glands and control the release of its hormones corticoids
	4. Prolactin (PRL) or Lactogenic Hormone	Stimulate mammary glands of breast and its milk secreation.
	5. Follicle Stimulating Hormone (FSH)	Spermatogenis in males and stimulate growth of ovarian follicles (egg) in females, release of estrogen from ovaries in females.
	6. Luteinizing Hormone (LH)	Secreation of testosterone in male and in females with FSH, it triggers ovulation, stimulates conversion of ovarian follicles into corpus luteum and release of Progesteron from corpus luteum
	7. Melanocyte Stimulating Hormone (MSH)	Exact role is not, but if present in excess can cause darkening of skin.

Part of Pituitary	Hormones	Action/Physiological role/Function
Neurohypophysis (Posterior lobe)	Oxytocin	Stimulates contraction of smooth muscle of uterus during childbirth. Stimulates mammary glands in the breast to secrete milk
	Antidiuretic Hormones (ADH) or Vasopressin	By acting on kidney, maintains water balance, i.e., Stimulates reabsorption of water and decreases urine volume and causes constriction of blood vessels thus increases blood pressure.

2. THYROID GLAND

The throide gland is the largest endocrine gland which is butterfly shaped or H-shaped. It is composed of two lateral lobes which are located on either sides of the trachea.

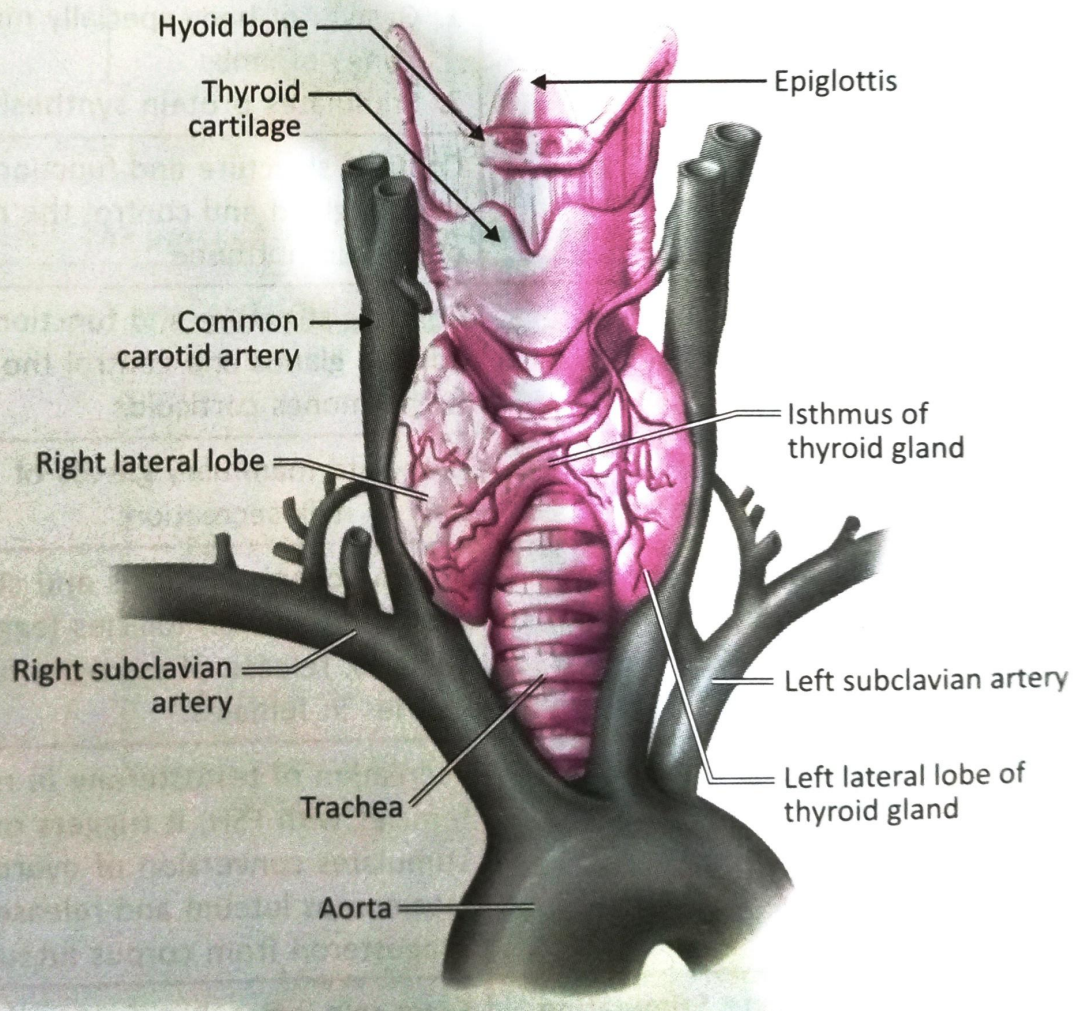

Fig. 14.4: *Thyroid Gland*

Thyroid follicle is composed of follicles which consist of follicular cells. The follicular cells synthesise two hormones:

1. Tri-iodothyronine (T_3)
2. Thyroxine or Tetraiodothyronine (T_4)

T_4 is converted into T_3 in pheripheral tissue. These hormones released under the influence of TSH of anterior pituitary.

Functions of Thyroid Glands

1. **Metabolism:** They control the metabolism of proteins, fats and carbohydrates and hence regulate growth of the body tissues. Also mentain BMR (Basal metabolic rate) and enhances heat production. Thus, maintains body weight.
2. **Tissue Growth and development**
3. **Regulate the activity of Nervous system:** Lakh of thyroid hormones causes mental retardation.

3. PARATHYROID GLANDS

It is situated on the dorsal surface of thyroid gland. These are four in number and named as superior and inferior parathyroid glands. Structurally parathyroid gland consists of compact mass of epithelial cells.

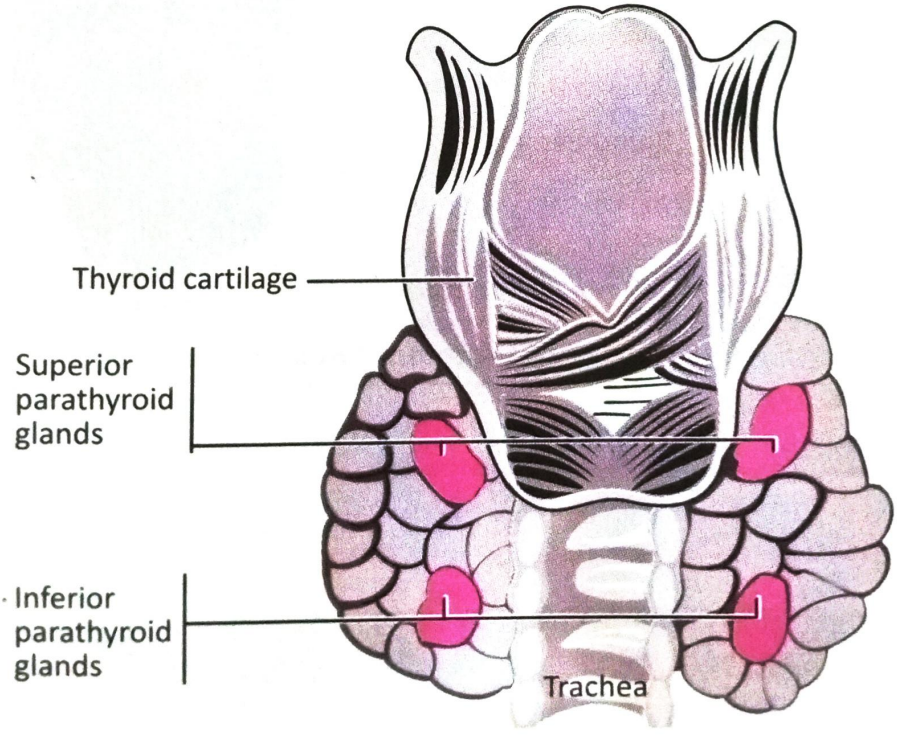

Fig. 14.5: ***Parathyroid Glands***

Parathyroid gland secretes a protein hormone called as parthyroid hormone Parathormone (PTH).

1. It increases calcium level in the blood.
2. It draws calcium from from bones and increases calcium absorption from intestine.
3. It regulates calcium and phosphate balance between blood and other tissues.
4. It reduces calcium loss through urine.

4. ADRENAL GLANDS

Adrenal glands are paired glands and located at the top of the kidneys.

Each gland composed of two types of tissues:

(i) Externally or outside adrenal cortex

(ii) Internally or at the centre adrenal medulla

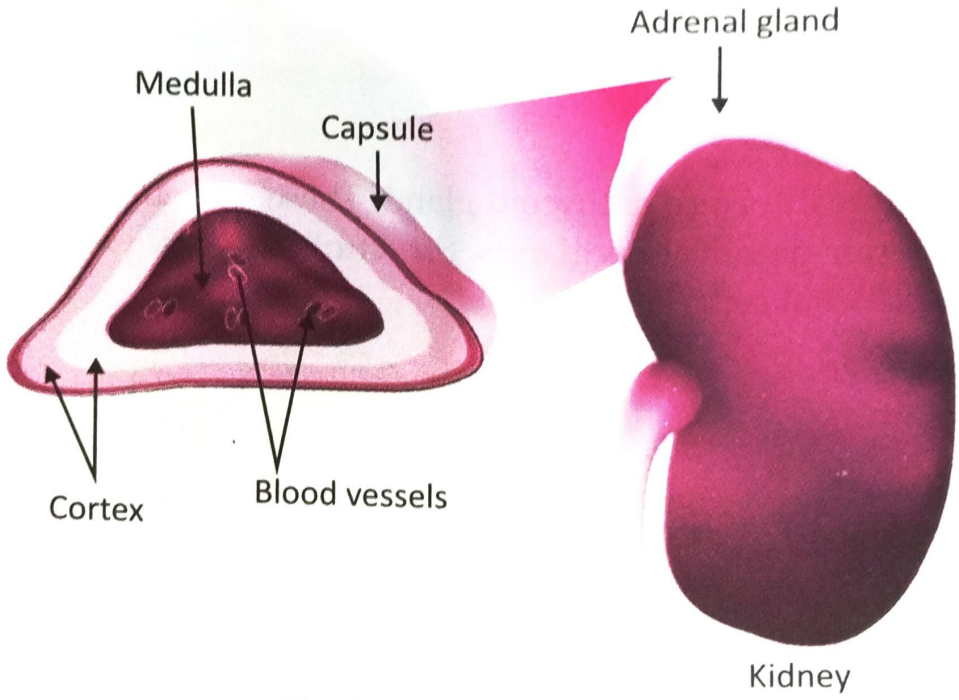

Fig. 14.6: *Adrenal Gland*

Hormones of Adrenal cortex

Adrenal glands	Hormones	Actions
Adrenal cortex hormones	1. Glucocorticoids-secreation of glucocorticoids is under the control of ACTH of anterior pituitary	(a) Glucose formation Gluconeogenis, i.e., synthesis of glucose (carbohydrate) from non-carbohydrate such as aminoacids and glycerol. (b) Lipolysis – breake down of fats stored in adipose tissue to fatty acids and release into blood. (c) Protein break down, i.e., Proteolysis-degradation of proteins into amino acids.
		(d) Anti-inflammatory reactions-Glucorticoids retards the activities of WBCs that involed in inflammatory reaction. (e) Supression of immune responses by inhibiting antibodies and lymphocytes and helpful in organ transplant. (f) Resistenceto stress, e.g., fasting, bleeding, infection.
	2. Mineralocorticoids-Aldesterone is the main mineralocorticoids. Its function is controlled by rennin angiotensin system.	1. Water and Electrolyte balance 2. Reabsorption of sodium and water 3. Excretion of potassium
	3. Sex corticoids or androgens	Develop external sexual characteristics in males, i.e., hair pattern (axial, pubic, facial).

Hormones of Adrenal Medulla

Part of Adrenal gland	Hormone	Action
Adrenal Medulla Hormones	Adrenaline and Noradrenalin	Initiate stress reponses, Stimulate sympathetic nerves of autonomic nervous system during stress produces actions like increase B.P, heart rate

5. PANCREAS GLAND (ISLETS OF LANGERHANS)

Pancreas is a composite (heterocrine) gland, i.e, acts as both exocrine and endocrine gland.

Exocrine gland that is Pancreas drained pancreatic juice in pancreatic duct and discharge into the duodenum.

Endocrine gland because Islets of Langerhans (group of cells) secretes insulin, Glucagaon, somatostain hormones into the blood.

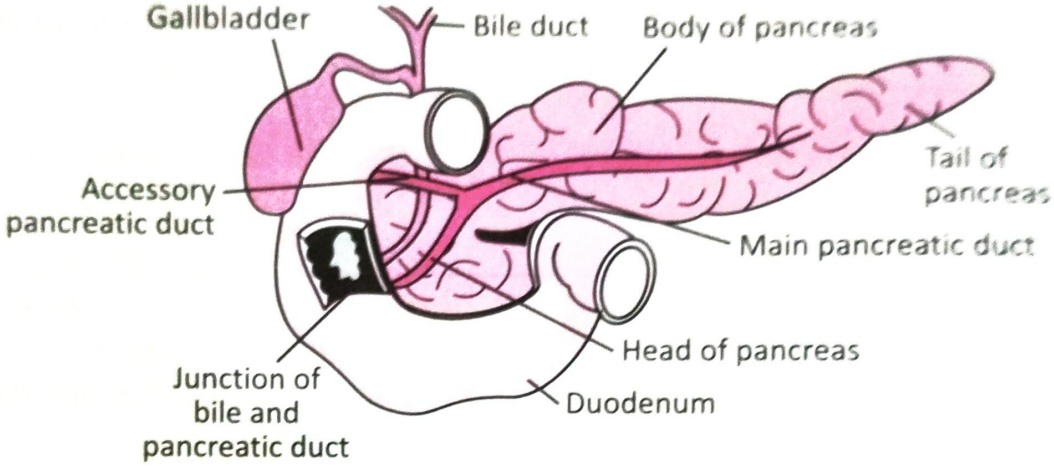

Fig. 14.7: ***Pancreas***

Three types of cells and they pour their secretions directly into the blood:

(i) Alpha cells secrete glucagaon hormone

(ii) Beta cells secrete insulin hormone

(iii) Delta cells secrete somatostatin

Pancreatic Hormones

Endocrine cells of Pancreas	Hormone	Action
Alpha cells	Glucagaonacts on liver, adipose tissue	**Increases blood glucose level by:** 1. Breakdown of glycogen to glucose in liver. 2. Promoting conversion of other nutrients such as amino acids and lactic acid into glucose in liver 3. Enhancing release of glucose into blood.

Endocrine cells of Pancreas	Hormone	Action
Beta cells	Insulinacts on liver, Muscles Adipose tissue	Lowers Blood glucose level by: 1. Stimulating transport of glucose from blood to muscles and adipose tissue, i.e., is uptake of glucose by liver. 2. Conversion of glucose into glycogen in liver and muscles. 3. Promote synthsis of fats from glucose by adipose tissue.

6. PINEAL GLAND

The Pineal gland is located in the brain near the corpus callosum between the right and left hemispheres. The pineal gland produces melatonin but its functions are not fully understood but melatoin helps in maintaining circadian rhythm and regulate reproductive hormones.

7. THYMUS GLAND

It is situated in the superior mediastinum, posterior to sternum between lungs. It is soft, pinkish, bilobed mass of lymphoid tissue.

It is a prominent gland at birth but gets gradually atrophied in the adult, so it is called temporary gland.

Functions of Thymus Gland

Thymus plays an important role in development of immunity as it is involved in maturation of T lymphocytes.

Thymosin promotes production of antibodies by providing humoral antibodies.

8. HORMONES OF OVARIES (FEMALES)

In females, a pair of ovary is located in the abdominal cavity. Ovary performs the functions of both primary sex hormones (production of ovum or egg) and endocrine (production of Estrogen and progesterone).

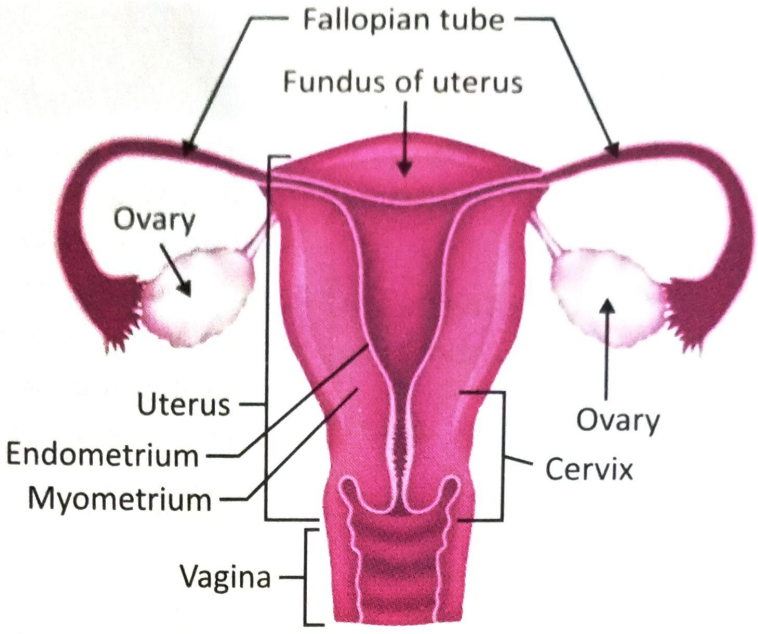

Fig. 14.8: ***Female Reproductive System***

Table 14.1

Estrogen	Progesterone
1. Secreted by ovary before and after ovulation	1. Secreted by ovary after ovulation
2. Estrogen is mainly produced by growing ovarian or graaffin follicle (some amount by corpus lutem)	2. Progesterone is mainly produced by ruptured and emptied graaffin follicle called corpus lutem.
3. Secretion of estrogen is largely controlled by FSH of pituitary gland	3. Secretion of progesterone is largely controlled by LH of pituitary gland
4. Estrogen controls the appearance and maintainance of secondary sex characters. (Female pattern), regulate menstrual cycle.	4. Progesterone controls the growth and maintainance of endometrial of uterus to support pregnancy. prepare mammary glands for lactatation, high level of Progesterone inhibit ovulation

Relaxin: Secreted by corpuslutem Increases flexibility of Pubic symphysis during pregency and relax uterine cervix during labour and delivery.

9. HORMONES OF TESTES (MALES)

Functions of Testosterone

1. Regulate spermatogenesis and male patern

2. Promotes and development and maintenance of male secondary sex characteristics such as beard, moustache.

Endocrine Glands and Associated Diseases

Glands	Hormone	Hyposecreation	Hypersecretion
Pituitary Gland	Growth Hormone	**Dwarfism:** Short stature average adult height among people with dwarfism is 4 feet	Gigantism in childrens acromegaly in adult excessive growth and height
	Antidiuretic Hormone	**Diabetes Insipidus:** More than 10 litres urine daily causing dehydration and extrme thirst (polydipsia)	Decreases urine
Thyroid Gland	Thyroxin Hormone	Cretinism (infant) mental retardation, stunted growth (dwarfism) **Myxedema (Gull's disease):** In adults-face look puffy, muscular weakness, lethargy, lacks intelligence and reoroductive failure.	**Exophthalmia Goiteror Grave's disease:** bulging of eye balls (exophthalmus) nervousness, irritability tremors.
Parathyroid Gland	Parathyroid Hormone	**Hyperparathyrodism:** Increases blood calcium level and causes decalcification or demineralization of bones (calcium from bones deposit in blood) leading to softening, bending and fracture of bone. This is known as osteoporosis.	**Hyporparathyrodism:** Lowers blood calcium level. This increases excitability of nerves and muscles causing muscle twitch and spasms known as parathyroid tetany and hypocalcemic tetany.
Adrenal Cortex of Adrenal Gland	Glucocorticoids Mineralo-corticoids	**Addison's Disease:** Nausea, vomiting, diarrhoea, weight loss, lethargy, low sugar level	**Cushing Syndrome:** Obesity, High sugar level, high B.P. in male, excessive hair growth (Hirsutism), in females beard, moustache etc.
	Aldesterone	—	**Aldesteronism (Conn's disease):** High plasma Na^+ rise in blood volume, high blood pressure, kidney damage.
	Sex corticoids	—	**Adrenal virilism:** Beard, moustache and male voice in women.

IMPORTANT QUESTIONS

1. Explain with example, feedback mechanism of secretion of hormones. (S-98; W-99)
2. Define hormones. List endocrine glands withlocation. (S-96, 97, 98, 02, 03; W-96, 97, 99, 00, 01)
3. Mention the hormones of Posrerior gland. Define hormone. (S-96, 98, 02)
4. Name the hormones of anterior pituitary gland and state the effect of hypersecreation and hyposecreation of pituitary gland. (S-97, 98; W-97, 01)
5. Name the disease caused by hyposecreation and hypersecreation of growth hormones and thyroid hormones. (S-96)
6. What are the hormones secreted by Posterior lobe of Pituitary lobe of pituitary gland? Mention their effect. (S-00, 03; W-00)
7. Which gland is called as master gland? (W-98; S-01)
8. Give functions of thyroidgland. (S-99)
9. What are the hormones of thyroide gland? How they are regulated. (S-98, 03)
10. Describe:
    (a) Hyperthyroidism
    (b) Hypothyroidism (S-00, 02; W-00)
11. Name three layers of adrenal cortex and write their secreations. (S-01)
12. What are mineralocorticoids? (S-99; W-01)
13. Mention the activities controlled by glucocorticoid. (W-00, 01)
14. Give the effects of hypo and hypersecretion of adrenal cortex. (S-98, 00; W-02)
15. Mention the hormones of Pancreas. (S-01)
16. Explain the role of Insuline and glucagaon in the body. (S-01)
17. Justify –Pancreas is both the endocrine as well as exocrine gland. (S-97, 00; W-02)
18. Explain the role of oestrogen and progesterone in body. (W-97)

15

CHAPTER

Reproductive System

FEMALE REPRODUCTIVE SYSTEM

Reproduction is the one of the important character of life. New species are produced as a result of reproduction and genetic material is passed from one generation to the next generation that is from parent cells to daughter cells.

The functions of the female reproductive system are:

1. Formation of ova (egg)
2. Reception of sperm from male.
3. Fertilization and fetus development
4. Child birth
5. Lactation

Female Reproductive System

External Genitalia (vulva)	Internal Genitalia
1. Mons 2. Labia Majora 3. Labia Minora 4. Clitoris	1. Vagina 2. Uterus 3. Fallopian Tubes 4. Ovaries

A. EXTERNAL GENITALIA (VULVA) OR EXTERNAL GENITAL ORGANS

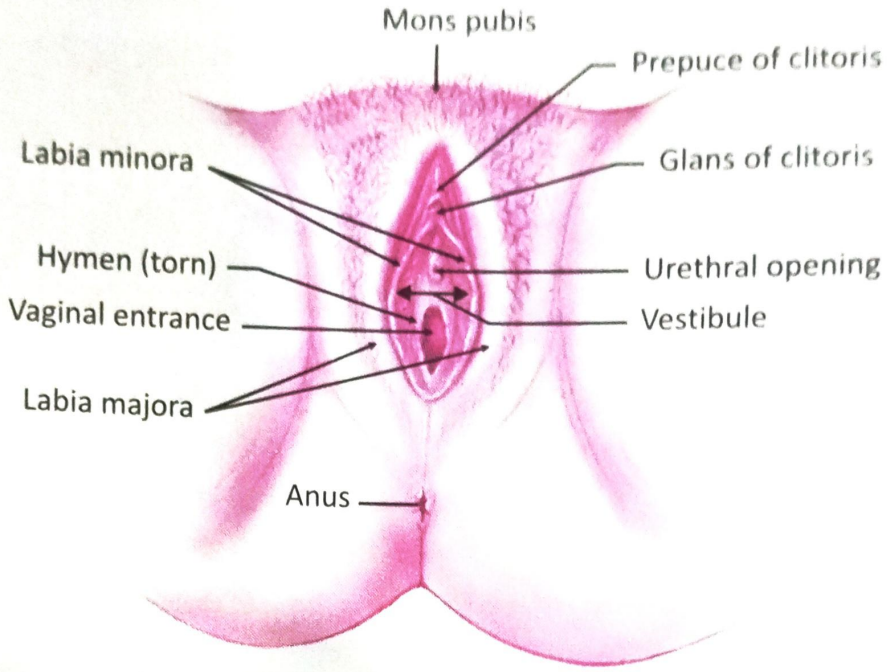

Fig. 15.1: ***External Genital Organs***

Mons Pubis

It is an elevation of adipose tissue covered by skin and pubic hair. It is present anteriorly to the vaginal and urethral opening. It acts as cushion to the pubic symphysis.

Labia Majora

These are two longitudinal folds of skin, extended from mons pubis inferiorly and posteriorly. They contain adipose tissue, sebaceous glands and sweat glands and they are covered by pubic hair.

Labia Minors

These are two smaller folds. They lie medially to the labia Majora. They do not contain pubic hair and adipose tissue. They contain few psudoriferius that is sweat glands, but contain many sebaceous glands. Prepuce of Clitoris is a point where the labia minora unite which covers the body of the clitoris.

The region between the labia minora is knowns as vestibule which consists of hymen, vaginal orifice, external urethral orifice. The vaginal orifice is the opening of the vagina to the exterior, occupies larger portion of vestibule and is bordered by hymen. Above the vaginal orifice, the opening of the urethra to the exterior, i.e., external urethral orifice is present.

Clitoris

It is a small cylindrical mass of erectile tissue lined with nerves. It is situated at anterior junction of labia minora. The clitoris has role in sexual excitement in the females.

Hymen

It is thin layer of mucous membrane. It partially occludes the opening of the vagina and normally it is incomplete to allow passage of menstrual flow.

Vestibular Glands

They are also known as Bartholins glands. They are situated one on each side of vaginal opening. They are about the size of pea and have ducts. The ducts open at vestibule. They secrete mucus that keeps vulva moist.

B. INTERNAL GENITAL ORGANS

1. Vagina

It is fibromuscular tube of about 10 cm in length. It is a connecting link between external and internal organs of reproduction. Superiorly, it is attached to the uterus.

Structure of Vagina

It consists of three layers:

(i) Outer covering or adventitia of areolar tissue. (Connective tissue)

(ii) Middle layer or muscular is of smooth muscles. (Muscular tissue)

(iii) Inner layer or mucosa made up of stratified squamous epithelium that forms rugae. (Epithelium tissue)

Lactobacillus acidophilus bacteria are present in vagina which secrete lactic acid which inhibits the growth of microorganism in vagina.

Functions of Vagina

1. It acts as outlet for menstrual flow.
2. It acts as receptacle for the penis during sexual intercourse.
3. It provides elastic passageway for the child birth.

2. Uterus

It is a hollow muscular pear shaped organ lies in the pelvic cavity. It is 7.5 cm long, 5 cm wide, 2.5 cm thick, weight about 30-40 gm in non pregnant females. After pregnancy,

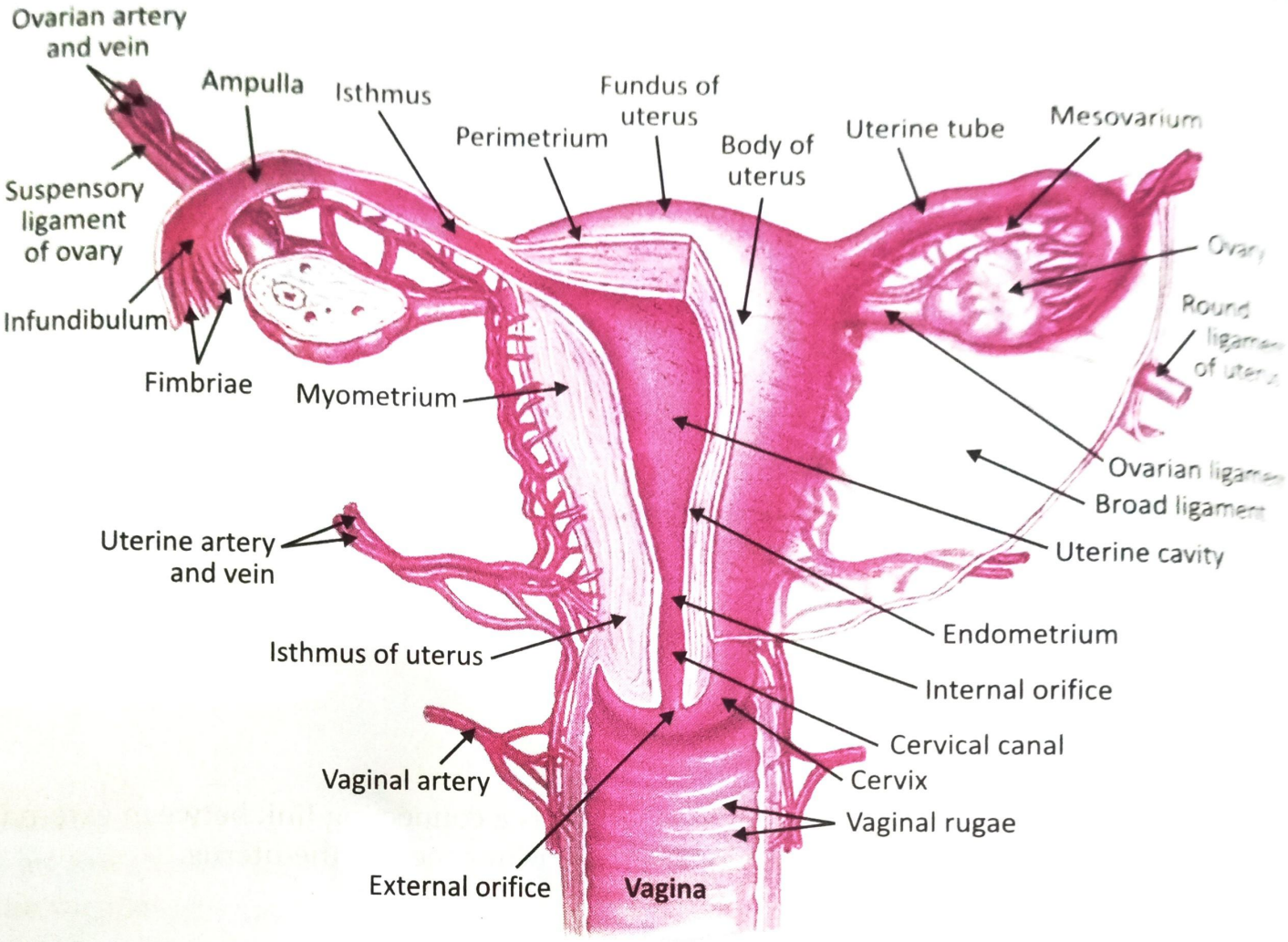

Fig. 15.2: ***Internal Genital Organs of Female Reproductive System***

the size of uterus increases but after menopause (when menstrual cycle is stopped) it becomes smaller and atrophied. (Not functioning)

Parts of Uterus

Anatomically uterus are divided into fundus, body and cervix.

(i) **Fundus:** This is dome shaped upper portion in which the fallopian (uterine) tubes connect to uterus.

(ii) **Body:** It is main central portion of uterus. It is continuous with cervix. The interior of the body of the uterus is called as uterine cavity.

(iii) **Cervix:** Lower portion of the uterus is called as cervix. It opens into vagina. It connects vagina with the uterine cavity. Interior of the cervix is called canal.

Structure (Histology) of Uterus

The wall of uterus is composed of three layers:

(i) **Perimetrium (Serosa):** Outer layer of simple squamous epithelium and areolar connective tissue.

(ii) **Myometrium:** This is the middle layer of uterus and consists of three layers of smooth muscles. These muscles contracts during delivery due to oxytocin hormone released from pituitary gland. It is thickest in the fundus and thinnest in the cervix.

(iii) **Endometrium:** It is inner layer of uterus and consists of columnar epithelium cells, mucus secreating endometrial glands and blood vessels.

Functions of Uterus

(i) It serves as a pathway for sperm deposited in the vagina and goes to uterine tubes.

(ii) It provides site for implantation of fertilized ovum (attachment of fertilized ovum to the wall of uterus) and starts pregnancy

(iii) It is a site for development of foetus into baby during pregnancy. It also takes part in placenta formation.

(iv) During delivery (childbirth), uterus contracts which help to expel fetus out of the body.

(v) When implantation does not occur, uterus cause menstrual flow during reproductive age.

3. Fallopian or Uterine Tubes or Oviducts

They are about 10 cm long muscular tubes lies on each side of the uterus.

Each tube has four parts:

(i) **Fimbrae:** Finger like ciliated projections called fimbrae which capture the ovum (egg) from the surface of ovary.

(ii) **Infundibulum:** It is a funnel shaped opening near the ovary to which fimbrae are attached.

(iii) **Ampulla:** Widest and longest part of tube in which Fertilization usually takes place.

(iv) **Isthmus:** Constricted portion at the body of the uterus. Connects ampulla to the uterine cavity.

Uterine Tubes Composed of three Layers

(i) External serosa consists of ciliated epithelium.

(ii) Middle mucosa consists of columnar ciliated epithelial cells.

(iii) Internal muscularis consists of (smooth muscles).

Functions of Fallopian/Uterine Tubes

(i) Uterine tubes transfer ovum (egg) from the ovary to uterus by peristalsis and ciliary movements.

(ii) Mucus secreted by ciliated epithelium in uterine tubes provides ideal conditions for movement of ova and spermatozoa.

(iii) Fertilization of ovum usually takes place in the uterine tube (at the junction of Ampulla & Isthmus) and then zygote moves into uterus for implantation.

4. Ovaries

1. Ovaries are the female gonads or sex glands that produces ovum (egg). These are endocrine glands and produces sex hormones estrogen and Progesteron. The Pair of ovaries lie in a shallow fossa on the lateral walls of pelvis. Each ovary is present on the either side of the uterus.
2. The ovaries are 2.5 cm long, 2 cm wide and 1 cm thick oval in shape. Each ovary is attached to upper part of the uterus by the ovarian ligament.

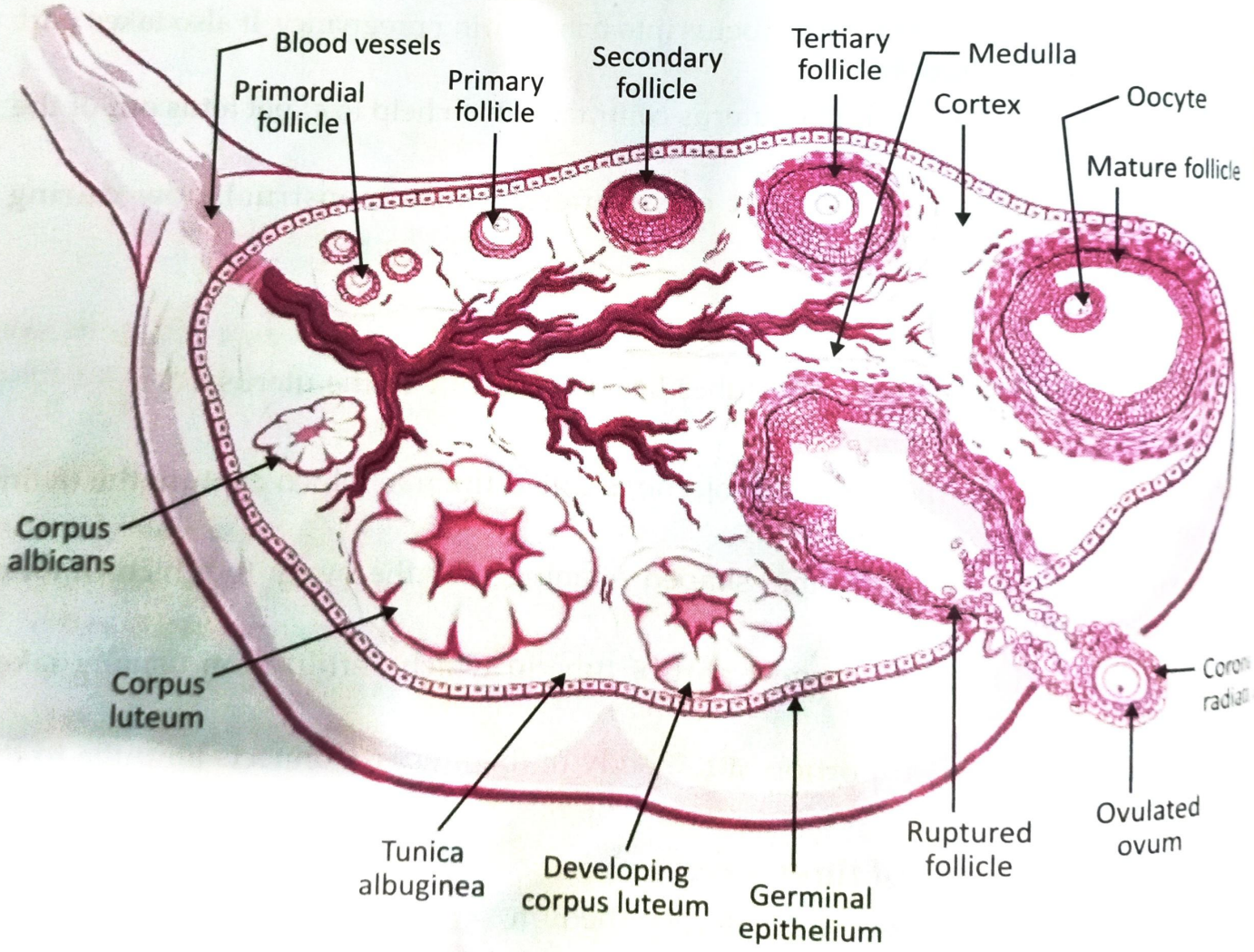

Fig. 15.3: *Structure of Ovary*

3. Each ovary contains a hilum through which blood vessels and nerves enter and exit.
4. **The ovaries has four layer of tissue:**
   (i) **Germinal epithelium:** Outermost layer. It is made of simple cuboidal cells
   (ii) **Tunica albuginea:** A collagenous Connective Tissue layer.
   (iii) **Cortex:** It is also outer layer consists of ovarian follicles.
   (iv) **Medulla:** It is the central portion of ovary and consists of blood vessels, nerves, fibrous tissue

Ovarian follicles sometimes called Graffin follicle are the basic units of female reproductive system contains a single oocyte (immature ovum or egg cell). After puberty, one of the ovaries releases a mature egg (ovum), once a month.

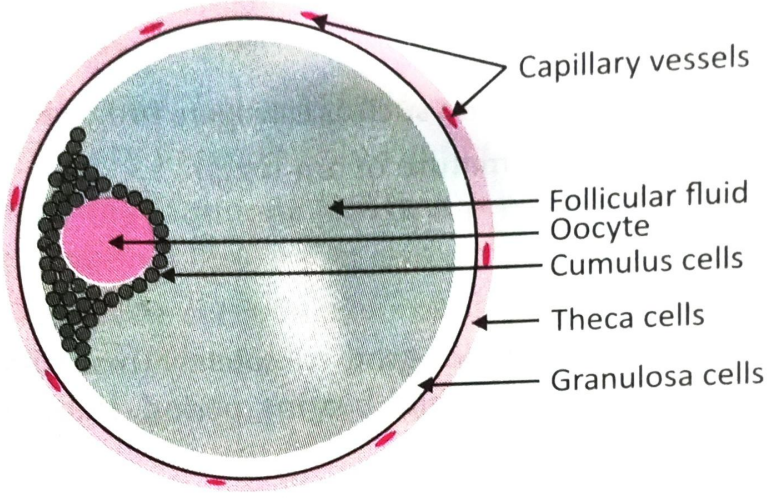

Fig. 15.4: *Ovarian Follicles*

Structure of Graffin Follicle

It consists of following cells:

(i) **Theca cells:** These are externally cells provides structural support of growing follicle
(ii) **Granulosa cells:** These forms single layer around the oocyte and produces sex steroids, i.e., estrogen and progesterons
(iii) **Cumulus cells:** These lie around the oocyte contribute to oocyte maturation and fertilization.

Stages of Graffin Follicle

(i) **Activation of Primordial follicles:** In this stage Primordial follicles (tiny sacs with liquid) consists of oocyte surrounded by a single layer of follicular cells

(epithelial cells), i.e., granulosa cells under influence of Follicle Stimulating Hormone (FSH) and Lutenising Hormone (LH) of the pituitary gland.

(ii) **Formation of primary follicle:** In this stage oocyte (immatured ovum) surround by single layer of cuboidal cells.

(iii) **Formation of secondary follicle:** Secondary follicles consists of many layers of cuboidal cells known as membranagranulosa cells. It secretes follicular fluid

(iv) **Formation of Tertiary follicles (antral stage):** Tertiary follicles consists of fluid filles cavity allledantrum. Which helps in the developments of matured ovum.

(v) **Formation of mature ovarian follicle or matured griffin follicle:** In this stage follicle fully matures and contribute to endocrine function, i.e., is releases estrogen hormone.

Functions of Ovaries

(i) Synthesis and release of hormones such as estrogen, progesterone, inhibin, relaxin

(ii) Development and release of mature ovum (egg.)

PUBERTY IN FEMALES

Puberty is the age at which internal organs grow completely (maturity). This is also called Menarch. It indicates the beginning of child bearing period. Puberty comes at 10 to years.

Following are the changes takes place in females at puberty:

(i) Reproductive organs such as uterus, uterine tubes and ovaries reach maturity

(ii) Menstrual cycle and ovulation begins

(iii) Breast develop and enlarge

(iv) Pelvic hairs grow

(v) Increase in height and widening of pelvis.

(vi) Fat deposition at the hips and breast increases.

PHYSIOLOGY OF MENSTRUAL CYCLE

Menstrual cycle is a series of changes in ovaries and uterus (endometrium) due to hormone production that make pregnancy possible.

The various hormonal changes are:

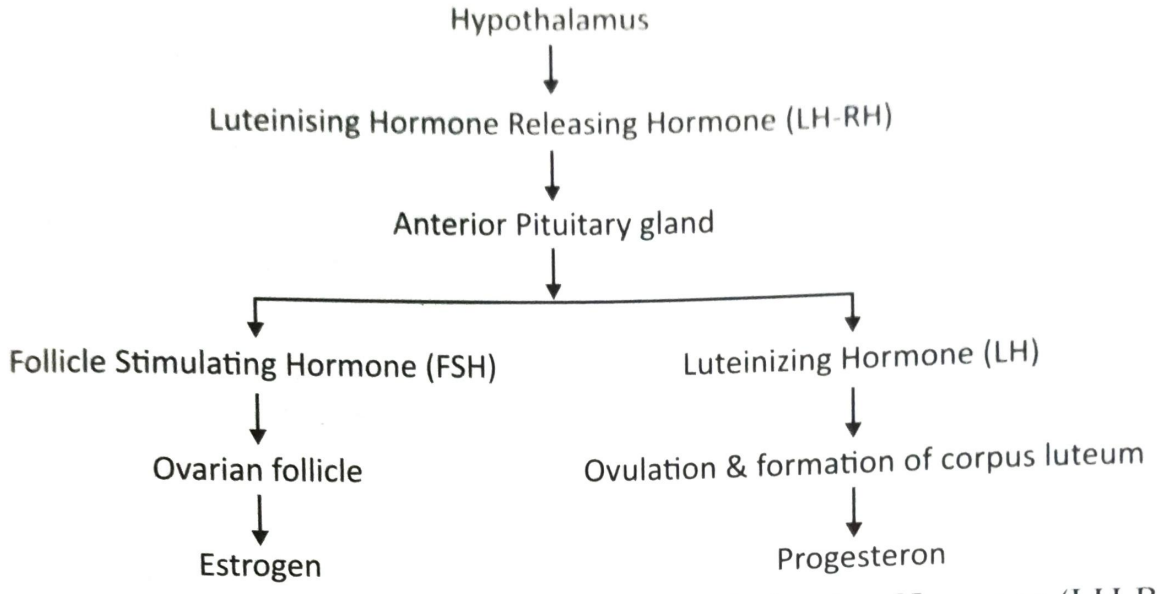

The hypothalamus secretes Luteinizing Hormone-Releasing Hormone (LH-RH). This stimulates anterior pituitary to secret following hormones:

1. **Follicle Stimulating Hormone (FSH):** It promotes maturation of ovarian follicle and growing ovarian follicle secret estrogen in ovaries.
2. **Luteinizing Hormone (LH):** It cause ovulation and stimulates the development of corpus luteum which secretes progesterone.

The phases of menstrual cycle are divided into three stages on the basis of histological changes:

1. Proliferative or Follicular Phase (Preovulation) about 10 days
2. Secretory or Luteal Phase (post ovulation) about 14 days
3. Menstrual Phase (bleeding occur if ovum is not fertilized) about 4 days.

1. Proliferative or Follicular Phase

(a) Here FSH (follicle stimulating hormone from anterior pituitary gland) stimulates growth of ovarian follicle in the ovary.

(b) Now growing ovarian follicle produces estrogen which causes proliferation (growth) of endometrium (lining of uterus). It becomes thicker and vascular for reception of fertilized ovum. This phase is of 10 days. This phase ends with ovulation (release of mature egg from the ovary) under the influence of Luteinizing hormone from pituitary gland and estrogen production stops.

2. Secretory Phase (post ovulation) about 14 days:

(a) Immediately after ovulation (after ovum was released) under the influence of LH, remaining cell lining of the ovarian follicle convert into mass of cells (clot) called corpus luteum. This corpus luteum produces Progesteron. This phase is also called luteal phase or progestational phase.

(b) Now under the influence of Progesterone, the secretory glands of endometrium (uterus) secretes watery mucus and it becomes edematous (thick) for implantation of fertilized ovum. So this phase is also called as secretary phase and lasts for 10-14 days.

3. **Menstrual Phase (bleeding occur if ovum is not fertilized) about four days**

(a) When the ovum is not fertilized, the corpus luteum start to degenerate (break) into an inactive mass of fibrous tissue called corpus albicans. Then menstruation occur.

(b) Due to break down of corpus luteum, the level of progesterone and estrogen decreases and here menstrual flow or discharge starts.

(c) Menstrual flow consists of blood from capillaries, unfertilized ovum. Mucus, epithelial or endometrial cells.

(d) Low levels of Progesteron and estrogen again stimulate anterior pituitary gland to release FSH & LH and starts next cycle.

(e) If ovum or egg is fertilized (fusion of female egg and male sperm). It travel through uterine tubes, where it embeds (attach or implant) in the uterus and produces the hormone chorionic gonadotropin (hcG). This hormone keeps corpus luteum intact and stimulate to secrete progesterone and estrogen for the first 3 months of pregnancy.

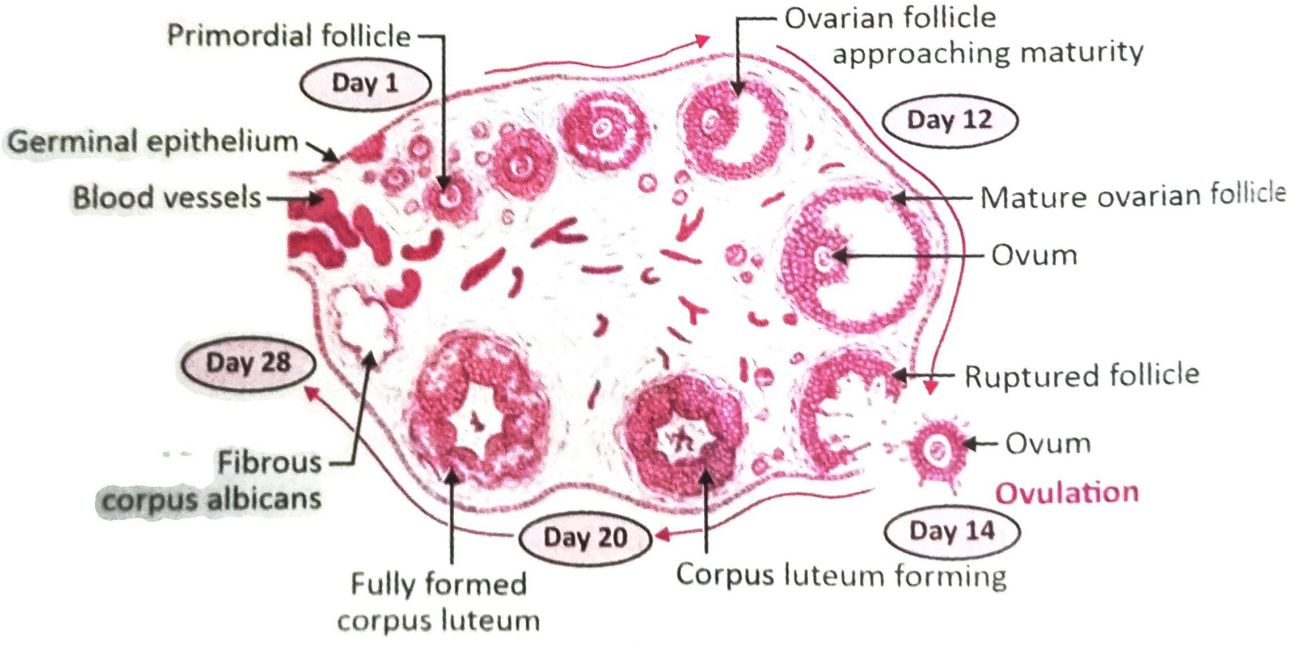

Fig. 15.5: *Stages of Development of one Ovarian Follicle*

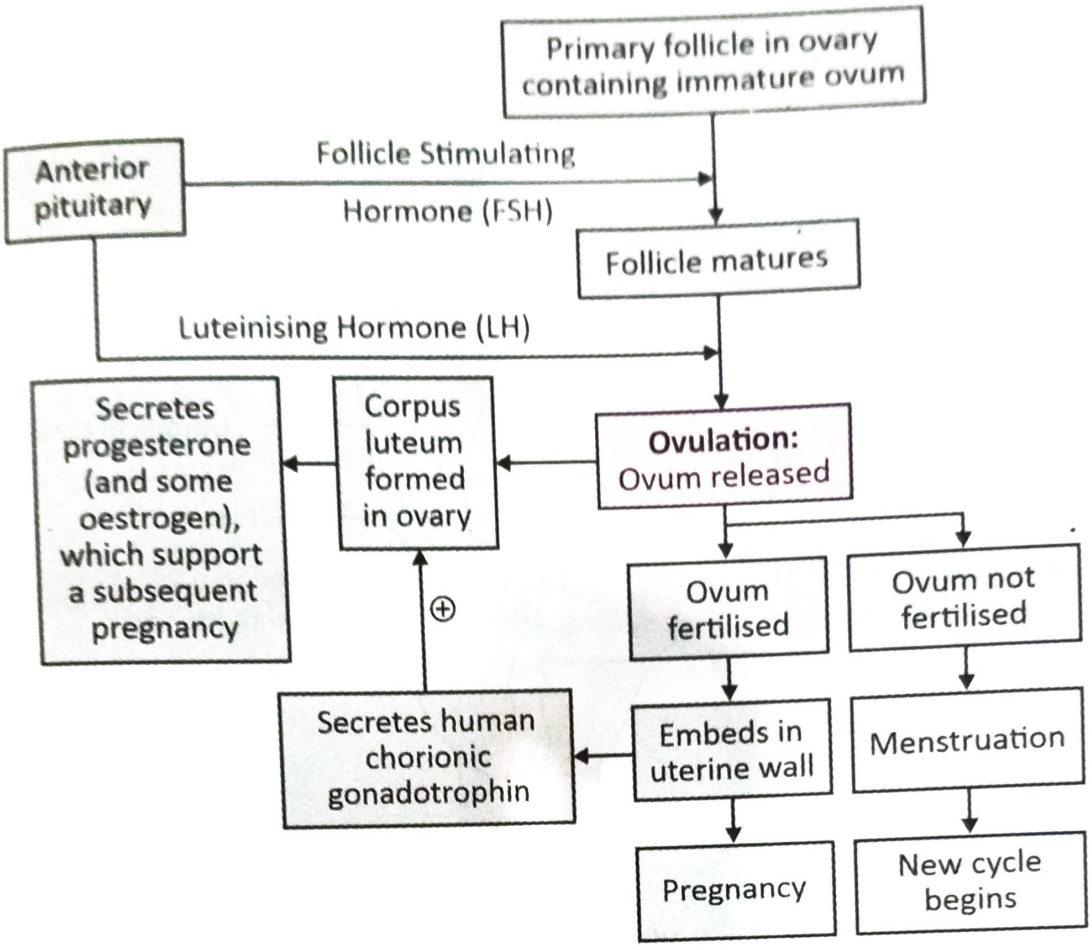

Fig. 15.6: ***Summary of the stages of development of the ovum***

PREGNANCY

Pregnancy is a sequence of events that begins with fertilization, proceeds to implantation, embryonic development and fetal development and normally ends with birth about 38 weeks later or 40 weeks.

Fertilization: The process of fusion of a sperm with the ovum is called fertilization. It takes place at the junction of Ampulla and isthumus of fallopian tube.

Implantation: The attachment of fertilized ovum to the wall of uterus.

Embryonic development (early stages of foetus development): Pregnancy lasts for 9 months. After one month of pregnancy, the embryo's heart is formed. At the end of second month of pregnancy, the foetus develops limbs and digits. At the end of 3 months or 12 weeks (first trimester), most of the major organ systems are formed. At the end of 24 weeks (second trimester) or 6 months, the body is covered with fine hair, eye lids separate and eye lashes are formed. At the end of nine months of pregnancy the foetus is fully developed and is ready for delivery.

During pregnancy, a temporary organ is developed in uterus that joins mother and foetus is called Plancenta. It provide oxygen and nutrients from mother to foetus and

transfer carbon dioxide, waste from foetus to mother through umbilical cord. Thus umbilical cord connects foetus to placenta.

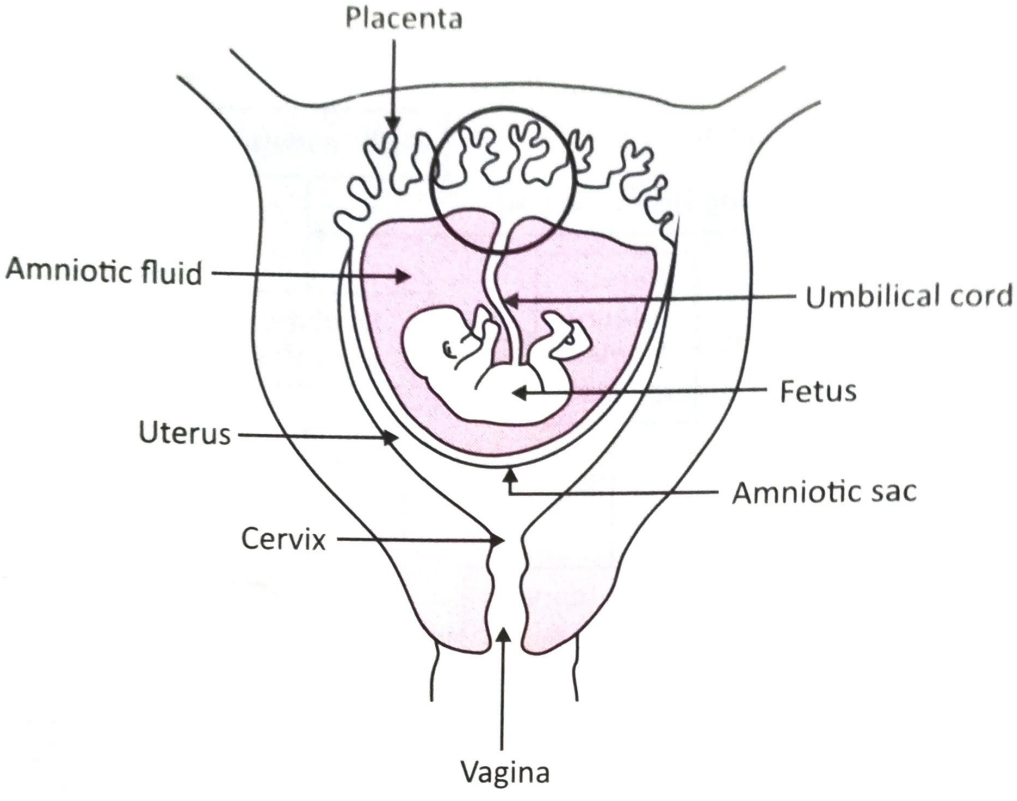

Fig. 15.7: ***Placenta and Umbilical Cord***

PARTURITION (LABOUR)

The average duration of human pregnancy is about 9 months or 38 weeks or 266 days after fertilization which is called gestation period. The process of delivery of the foetus (childbirth) is called Parturition or labour.

Parturition or labour is induced by a complex neurohormonal mechanism. The signals for parturition originate from fully developed foetus and placenta which cause contraction of uterus known as foetal ejection reflex. This triggers the release of oxytocin from the maternal pituitary gland. Oxytocin acts on the muscles of uterus and starts its contraction. Further secretion of Oxytocin resulting in stronger and stronger contractions. This leads to expulsion of the baby out of uterus through the birth canal. Also placenta is expelled out of the uterus.

Parturition includes three stages:

1. **Dilation Stage:** The uterine contraction starts which forces foetus outward and pushes foetal head against cervix. As a result cervix get dilated. This stage lasts 6-12 hours. Dilation of cervix increases the stimulus for xytocin secreation further increases the strength and frequency of contraction (1-3 every minute). With

continued powerful contractions, the amnion (inner membrane that surrounds foetus) rupture and the amniotic fluid flows out through vagina.

2. **Expulsion stage:** The time (10 min to several hours) from complete cervical dilation to delivery of the baby is the stage of expulsion. With further uterus and abdominal contractions, the foetus comes out through cervix and vagina, with head coming out first. Expulsion or delivery may take 20-60 minutes. Umbilical cord cut. Infant's lungs expand and his breathing starts.
3. **Stage of After birth or Plancental stage:** Within 10-15 min after delivery, placenta and the umbilical cord which is called 'after birth' is expelled out.

MALE REPRODUCTIVE SYSTEM

The organs of male reproductive system are given below:

1. **Male gonads:** 2 Testes
2. **Ducts of testes:**
   - 2 Spermatic cords
   - 2 epididymis
   - 2 Vas deferens
   - 2 ejaculatory ducts
   - 1 urethra
3. **Acessory sex glands:**
   - 2 seminal vesicles
   - 1 prostate
   - 2 Cowper's gland (bulbourethral glands)
4. **Supporting structures:** 1 scrotum and 1 penis

PHYSIOLOGY OF MALE REPRODUCTIVE ORGANS

1. **Male gonads:** Testes which produce sperms and male sex hormone testosterone.
2. **Spermatic cords:** Support the testes in scrotum.
3. **Epididymis:** Transport sperm from testis to Vas deferens.
4. **Vas deferens:** Transport sperm to ejaculatory duct.
5. **Ejaculatory duct:** Transport sperm to urethra.
6. **Seminal vesicles:** Produce and store fluid called seminal fluid (semen) which is responsible for sperm motility.
7. **Urethra:** Expel or ejaculate semen.

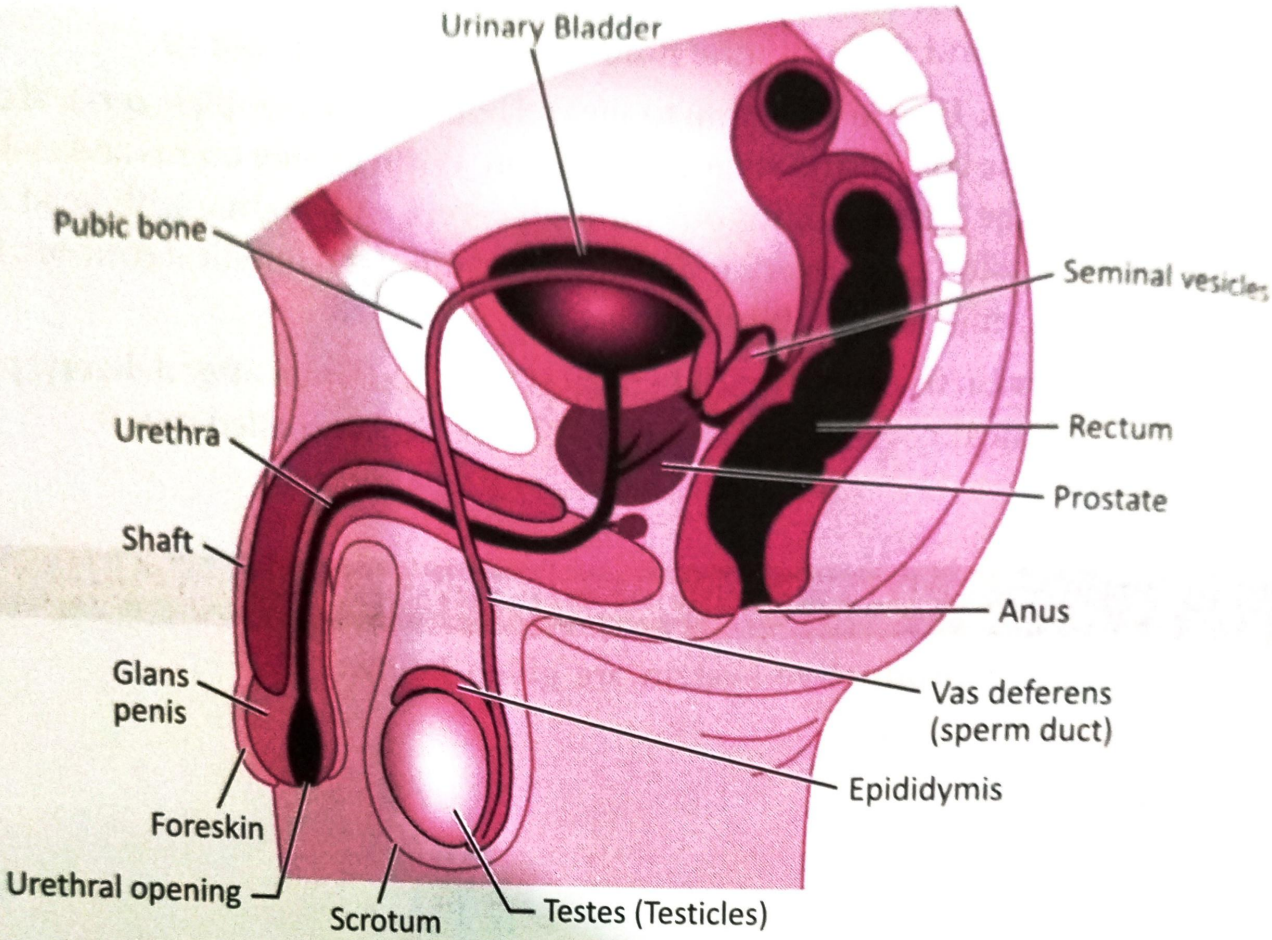

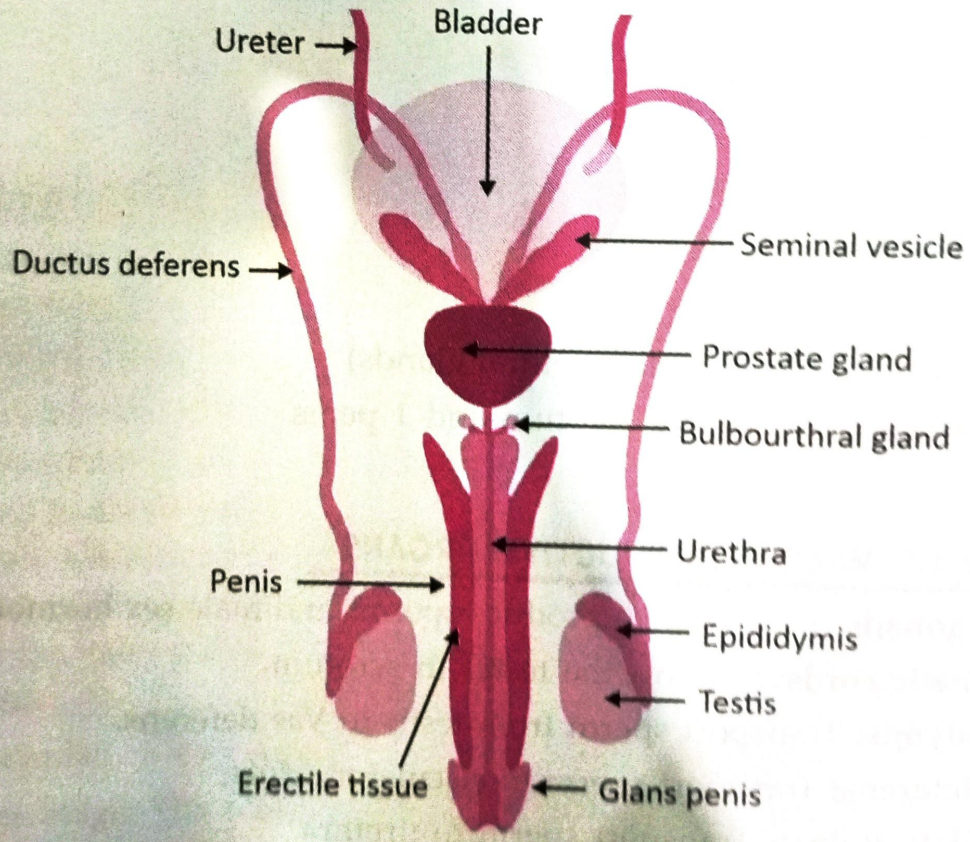

Fig. 15.8: *Male Reproductive Organs*

8. **Prostate gland:** Adds its secreation to the Seminal vesicles for sperm nourishment and motility.
9. **Cowper's gland (bulbourethral glands):** Adds its secreation to the Seminal vesicles and protect sperms during ejaculation.
10. **Scrotum:** It is a bag that holds testes and protect them
11. **Penis:** Transfer semen during sexual intercourse.

ANATOMY OF MALE REPRODUCTIVE ORGANS

A. Scrotum

1. It is a bag or sac consisting of deeply pigmented loose skin, fibrous and connective tissue and smooth muscle. It is a attached portion behind the penis.
2. Externally, the scrotum looks like s single pouch of skin separated into two lateral portions by a median ridge called raphae.
3. Internally, the scrotum divides the scrotum into two sacs, each containing a single testes, one epididymis and testicular end of spermatic cord.

B. Testes

1. The testes are two in number ovoid reproductive glands of the male present in the scrotum. These are equivalent of the ovaries in the female.
2. The testes are about 4.5 cm long, 2.5 cm wide and 3 cm thick and are suspended in the scrotum by the spermatic cords. They are surrounded by three layers of tissues:

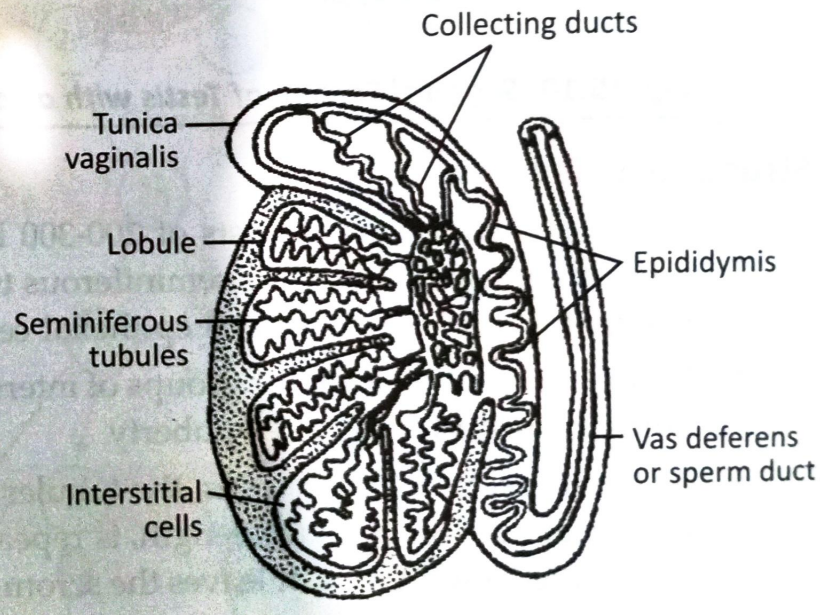

Fig. 15.9: *Testes*

(i) **Tunica vaginalis:** It is a double membrane, forming the outer covering of the testes.

(ii) **Tunica albuginea:** This is the fibrous covering below tunica vaginalis.

(iii) **Tunica vasculosa:** This consists of a network of capillaries.

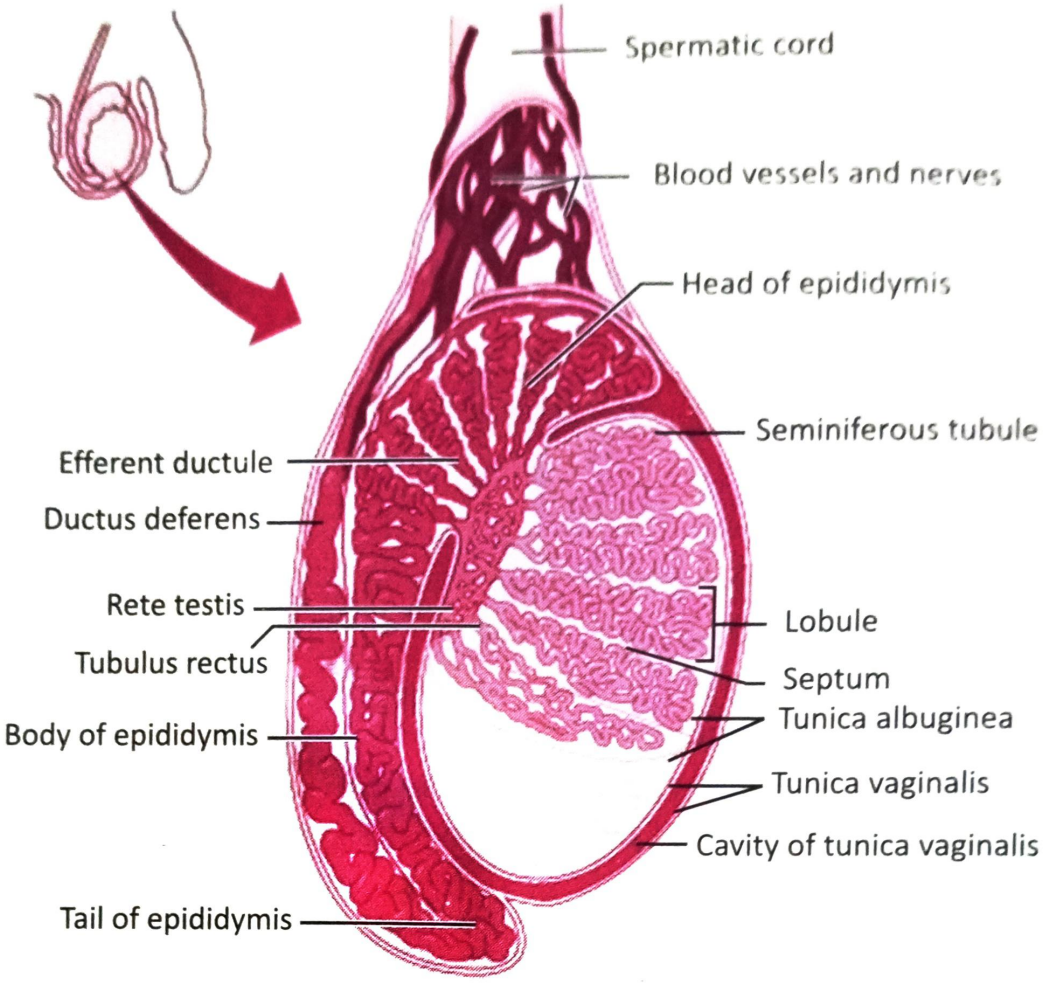

Fig. 15.10: ***Saggital Section of Testis with arrangement of Seminiferous Tubule***

Structure of Testes

1. Each testis (singular) consists of 200-300 lobules. Within each lobule 1-4 coiled tubes are present, known as seminiferous tubules. These tubules are composed of spermatogenic cells (germinal epithelial cells) produces sperms at puberty.
2. Between the tubules are the groups of interstitial cells (of Leyding) that secrete the hormone testosterone after puberty.
3. At the upper pole of the testis, the tubules combine to form a single tubule. This tubule, about 6 m in its full length, is repeatedly folded and tightly packed into a mass called epididymis. It leaves the scrotum as the deferent duct in the spermatic cord.

Structure of Sperm

Mature sperm cell consists of:

1. Head
2. Neck
3. Middle piece
4. Tail

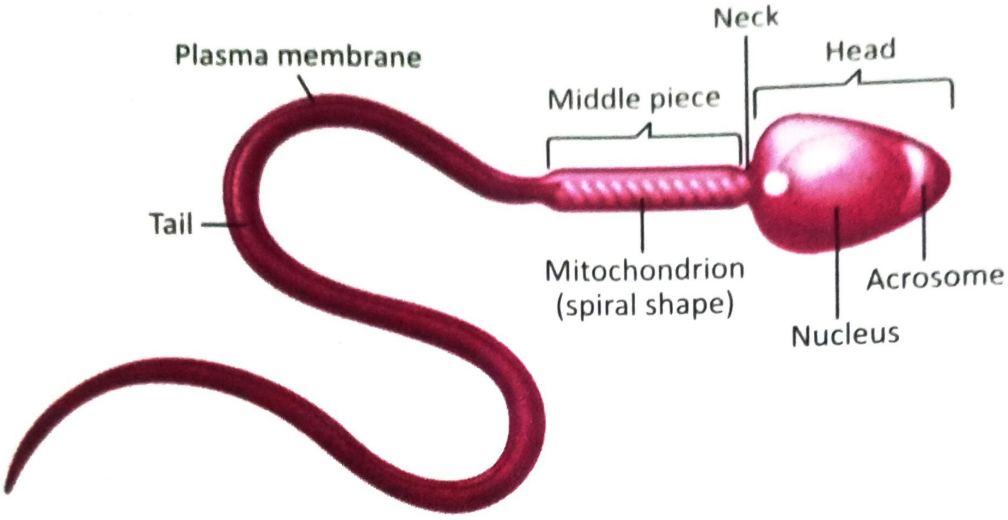

Fig. 15.11: ***Structure of a Spermatozoa***

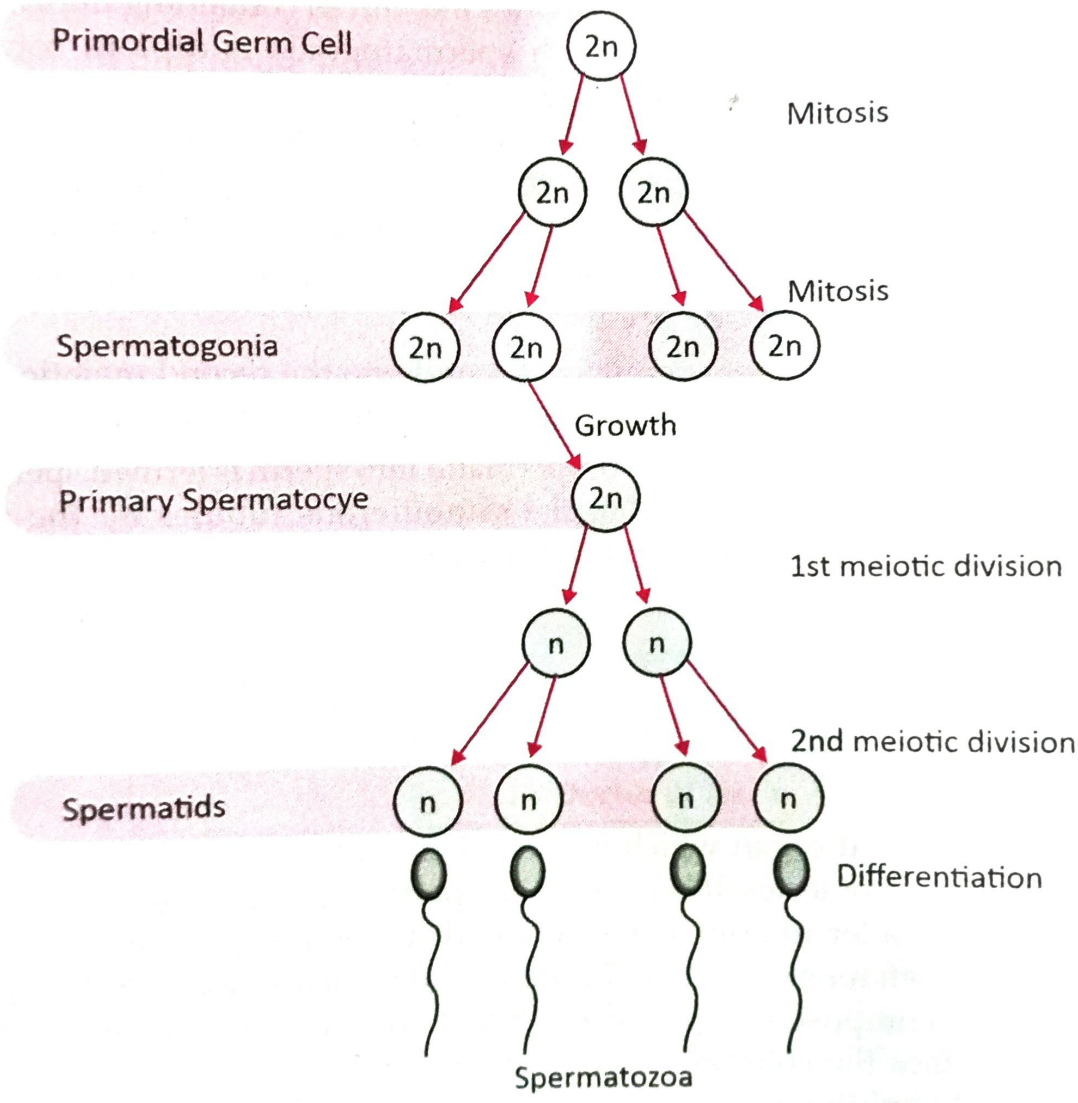

Fig. 15.12: ***Oogenesis***

A plasma membrane envelops the whole body of sperm. The sperm head contains very little cytoplasm. elongated nucleus, the anterior portion of which is covered by a cap like structure, acrosome. The acrosome is filled with enzymes that help in fertilisation of ovum. The middle piece contains numerous mitochondria which produces energy for movement of sperm for fertilisation.

The tail is made up of a central axial filament surrounded by a small amount of cytoplasm and cell membrane as external sheath.

Spermatogenis

It is the process in which immature spermatogonia (male germ cells produces sperm) develop into mature sperm cells Spermatogenesis occurs in four stages in testes-

1. **Spermatocytogenesis:** In this stage the spermatogonia (male germ cells produce sperm) present inside the wall of seminiferous tubules multiply by miotic division (cell division in which the nucleus divides into nuclei containing the same number of chromosomes cell division). Each spermatogonia is diploid containing 46 chromosomes.Some spermatogonia undergo changes, increase in size by accumulating nourishing material and are called diploid primary spermatocytes which periodically undergo meiosis and others remain spermatogonia.
2. **Meiosis-I:** A diploid Primary spermatocytes (2n, 44+ XY Total 46 chromosomes) undergo first meiotic division forms haploid secondary spermatocytes have 23 chromosomes each 22+ X or 22+ Y
3. **Meiosis-II:** The secondary spermatocytes undergo the second meiotic division to produce four equal haploid spermatids. These are non-motile and heavy.
4. **Spermiogenesis:** Transformation of spermatid into sperm is termed spermiogenesis Finally sperms are released from the seminiferous tubules by the process of spermiation. As they are motile and weight less.

DUCTS OF TESTIS

Epididymis

It is a long comma shaped organ which is about 4 cm in length with coiled appearance that lies on the back side of testes. It is consists of 3 parts head (larger superior part), body (middle part), tail (smaller inferior part). At the distal end, the tail of the epididymis continues as the vas deference duct. If epididymis is uncoiled it would be about 6 metres in length. Its walls composed of pseudostratified columnar epithelium and smooth muscles. At the surface the columnar cells branching microvillus called stereo cilia are present. Functionally epididymis is the site of sperm maturation. Which occur within 14 days. It also helps propel sperm into vas deference during sexual arousal by peristaltic contraction of its smooth muscle. Epididymis stores sperm which remain viable for upto several months. Any stored sperm that are not ejaculated by that are eventually reabsorbed

Vas Deferens

The tail of epididymis is known as Vas Deferens. It is about 45 cm in length. Its dilated portion is known as the ampulla which consists of three layers of smooth muscle inner and outer have longitudinal and middle have circular smooth muscles. Functionally Vas Deferens transfer sperms during sexual from epididymis towards urethra by peristaltic contraction of its smooth muscle. Like Epididymis, Vas Deferens stores sperm which remain viable for upto several months. Any stored sperm that are not ejaculated by that are eventually reabsorbed.

Ejaculatory Ducts

It is about 2 cm long and formed by the union of the duct of seminal vesicle and the ampulla of the Vas Deferens. They pass through the prostate gland and join the prostatic urethra where they eject sperm and seminal vesicle secreations just before the release of semen from urethra to the exterior.

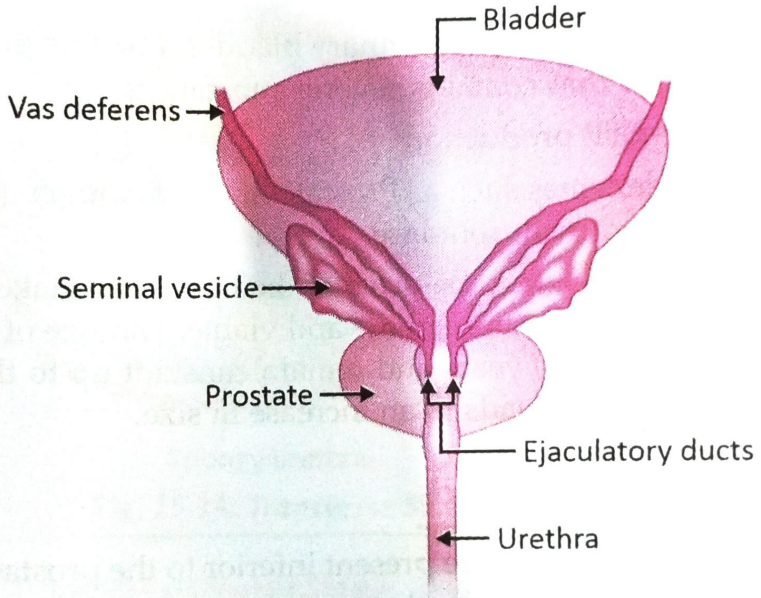

Fig. 15.13: *Ductus of Testis*

Urethra

In male urethra is terminal duct of reproductive and urinary systems. It acts as a common pathway for both semen and urine. Urethra is about 20 cm long consists of 3 parts: first is prostatic urethra is 2-3 cm long passes through the prostate; second is membranous urethra is shortest extends from the prostate gland to the bulb of the penis, third is spongy (penile) urethra is about 15 cm lies within the corpus spongiosum of the penis. The spongy urethra at the end forms external urethral orifice.

ACESSARY SEX GLANDS

Acessary Sex Glands includes seminal vesicle, prostate, cowper's or bulbourethral glands secrete liquid portion called semen.

Seminal Vesicle

These are sac like structures and two in number about 5 cm in length. They are present posterior to the base of the urinary bladder. It secrete an alkaline viscous fluid called as seminal fluid that contains fructose, prostaglandins, clotting proteins. The alkaline nature of this fluide helps to neutralize the acidic environment of the male urethra and female reproductive tract otherwise due acidic environment sperms will die. Fructose used for ATP production. Prostaglandins contribute to sperm mondtility, viability and stimulate smooth muscle contraction. After ejaculation, the semen clots due to proteins. About 60-65% of the semen is secreted by the seminal vesicle.

Prostate Gland

It is a small gland present inferiorly to the urinary bladder. Prostate gland secretes milky, slightly acidic fluid of pH 6.4 that contains several substances:

1. Citric acid used for ATP production
2. Several proteolytic enzymes such as Prostate Specific Antigen (PSA), pepsinogen, lysozyme, amylase and hyaluronidase.

The secretion of this prostate gland passes into the urethra to make proper volume of the semen. It helps the sperms to remain motile and viable. The size of the prostate gland increases up to the age of about 30 years and remain constant up to the age of 45 years. Any infection leads to an increase leads to an increase in size.

Bulbourethral Glands/Cowper's Glands

These are about the size of peas. They are present inferior to the prostate on either side of urethra. During sexual arousal, these glands

Secrete an alkaline fluid into urethra into urethra that protects sperms. These gland also secrete mucus that lubricates the end of penis and lining of urethra, decreasing the number of sperm damaged during ejaculation.

Semen

It is mixture of sperm and seminal fluid (liquid that consists of secretions of the seminiferous tubules, seminal vesicles, prostate, bulbourethral glands). The volume of semen in a typical ejaculation is 2.5-5 ml with 50-150 million sperms per ml. It has slightly alkaline pH 7.2 to 7.7

Penis

It is a male genital organ for reproduction. Penis contains urethra and is a passageway for the ejaculation of semen and the excretion of urine. It has cylindrical shape and consists of 3 portions body, glans penis and root.

The body of the penis have three cylindrical masses of tissue which are surrounded by fibrous tissue is known as tunica albuginea.

The dorsolateral masses is called corpora cavernous penis. Inside the cavernous penis is the midventral mass is known as corpus spongiosum penis. This layer helps to form spongy urethra and is kept open for ejaculation.

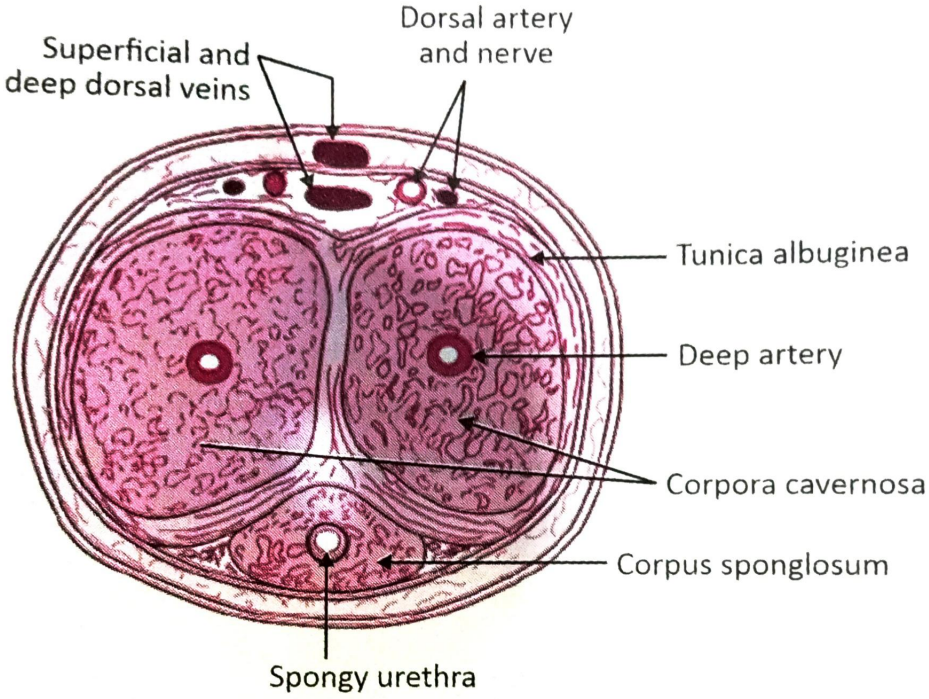

Fig. 15.14: ***Transverse Section of Penis***

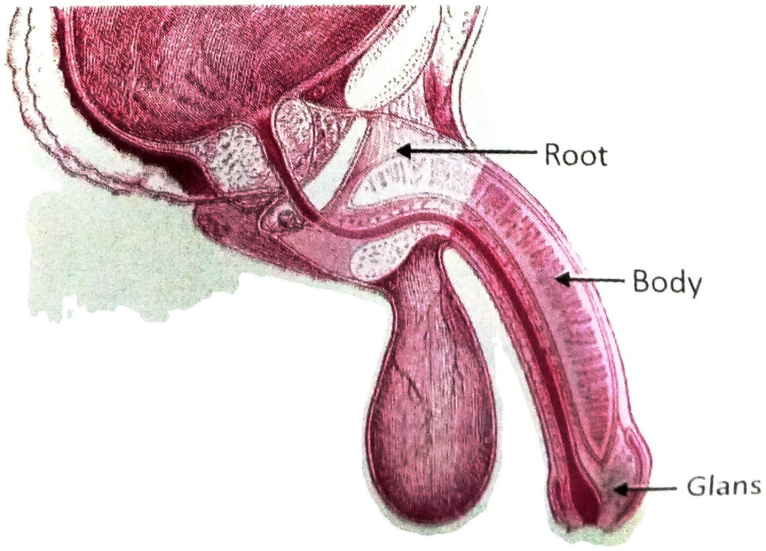

Fig. 5.15: ***Parts or Portions of Penis***

IMPORTANT QUESTIONS

1. Define reproduction. (W-96)
2. Name the different parts of male reproductive system. (W-96; S-03)
3. Describe Testis as a male reproductive organ. (W-99)
4. Discuss the external organs of female reproductive system. (S-96, 97, 99; W-01, 02)
5. Explain the structure and function of ovary. (W-98, 00, 01, 02)
6. Give the features of puberty in male and female. (W-02)
7. Explain Puberty in female. (S-98; W-02)
8. What is Puberty? (W-02)
9. Define menstruation. Describe in detail phases of menstruation. (S-97, 99, 00; W-02)
10. Give the structure and functions of uterus. (S-98, 02; W-98, 01)
11. Describe uterine or follicle tube. Describe oviducts. (W-97, 01)
12. What is menopause? (S-01; W-98)
13. What is semen? (S-01; W-97, 98)
14. Describe Male and Female sex hormones in short. (W-02)
15. What is Placenta? Write its functions. (S-01)
16. Describe ovulation in short. (S-02)

Index

A

Abnormal constituents of urine 221
ABO system 71
ABO system of blood group 71
Absorption of fat soluble vitamins 233
Accessory organs of the eye 192
Acute Renal Failure (ARF) 226
Addison's disease 243
Adipocytes 22, 29
Adipose capsule 234
Adipose connective tissue 25
Adrenal cortex of adrenal gland 243
Adrenal glands 239
Adrenal medulla 243
Agranulocytes 75
Aldosteronism 243
Alimentary canal or tract 132
Alimentary tract 134
Alveoli 120
Anaphylactic shock 110
Anabolic role of parasympathetic and sympathetic nervous system 184
Anatomical position 5
Anatomical terminologies 5
Anatomy 1
Anemia 73
Aneurysm 110
Angina pectoris 110
Antibody mediated immunity 85
Aplastic anemia 73
Appendicular skeleton 33, 48
Appendicular skeleton structure 37
Areolar connective tissue 25
Arteriole 96, 98
Arteriolus 96
Arteriosclerosis 110
Arteritis 110
Arthritis 63
Arytenoid cartilages 126
Asthma 130
Astigmatism 197
Atlas vertebra 42
ATP (Adenosine Triphosphate) 16
ATP hydrolysis 164
Atrioventricular bundle 96
Atrioventricular node 95
Auditory ossicles 36, 199
Auricle 199
Auscultatory method 105
Autonomic nerve activity 96
Autonomic nervous system 182

AV bundle braches 96
Axial skeleton 33, 35
Axial skeleton structure 35
Axis vertebra 43
Axolemma 32
Axons 32

B

Ball and socket joint 60
Baroreceptor reflex 96
Basal ganglia 176
Basophils 75
Bile pigment bilirubin 153
Biogenic amines 232
Blindness 197
Blood 65, 82
Blood cells 68
Blood flow through the heart 92
Blood, functions 65
Blood groups 71
Blood pressure 100
Blood pressure balance 222
Blood supply to the heart 94
Blood vessels 86
Body cavities 4
Body spaces 4
Bone tissue 26
Bones, classification 38
Bones of
  fingers 53
  hand 52, 53
  skull 37
  wrist 53
Bony labyrinth 201
Bowman's capsule 218
Brachial plexus 180
Brain and spinal cord 174
Breastbone 46
Breathing 125
Bronchioles 120
Bronchopulmonary tree 119
Bulbourethral glands 264

C

Capillaries 87
Carbohydrate metabolism 151
Cardiac arrhythmias 110
Cardiac cycle 97
Cardiac muscles 29
Cardiac output 98
Cardiogenic shock 110
Cartilage 28
Cartilagenous joints 59
Cataract 197
Cavities of an eye 191
Cavities of body 4
Cecum 155
Cell 1, 8
Central Nervous System (CNS) 174, 176
Central tendon 123
Cerebellum 178
Cerebrospinal Fluid (CSF) 175
Cerebrum 176
Cervical plexus 180
Cervical spine 43
Cervical vertebrae 42
Characteristics of urine 224
Chemical control 129
Chemical nature of hormones 232
Chochlea 201
Chondrocytes 28
Choroid 189
Chromosomes 12
Chronic Renal Failure (CRF) 228
Chyne stoke's breathing 131
Circulating chemicals 96
Circulation of blood 104
Circulation of blood in the body 87
Circumvallate papillae 136
Classification of blood cells 67
Classification of nervous system 173

Clavicle or collar bone 48
Clitoris 247
Clotting mechanism 76
Coagulation process 76
Coccyx 45
Cochlea 202
Colon 155
Common cold 130
Compact bone 27
Composition of blood 66
Composition of blood with their functions 66
Composition of gastric juice 143
Compound/stratified epithelial tissue 20, 21
Conducting system of the heart 94
Condylar process 40
Condyloid joint 62
Congenital heart disease 110
Congestive Cardiac Failure (CCF) 110
Conjunctiva 193
Conjunctivitis 197
Connective tissue 18, 22
Connective tissue fibers 24
Conn's disease 243
Cornea 189
Corniculate cartilages 116
Coronary circulation 104
Coronoid process 40
Coryza 130
Cowper's glands 264
Cranial nerves 185
Cricoid cartilage 116
Cristae 15
Cuneiform cartilages 117
Cushing syndrome 243
Cytoskeleton 16

D

Dendrites 172
Dermis 207
Diabetes insipidus 243
Digestion and absorption of fat 153
Digestion and absorption of nutrients 156
Digestive system 132
Diphtheria 130
Disorders of
blood vessels 110
eye 196
heart 110
red blood cells 73
respiratory system 130
skeletal muscles 165
urinary bladder 227
Distal Convoluted Tubule (DCT) 218
Divisions of PNS 174
Dorsal cavity 4
Double hinge joint 62
Ducts of testis 262
Duodenum 145
Dyspnea 131

E

Ear drum 199
Ears 197
Edema (swelling) 228
Eicosanids 232
Ejaculatory ducts 257, 263
Elastic cartilage 28
Electrial changes in the heart 99
Electrocardiogram (ECG) 99
Electrolyte balance 222
Electrolytes 66
Ellipsoidal joint 62
Embolism 78
Emotional states 96
Emphysema (full of air) 130
Endocardium layer 90
Endocrine glands 231, 243
Endocrine system 230
Endoplasmic Reticulum (ER) 13
Enzymes 66
Eosinophils 74

Epidermis 205, 206
Epididymis 257, 262
Epiglottis 116
Epithelial tissues 18, 19
Erythrocytes 68
Esophagus 141
Excretion of waste 153
Excretory organs in the human body 212
Exocrine gland 231
Exophthalmia goiteror grave's disease 243
Expiration or exhalation 126
Expiratory reserve volume 129
External acoustic meatus 199
External auditory canal 199
External ear 198
External genital organs 246
External respiration 112, 126
External structure of kidney 214
Eye and sight 188
Eye brows 192
Eye lids 192

F

Face 35
Factors influencing blood pressure 100
Fallopian or uterine tubes or oviducts 249
Farsightedness 196
Fat cells 22
Fatty acid derived hormones 232
Female pelvis 54
Female reproductive system 242, 245
Female urethra 226
Femur bone 55
Fibres of the connective tissue 23
Fibro cartilage 28
Fibroblast 22
Fibrous joint 59
Fibula 56
Filiform papillae 136
Filtering of the lymph 83
Fingers 52
Flat bones 38
Flow of fluid through nephron 219
Flow of tears 193
Foetal blood cell formation 85
Foot bones 58
Forebrain 176
Formation of blood cells 68
Free passage of air 117
Freely movable joints 59
Functions of
  bile 153
  digestive system 133
  fallopian/uterine tubes 250
  hairs 208
  hormones 232
  kidney 212
  large intestine 156
  larynx 117
  muscle tissue 160
  nervous system 171
  ovaries 252
  salivary glands 141
  sclera 189
  skin 209
  small intestine 145
  spinal cord 180
  stomach 143
  testosterone 242
  thymus gland 241
  thyroid glands 237
  urinary system 212
  uterus 249
  vagina 247
Fungiform papillae 136

G

G.I.T. (Gastrointestinal Tract) 132
Gallbladder (gall-bile) 153
Gases 66
GIT (Gastrointestinal Tract) 134
Glaucoma 197
Gliding joint 62
Glomerular capsule 218

Glomerular filteration 219
Glomerulus 216
Glomerulus and glomerular capsule 216
Goblet cells 20
Golgi apparatus 14
Golgi complex 14
Gout 63
Gouty arthritis 63
Granulocytes 74
Greater circulation 107
Gull's disease 243

H

Haemolytic anemia 73
Haemophilia 78
Haemopoiesis 85
Haemopoietic system 65
Haemorrhagic anemia 73
Haemorrhoids 110
Haemostasis 76
Hairs 208
Haversian system 27
Hay fever (allergic rhinitis) 130
HDN or erythroblastosis fetalis 72
Heart 86, 89
Heart rate 96
Heart sound 98
Hemolysis of RBCs 70
Hind limbs 36
Hing joint 61
Hinge joint 61
Hip joint 60
Histology of
large intestine 155
small intestine 146
Histology or coats of alimentary canal (GIT) 134
Hormones 67
Hormones and their functi[illegible]
Hormones in the body 96
Hormones of
adrenal cortex 239
adrenal medulla 239
ovaries (females) 241
pituitary glands 235
testes 242
Humerus 50
Hyaline cartilage 28
Hymen 247
Hyoid bone 36
Hypermetropia 196
Hyperparathyrodism 243
Hypertension 110
Hypopharynx 114
Hypoplastic 73
Hyporparathyrodism 243
Hypothalamus 177, 233
Hypovolemic shock 110

I

Ileum 145
Immovable joint 59
Immunity 83
Incompetence 110
Incus 199
Influenza (flu) 130
Inspiration or inhalation 126
Inspiratory Capacity (IC) 129
Inspiratory Reserve Volume (IRV) 129
Intercoastal muscles 123
Internal (inner) ear 200
Internal genital organs 247
Internal genital organs of female reproductive sys 248
Internal respiration 113, 128
Internal structure of kidney 215
Intestinal juice 147
Involuntary muscles 29
Iron deficiency anemia 73
Irregular bones 38

Ischaemic Heart Disease (IHD) 110
Islets of langerhans 240

J

Jejunum 145
Joint disorders 63
Joints 59

K

Knee cap 56

L

Labia majora 246
Labia minors 246
Labyrinth 200
Lacrimal apparatus 193
Lamellae 27
Large intestine 154
Laryngopharynx 114
Larynx (voice box) 115
Layers or coverings of the heart 89
Lens 191
Lesser circulation 105
Leukaemia 75
Leukocytes 74
Leukocytes disorders 75
Leukocytosis 75
Leukopenia 75
Lipid metabolism 152
Lipids digestive enzyme 148
Liver 149
Location of kidneys 214
Long bones 38
Loop of henle (nephron loop) 218
Lower limb 55
Lower or hind limbs 36
Lumbar plexus 180
Lumbar vertebrae 44
Lung volumes and capacities 128
Lungs 121
Lymph 81, 82
Lymph capillaries 82
Lymph nodes 82
Lymphatic system 80
Lymphocytes 75
Lymphoid tissue 28
Lysosomes 15

M

Macrophages 23
Male gonads 257
Male pelvis 54
Male reproductive system 257
Male urethra 226
Malleus 199
Mandible 39
Mast cells 23
Measurement of Blood Pressure (B.P.) 103
Mechanism of hearing 204
Mechanism of respiration 125
Medulla oblongata 178
Megaloblastic anemia 73
Membranes of lungs 122
Metacarpals 53
Metatarsal 58
Metatarsals 57
Microcytic 73
Microfilament 16
Microscopic structure of
  kidney-nephron 216
  liver 150
  skin 206
  skeletal muscle 160
Microtubules 16
Micturition/urination 226
Middle ear 199
Minor and major calyces 215
Mitochondria 15
Monocytes 75
Mons pubis 246

Mouth 135
Mucociliary function 118
Mucosa 146
Muscle fibres 29
Muscle strain 165
Muscle tissue 18, 29
Muscles of
hip & lower limb 169
the abdominal wall 167
the back 166
the face 165
the lower limb 169
the neck 166
the pelvic floor 167
the shoulder 168
the trunk 166
the upper limb 168
Muscular dystrophy 165
Muscular system 159
Muscularis 146
Myalgia 165
Myasthenia Gravis (MG) 165
Myeline sheath 32
Myocardial Infarction (MI) 110
Myocardium layer 90
Myopia 196
Myositis 165
Myxedema 243

N

Nasopharynx 114
Nearsightedness 196
Nephritis 227
Nephrons 215
Nephrotic syndrome 228
Nerve cell body 171
Nerve supply to the heart 96
Nervous system 171
Nervous tissue 19, 30
Net filteration pressure 220
Neural or nervous control 129
Neurilemma 32
Neuromuscular Junction
Neuron 31, 171
Neutrophils 74
Nodes of ranvier 32
Nose 114
Nucleoli 12
Nucleus 12
Nutrients 66

O

Obstructive shock 110
Oliguria 228
Oogenesis 261
Organ 1
Organelles of the cell 12
Organs of digestive system 132
Organs of respiratory system 113
Organs of urinary system 212
Oropharynx 114
Osteoarthritis 63
Osteocytes 27
Osteons 27
Outer bony labyrinth 200
Ovarian follicles 251
Ovaries 250

P

Pancreas 148
Pancreas gland 240
Pancreatic hormones 240
Parathyroid gland 243
Parathyroid glands 237
Parts of uterus 248
Parturition (labour) 256
Passage of sound waves 203
Patella (little dish) 56
Path of urine of urine drainage 21
Pectoral (shoulder) girdles 36, 48
Pectoral girdle 55
Pelvic (hip) girdle 53

Pelvic girdle 41
Pelvis 54
Penis 265
Pericardium 91
Pericardium layer 90
Periosteum 26
Perioxisomes 15
Peripheral Nervous System (PNS) 182
Permanent teeth 139
Pernicious anemia 73
Phagocytosis 83
Phalanges 53, 57, 58
Pharynx (throat) 114
Phases of gastric juice secretion 144
Physical properties of blood 66
Physiology 1
Pineal gland 241
Pinna 199
Pituitary gland 233, 243
Pivot joint 63
Plasma 67
Plasma cells 23
Plasma membrane 11
Plasma proteins 66
Plasma versus serum 67
Platelets 76
Platelets disorders 77
Pneumonia 130
Polycystic kidney diseases 228
Polycythemia 73
Pons 178
Portal circulation 107, 108
Power house of the cell 16
Pregnancy 255
Presbyopia 197
Prostate gland 264
Protein metabolism 151
Protein or peptide hormone 232
Proximal Convoluted Tubule (PCT) 218
Proximal end 50
Puberty in females 252
Pulmonary circulation 105
Pulmonary ventilation 125
Pulse 99
Pupil, iris and ciliary body 190
Purkinje fibres 96

R

Radius 51
Rectum 155
Red blood cells 68
Reflex action 180
Reflex arc 181
Regional part of the body 6
Regulation (rate and depth) of respiration 129
Regulation of blood pressure 101
Renal capsule 214
Renal corpuscle 216
Renal cortex 215
Renal failure 228
Renal fascia 214
Renal hilum 214
Renal medulla 215
Renal papilla 215
Renal pelvis 215
Renal pyramids 215
Renal tubule 216, 218
Reproductive system 245
Residual volume 129
Respiratory system 112, 113
Retina of an eye 190
Rhesus system (Rh) 71
Rheumatoid Arthritis (RA) 63
Rib 47
Rib cage 47
Ribosomes 14
Ribs 47
Role of thoracic cage in respiration 123
Rough endoplasmic reticulum 13

S

Sacral plexus 180
Sacrum 45
Saddle joint 63
Salivary glands 139
Scapula or shoulder blade 48
Sclera 189
Scrotum 259
Sebaceous (oil) glands 208
Selective reabsorption 221
Semen 264
Semicircular canals 200
Seminal vesicles 257, 264
Sense organs 188
Sensory nerve endings 208
Septic shock 110
Serosa 146
Sesamoid bones 38
Sex glands 264
Shock 110
Short bones 38
Shoulder joint 60
Sickle cell anemia 73
Simple epithelial tissue 19, 20
Sinoatrial node 95
Sinusitis 130
Skeletal muscles 29, 159
Skeletal muscles of the body 165
Skeletal or voluntary muscles 160
Skeletal system 33
Skeleton 33
Skeleton system 33, 34
Skin 204
Skull–cranium 35
Slightly movable joint 59
Small intestine 145
Smooth endoplasmic reticulum 14
Smooth muscles 29
Spermatic cords 257
Spermatocytogenesis 262
Spermatogenis 262
Spermatozoa 261
Spermiogene
Sphygmomanometer 103
Spinal cord 179
Spinal nerves 185
Spleen 84, 85
Spongy bone (cancellous or trabecular bone) 27
Stages of graffin follicle 251
Stages of respiration 112
Stapes 199
Stenosis 110
Sternum 46
Steroids 232
Stomach 142
Storage of blood 85
Stratified squamous epithelium 21
Stratum corneum 207
Stratum germinativum 207
Stratum granulosum 207
Stratum lucidum 207
Striated muscles 160
Stroke volume 98
Structure (histology) of uterus 249
Structure of
- blood vessels 87
- eye 189
- graffin follicle 251
- ovary 250
- retina 196
- salivary glands 140
- skin 205
- sperm 260
- testes 260
- vagina 247

Stye 197
Submucosa 146
Suicidal bags 15
Sweat glands (sudoriferous glands) 2
Synovial joints 59, 60
System 1
Systemic circulation 107
Systemic gas exchange 128
Systems of the human body 3

T

Tail bone 45
Tarsals 57
Teeth 137
Temporary or deciduous or milk teeth 138
Testes 259
Thalamus 177
Thalassemia 73
The cricoid cartilage 116
Thigh bone 55
Thoracic cage 45, 124
Thoracic cavity 47
Thoracic vertebrae 44
Thorax 36, 45
Thrombocytes 76
Thrombocytopenia 77
Thrombosis (large blood clot) 78
Thymus gland 241
Thyroid cartilage 116
Thyroid gland 236, 243
Tibia (shin bone) 56
Tibia and fibula bone 57
Tidal volume 128
Tissue 1, 18
Tonsillitis 130
Tounge 136
Trabeculae 27
Trachea 117
Transitional epithelium 21
Trigone 225
Tuberculosis (TB) 130
Tubular reabsorption 221
Tubular secretion 221
Tympanic cavity 199
Tympanic membrane 199
Types of muscles 159
Typical vertebra 42

U

Ulna 51, 52
Ultrafilteration 219
Upper or lower limbs 36
Ureters 224
Urethra 226, 257, 263
Urinary bladder 225
Urinary system 212, 213
Uterine tubes 249
Uterus 247

V

Vagina 247
Valves of the heart 91
Varicose vein 110
Vas deferens 257, 263
Vascular shock 110
Veins 87, 88
Ventral cavity 4
Venules 87
Vertebral column 36, 40
Vestibular glands 247
Vestibule 201
Vital Capacity (VC) 129
Voice box 115
Voluntary muscles 29

W

Waste products 67
Water balance 221
White blood cells 23, 74
White fibrous tissue 26
Wind pipe 117
Wrist 52

Y

Yellow elastic tissue 26

Also Available

Textbook of Social Pharmacy

Exclusively Prepared for D.Pharm First Year Students (PCI ER 2020)

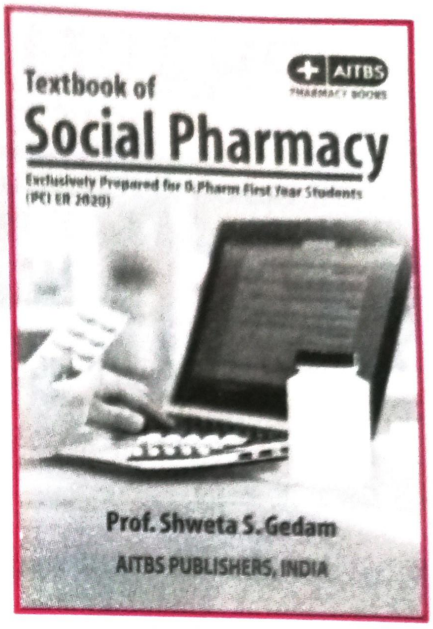

PROF. SHWETA S. GEDAM
M. Pharmacy (Pharmaceutics)
Assistant Professor
Sandip Institute of Pharmaceutical Sciences
Nashik, Maharashtra

1/Ed. 2022 • 264 pages • 5.5" × 8.5" • Soft Cover

ISBN: 978-93-7473-706-4

About the Book:

The contents of the "Textbook of Social Pharmacy" comprises total 6 units as syllabi laid down by Pharmacy Council of India, which is mandatory and followed by all D. Pharmacy Institutes throughout the India.

This book provides detailed knowledge of concepts of health, various National health policies, scope of social pharmacy and role of pharmacist in public health, Preventive healthcare, Nutritional benefits towards health, importance of balance diet, Microbiology and Epidemiology for knowing Cause, Symptoms, Mode of Transmission, Treatment, Prevention and control of various communicable diseases such as Covid-19, and various ongoing National health programmes in India.

Contents of the Book:

1. Introduction to Social Pharmacy
2. Prevention Healthcare–Role of Pharmacist
3. Nutrition and Health
4. Microbiology and Common Microorganisms
5. Health Systems and National Health Programmes
6. Pharmacoeconomics

AITBS Books
Medical Publishers

For more Books please visit or Scan the QR Code
www.aitbspublishersindia.com & all leading book stores

HUMAN ANATOMY & PHYSIOLOGY

Exclusively Prepared for D.Pharm First Year Students (PCI ER 2020)

This book is written in a lucid language along with schematic diagrams to expand the horizon of conceptual understanding. It is designed to facilitate the meaningful learning experiences and also enables students to appreciate the beauty of the subject. The content of this book is beneficial for the study of Pathophysiology, Pharmacology and Pharmacotherapeutics.

It is a humble attempt as per syllabus based on Education Regulations, 2020 prescribed by Pharmacy Council of India (PCI), New Delhi for Diploma Course in Pharmacy. I hope this book becomes valuable tool for students as-well-as teachers to achieve academic goals.

Seema Rahul Kenjale was D.Pharm Topper of Bharati Vidyapeeth's Institute of Pharmacy, Pune. She completed her B.Pharm from Bharati Vidyapeeth's Poona College of Pharmacy, Pune and M.Pharm (Pharmacology) from P.D.E. A's Seth Govind Raghunath Sable College of Pharmacy, Saswad under the Pune University. She worked as an Assistant Professor at Pune District Education Association's Seth Govind Raghunath Sable College of Pharmacy(Polytechnic) Saswad and Currently at Pune District Education Association's Shankarrao Ursal College of Pharmacy (Diploma), Kharadi Pune. She has total 16 years of teaching experience. She is a member of Association of Pharmaceutical Teachers of India (APTI). She attended 34 Seminars, Workshop and Faculty Developments Programmes sponsored by AICTE, MSBTE and various universities.

₹ 295

ISBN 978-93-7473-714-9

9 789374 737149

A.I.T.B.S.

AITBS PUBLISHERS, INDIA

MEDICAL PUBLISHERS

J-5/6, Krishan Nagar, Delhi-110 051 (INDIA)

Phone: 011-40167052, 49067602; Fax: 011-2200907

E-mail: aitbsindia@gmail.com & aitbsindia@hot

Website: www.aitbspublishersindia.co